

The radial artery as a conduit for coronary artery bypass grafting: review of current knowledge

*Koroner arter cerrahisinde konduit olarak radyal arter:
Mevcut literatürün gözden geçirilmesi*

Petar S. Risteski, Birkan Akbulut, Anton Moritz, Tayfun Aybek

Department of Thoracic and Cardiovascular Surgery, Johann Wolfgang Goethe University, Frankfurt am Main, Germany

ABSTRACT

The effect of coronary artery bypass grafting (CABG) lasts as long as the grafts are patent. The internal mammary artery has been considered the "golden" graft due to the superb long-term patency, exceeding 90% at 10 years. The saphenous vein grafts, unfortunately, tend to occlude with a rate of 10-15% within a year after surgery, and eventually, at 10 years after the operation, as much as 60-70% of these vein grafts are either occluded or have angiographic evidence of atherosclerosis. The search for another "arterial conduit", the radial artery, has intensified through the last 15 years in hope to provide a better graft than the saphenous vein for CABG. This article reviews the current knowledge for the radial artery as a conduit in CABG. (*Anadolu Kardiyol Derg 2006; 6: 153-62*)

Key words: Radial artery, conduit, coronary artery bypass graft surgery

ÖZET

Koroner arter baypas greft cerrahisinin (CABG) etkisi greftler patent olduğu sürece devam eder. İnternal mammaryan arter 10 yılda %90'lık olağanüstü kabul edilen uzun dönem açıklık oranı ile "altın" greft olarak nitelendirilmiştir. Safen ven grefti ne yazık ki cerrahiden bir yıl sonra % 10-15 oranında oklüde olmaktadır ve nihayet 10 yıl sonra da ven greftlerinin % 60-70'i ya oklüde olurlar ya da anjiyografik olarak aterosklerotiktirler. Son 15 yılda CABG için safen venden daha iyi bir greft sağlamak amacıyla başka bir "arteryel konduit", yani radyal arter için arayışlar yoğunlaşmıştır. Bu makale radyal arterin CABG'de kullanımı için mevcut bilgileri gözden geçirmektedir. (*Anadolu Kardiyol Derg 2006; 6: 153-62*)

Anahtar kelimeler: Radyal arter, konduit, koroner arter baypas cerrahisi

Introduction

The radial artery (RA) was introduced as coronary artery bypass grafting (CABG) conduit by Carpentier in 1973 (1). His initial experience was disappointing: graft occlusion secondary to spasm from traumatic harvesting and lack of perioperative antispastic measures was a common complication. Others concluded similarly, leading to early abandonment of this vessel as a CABG conduit by the mid-1970's (2). At that time, antispasmodic drugs were not available, and the role of the preservation of endothelial function during harvest was unknown.

More than fifteen years after the first series by Carpentier, Acar observed that some of the RA grafts originally thought to be occluded are fully patent on control cineangiography. This, together with the introduction of minimally traumatic dissection techniques and calcium-channel blockers to prevent postoperative spasm has revived the RA as a graft for CABG (3).

Acar's 1989-1992 experience with the initial 50 patients with the RA as conduit for CABG has been excellent (3). This time, however, all of the patients have diltiazem started intraoperatively

and continued after discharge. The early angiographic controls have depicted average patency rate of 99% and perfect patency rate of 89.3% for RA grafts in this series. This encouragement has further increased the interest for the use of the RA as a coronary artery bypass. The need for "another" arterial conduit was already there, as the well-documented long-term failure of great saphenous vein (GSV) has become number one cause for reoperation in CABG patients. Afterwards, many institutions have started CABG programs with the use of the RA, advancing towards total arterial myocardial revascularization, including also diabetic patients (4-6).

The purpose of this paper is to review the current knowledge about the radial artery as a bypass graft, with emphasis on the early, mid- and long-term clinical results available in the literature.

Histology and Anatomy of Radial Artery

The average patient's RA length varies between 18 and 22 cm, and the inner diameter spans between 2-3 mm (7). The radi-

al artery is a thick-walled muscular artery, representative of Guo-Wei He's classification type III (limb artery). The major feature of this type of arteries is the higher tendency for spasm when compared to other types (somatic and coronary) (8). It is rarely aneurysmatic, and if so, the aneurysm or pseudoaneurysm is usually saccular and involves the very distal segment of the RA (9).

As with the other arteries, five histologically distinct layers in the RA wall can be identified. The intima has a single layer of endothelial cells. The internal elastica lamina has multiple fenestrations, and the media is constituted by many leiomyocytes, collagen and elastic fibers, some macrophages and fibroblasts. The external elastic lamina is less individualized than the internal lamina. The vasa vasorum, nerves, and delicate lymphatic vessels are confined to the adventitia.

As opposed to the internal thoracic artery (ITA), the RA has a thicker wall, is greater in size and luminal diameter, and has a higher density of muscle cells with relatively the same amount of elastic tissue in its media (7). In addition, the myocytes are organized into multiple tight layers, while in the ITA, the muscle cells are less organized and irregular in shape, and this, together with the wider thickness of the media, may in part explain the spasmodic features of the RA.

The degree of vulnerability to atherosclerosis with the RA in presence of risk factors, although low, has been reported to be slightly higher than that of the ITA (10). This slightly higher propensity of the RA to atherosclerosis usually does not impair RA flow, because of its relatively large diameter.

A detailed knowledge of volar forearm anatomy, its sensory innervation as well as surgical and topographic anatomy of the radial artery and its course is required for safe harvest.

The volar forearm extends from a line drawn between the two humeral epicondyles to the wrist crease. It is divided into three zones for purposes of RA harvest: proximal, middle, and distal zone.

The proximal zone presents with lateral muscular prominence (Fig. 1), composed of the brachioradialis, the extensor carpi radialis longus, and the extensor carpi radialis brevis muscles. The medial aspect is marked with the ridge of the biceps tendon. In the middle zone of the volar forearm, the lateral edge of the brachioradialis muscle gently curves to take the contour of the

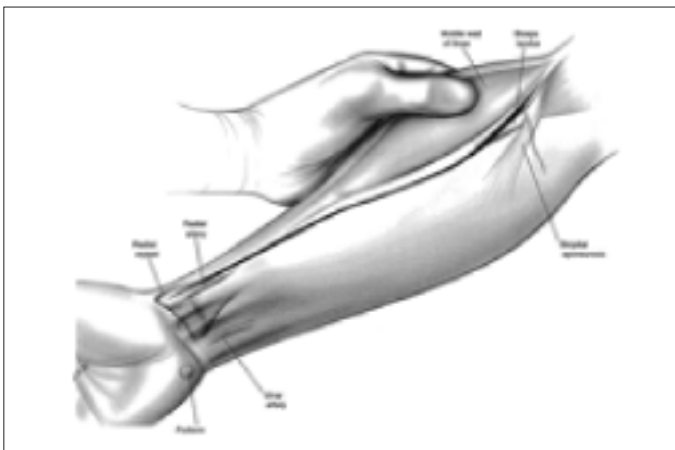


Figure 1. Superficial landmarks and skin incision for radial artery harvest. The incision follows the curving edge of the belly of the brachioradialis muscle

(Reprinted from ANNALS OF THORACIC SURGERY, V59: 118-126, Reyes AT et al: "Technique of harvesting ..." © 1995, with permission from the Society of Thoracic Surgeons).

radius bone. It is in this zone that the RA exits from underneath the cover of the brachioradialis muscle, revealing the most proximal point of the radial pulse detected by superficial palpation. The radial styloid, a surface landmark of the distal zone, is a bony prominence at the distal lateral extent of the radius bone. Medial to it, two prominent tendons extend toward the palmar aspect of the hand - the tendon of the flexor carpi radialis muscle is lateral, and the tendon of the palmaris longus muscle is medial.

The sensory innervation of the volar forearm, portions of the thumb, and the dorsum of the hand is provided by two nerves: the lateral antebrachial cutaneous nerve (LABCN) and the superficial branch of the radial nerve (sRN). These nerves could be encountered during harvest attempts and measures should be undertaken to avoid injury

The LABCN is a branch of the musculocutaneous nerve. Formed by the ventral rami of the C5 and C6 roots, it provides sensory innervation to the radial aspect of the volar forearm. Injury of this nerve during harvest can result in postoperative paresthesias to the radial aspect of the volar forearm. After division into volar and dorsal branch at the level of antecubital fossa, the volar branch of the LABCN enters the proximal zone through an opening in the investing layer of fascia that covers the biceps and brachialis muscles. As it travels distally, the nerve traverses the fascial sheath of the brachioradialis muscle and the superficial flexor muscle compartment of the forearm.

The sRN is purely sensory nerve providing cutaneous innervation to the thenar eminence in the palm, radial aspect of the thumb and dorsum of the hand. It is formed from ventral rami originating from C7 and C8 cervical nerve roots. The sRN courses distally in the volar forearm in close proximity to the RA. Both the artery and the nerve lie under the brachioradialis muscle in the proximal and middle zones. In the distal zone, the nerve swings underneath the brachioradialis tendon to enter the dorsum of the distal forearm and hand. Normally, it is not visualized during harvest; however, if excessive lateral retraction to the brachioradialis muscle is being applied during harvest, it will become visible. In this case, the risk for traction trauma is increased.

The RA originates at the level of the radial tuberosity, below the elbow, as a more direct continuation of the brachial artery. The ulnar artery originates at almost a right angle from the parent vessel. Based on anatomic studies, the ulnar artery has been considered to be the greater artery, although conflicting reports have been published. These include greater radial artery blood flow (11) and greater mean internal diameter of the radial artery (12) when compared to the ulnar artery.

In its proximal third, the RA courses beneath the brachioradialis muscle belly, and then progressively leaves the lower surface of the muscle, running beneath the antebrachial fascia, between the brachioradialis muscle and the flexor carpi radialis muscle or its tendon. In this area, care has to be taken to spare the LABCN which lies over the belly of the brachioradialis muscle. The first major side branch of the radial artery, the radial recurrent branch takes off approximately 1 cm distal to radial edge of the bicipital aponeurosis. This side branch is the endpoint landmark for proximal dissection of the RA.

In the middle zone, the RA courses between the brachioradialis muscle (lateral to the artery) and the superficial flexor muscle compartment of the forearm (medial to the artery). The floor beneath the artery in this zone is limited to the pronator teres muscle. It is in this zone that the LABCN and sRN are at gre-

atest risk. Along the course in the middle zone, numerous small dorsolateral and dorsomedial perforating branches take off at irregular points from the RA and provide perfusion for the muscles, fascia and skin of the forearm. Eventually, this small vessel network anastomosis with similar small branches' network arising from the ulnar artery, an anatomic concept critical for the lack of forearm and hand ischemia after removal of the radial artery. The perforating branches are also found in the proximal and distal zone.

The distal RA is superficial, covered only by skin, superficial fascia and thin layer of connective tissue. It courses in a groove ("the pulse groove") between the brachioradialis tendon laterally and the flexor carpi radialis tendon medially. The perforating branches found in this zone are shorter, finer, and more delicate than those present in the two other zones. In addition, it is in this zone that the RA can be encased in a scar tissue and inflammatory adhesions as a result of prior cannulation for arterial gas sampling or continuous blood-pressure measurement, or even be aneurysmatic (9). The harvesting technique in this zone, therefore, can be more technically demanding. Because of large number of anastomotic branches in the distal third of the forearm, if only a short segment of RA is required, eg. as for an intermediate, high obtuse marginal or right coronary artery, then the proximal two thirds of the radial artery would be preferred as a conduit - both to avoid disrupting the distal anastomotic branches, and also to enable the surgeon to work with a larger conduit.

In the most distal aspect of this zone, the radial artery divides into four branches which anastomose with similar branches of the ulnar artery, providing the vascularization of the hand: (1) the carpal palmar branch anastomoses with a similar branch of the ulnar artery; (2) the superficial palmar branch, which together with the main trunk of the ulnar artery, forms the superficial palmar arch, that gives the four common digital palmar arteries, (3) the dorsal carpal branch, with a similar ulnar branch, forms the dorsal carpal arch that gives rise to the dorsal metacarpal arteries, and (4) the termination of the RA itself anastomoses with the deep palmar branch of the ulnar artery to form the deep palmar arch. It is due to this rich intercommunication between the radial and the ulnar arteries that the vascularization of the hand is preserved after RA harvest. One functional artery is enough for limb viability and vascular function (13). Usually, the origin of the superficial palmar branch defines the distal extent of forearm dissection for RA harvest.

Preoperative Assessment of the Adequacy of the Ulnar Collateral Circulation of the Hand and Contraindications for RA Harvest

In preparation for RA harvest for purposes of CABG, the patient's ulnar collateral circulation to the hand must be assessed. Only in cases of sufficient collateral circulation, the harvest can be undertaken.

The up-to-date methods include:

- a. the Allen test (14) and its modifications (15);
- b. static and dynamic Doppler testing (16);
- c. direct digit pressure measurement during RA compression (17);
- d. oximetric plethysmography with computation of a perfusion index (18).

If these protocols are closely followed, any ischemic finger complication may be only anecdotal. A nonsatisfactory collate-

ral circulation has been reported to exclude RA harvest unilaterally in 5% to 11.6% (19), and bilaterally in 5% to 6.4% (18) of patients who are candidates for RA harvest.

In addition, absence, hypoplasia or atrophy of the ulnar artery, although rare findings (20), are clear contraindications for RA harvest. Other contraindications to the use of the RA (21) include:

1. Previous upper limb trauma
2. Presence of arteriovenous fistula
3. Chronic disease states that would not permit Ca²⁺ channel blockers therapy in the postoperative period:
 - depressed ventilatory function as suggested by preoperative pulmonary function tests,
 - chronic renal failure as suggested by a serum creatinine level greater than 2 g/100 mL,
 - systolic blood pressure less than 100 mm Hg

In addition, the radial artery would not be harvested if it may be required in the future, such as a creation of AV fistulas for dialysis, or when significant calcification can be palpated, or is noted on ultrasound imaging of the radial artery.

Harvesting Techniques

A.Reyes' pedicled technique

The harvesting technique depicted in the following paragraphs has been described by Reyes and co-workers in 1995 (22). The RA is usually harvested from the nondominant upper limb, although it is convenient to harvest the left internal thoracic artery and left radial artery at the same time. Harvest of bilateral radial arteries is also possible, particularly if there is conduit shortage, and the artery of the dominant forearm can be used without compromising the patient.

The extremity is circumferentially prepared, extended and supinated on an operative arm board angled at approximately 90°s to the operating table. The extremity is secured in position with two towel clips affixed to hand towels and the arm-board wrap. The arm is left in this position for the duration of CABG. In order to shorten the operative time, it is advisable to harvest the RA in conjunction with the takedown of internal thoracic artery for CABG. A pulse oximeter probe can be placed on the thumb of the chosen hand for intraoperative monitoring of oxygen saturation.

a. Incision and harvest

A gentle curvilinear incision that mimics the rounded belly of the brachioradialis muscle is made extending from a point between the palpable biceps tendon and the prominence of the brachioradialis muscle. It is extended throughout the whole length of the forearm to a point between the tendon of the flexor carpi radialis muscle and the radial styloid at the wrist crease (Fig. 1). Prominent subcutaneous veins are properly handled for acquisition of hemostasis.

Once the subcutaneous fat has been dissected, the fascia overlying the brachioradialis muscle and the superficial flexor muscles of the forearm is divided between the bellies of the brachioradialis and the flexor carpi radialis muscles. Care is taken to keep the LABCN in the lateral compartment of the fascial division.

After division of the fascia, a careful retraction of the brachioradialis and flexor carpi radialis muscles should reveal the entire course of the RA in the forearm (Fig. 2). It is important to recog-

nize that the RA is followed in its course by two small concomitant veins and discrete amount of areolar and fat tissue, enveloped in delicate adventitial compartment ("the pedicle"). The middle zone is where the initial harvest begins. After gentle mobilization of a very small section in the middle zone, a plastic vessel loop is placed around the artery and used for fine elevation of the artery from its muscular bed. This maneuver will expose the fine dorsolateral and dorsomedial perforating branches, and should be done gently not to risk branch avulsion. Continuous delicate upward traction is applied to the vessel loop as these branches are sequentially divided between small clips. The dissection as described above continues proximal to the level of origin of the recurrent radial artery and distally to the level of origin of the superficial palmar branch, for full RA harvest (Figures 3 and 4). The recurrent radial artery should be preserved, since it may later play an important role in forearm circulation (23).

The safe perimeter of tissue dissection is at least 1 cm away from the RA. The diathermy should be mild, from 20 to 40 W according to the surgeon's preference, and should not be applied upon the artery at all time. In this fashion, the main trunk of the RA is mobilized in a pedicle fashion (with concomitant veins, areolar tissue and surrounding adventitia) with no direct contact with the vessel (no-touch technique).

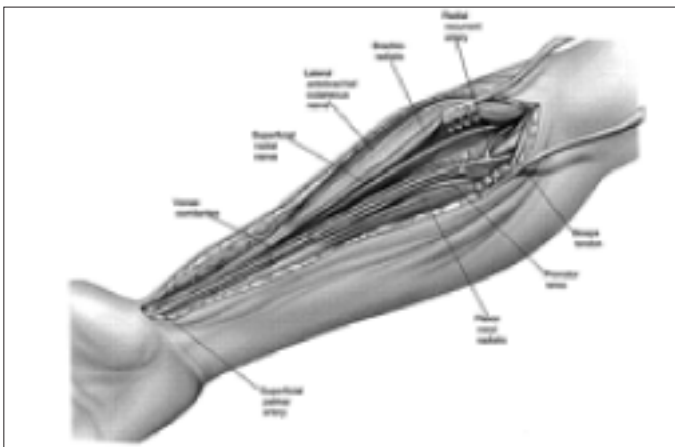


Figure 2. The course of the radial artery in the forearm

(Reprinted from ANNALS OF THORACIC SURGERY, V59: 118-126, Reyes AT et al: "Technique of harvesting ..." © 1995, with permission from the Society of Thoracic Surgeons).

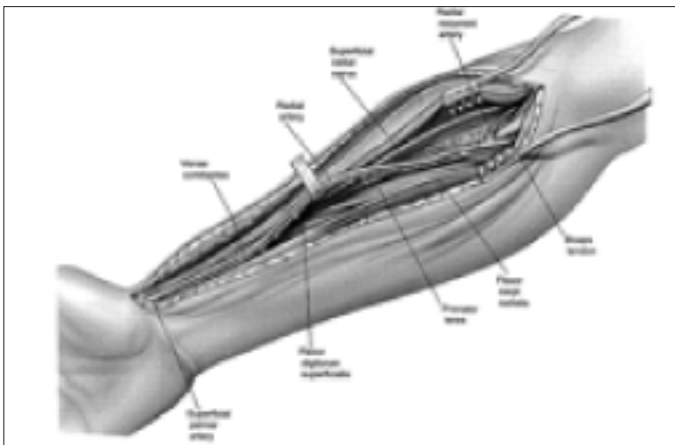


Figure 3. Mobilization of the radial artery (the no-touch technique)

(Reprinted from ANNALS OF THORACIC SURGERY, V59: 118-126, Reyes AT et al: "Technique of harvesting ..." © 1995, with permission from the Society of Thoracic Surgeons).

Apart from Reyes' experience, at this point the artery can be safely wrapped in antispasmodic-solution-soaked gauze, leaving only the proximal and distal ends of the main trunk free and available for division. This method of preservation of the artery is directed to both prevention of spasm and control of hemostasis, since even the smallest leakage sites can be easily recognized on the white gauze background. Another maneuver that helps in this setting is distal occlusion of the RA with a fine DeBakey or Dietrich vascular clamp. In this manner, the main trunk of the RA is subjected to increased pulsative pressure, a maneuver in part directed toward mechanical dilatation of the vessel and in part toward provoking any potential leakage sites. The artery is left in this position for at least 10-15 minutes before distal division. This maneuver, however, requires at least partial systemic heparinization.

Once systemic heparinization has been obtained, the artery can be divided. Distal division is done initially, followed by the proximal. After placement of a fine Dietrich occlusive vascular clamp on the distal end, a 5-0 polypropylene suture ligature is placed around the artery distally of the clamp and tied. The artery is divided with fine scissors. At this point, the blood flow through the RA can be observed under direct vision which also helps in flushing of particulate thrombi from the lumen, if any. In addition, the ulnar artery contribution to the collateral circulation of the hand can be confirmed by observation of the pulsating distal RA stump.

The proximal division follows. A 2-0 silk suture is passed around the selected point for division and tied. The artery is divided with fine scissors. The RA conduit is now wrapped in antispasmodic-solution-soaked gauze and removed from the operative field. The remaining stumps are additionally secured with a suture ligature. Hemostasis is confirmed. The forearm wound is packed with saline solution-soaked gauzes, a sterile towel and covered with plastic sheet that acts as a vapor barrier until closure of the wound can be undertaken.

b. Wound closure

Closure of the forearm wound is performed at the completion of the operation and after infusion of protamine sulfate. The closure is performed in two layers, fascial followed by skin closure. Drainage may or may not be used. No pressure dressings

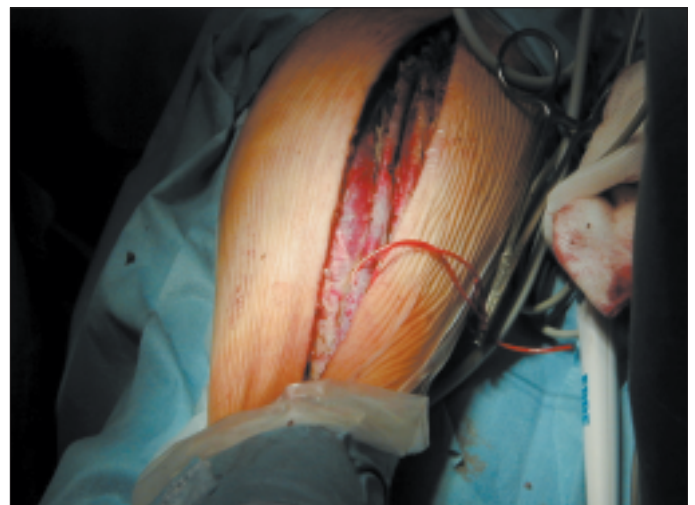

Figure 4. An intraoperative view of a radial artery harvested for purposes of CABG graft

CABG - coronary artery bypass graft

are applied. A small sterile dressing is sufficient. The dressing tape is placed in a longitudinal fashion to the volar surface of the forearm to avoid circumferential compression of the extremity. Elevation of the extremity is not necessary in the postoperative period.

Apart from Reyes' experience, others advocate suturing the subcutaneous fat layer instead of the fascia, in order to prevent postoperative compartment syndrome. Local early postoperative morbidity may involve infection or hematoma and occurs rarely, with most groups experiencing rates of 0.2-0.3%.

B. Hemiskeletonization of the RA

Hemiskeletonization refers to denudation of the volar aspect of the RA by longitudinal division of the adventitia. In this manner, "one half" of the circumference of the artery is longitudinally freed of any additional tissue, to expose the shiny volar course of the RA. This harvesting method may be preferred when performing sequential "jump" anastomoses.

C. Taggart's skeletonization technique

A skeletonization applies to a "naked" takedown of the RA, free of the concomitant veins, perivascular fat and areolar tissue as well as of the surrounding adventitia. The rationale for preferring skeletonization over the pedicled technique includes several advantages (24):

1. Extra length is provided by this technique. This is especially valuable if the RA is to be used for more than a single graft, as a sequential graft, or "recycled" to extend other grafts;

2. Improved visual inspection for identification of any spastic damaged areas that can, otherwise, be obscured by perivascular fat;

3. Sequential "jump" anastomoses and composite arterial grafting can be done more easily and with greater precision as the venae comitantes, perivascular fat, and areolar tissue do not obscure the anastomosis;

4. Aids in judgment of the length of the graft; and

5. The risks for kinks or twists of the conduit are minimized.

However, the skeletonization technique is by far technically more demanding than pedicle harvest. Careful and meticulous dissection is required. It takes approximately an additional 10-15 minutes when compared to the pedicle technique. The risk for small branch avulsion by excessive upward traction is increased. Since a more delicate manipulation is required, this technique probably induces a greater degree of spasm of the radial artery. It may be possible that due to the interrupted vasa vasorum in the adventitia, skeletonized RA is more prone to developing intimal hyperplasia.

The process of skeletonization of the RA is essentially the same as that of the pedicled technique up to the point of exposure of the vessel. Then, using fine curved-tip scissors the adventitia on the volar side of the artery is longitudinally cut for the full length of the harvested area in order to expose the "shiny" exterior of the vessel together with the concomitant veins. The plane of dissection starts immediately between the artery and the concomitant veins. Working in close proximity of the vessel, the fine areolar bridges and attachments are dissected free from the artery along its entire length. A vascular loop is placed around the artery, in a manner leaving the veins outside of the loop, and the artery is gently retracted upwards for exposure of the perforating branches. Division of the perforating branches between sets of pair of fine ligaclips follows (Fig. 5). In this manner, the entire length of the artery is skeletonized.

In Taggart's experience, only one artery has been rejected due to irreparable injury sustained during the harvest with this technique in approximately 100 cases (24). Others (25) have questioned the rationale for skeletonization of the RA. In their words, every radial artery conduit even from the small patient can reach the obtuse side of the heart or the posterior descending artery on the right side. Therefore, the artery should not be subjected to an increased risk for injury just for the sake of the length.

In order to minimize injury during harvesting, the use of ultrasonic scalpel (Harmonic Scalpel, dissecting-hook type; Ethicon Endo-Surgery, Cincinnati, OH) for fine dissection maneuvers has been reported to be safe and efficient (26). The ultrasonic scalpel converts ultrasonic energy to denature tissue proteins into a sticky coagulum that suffices hemostasis with less heat production than electrocautery (27).

D. Connolly's endoscopic radial artery harvesting technique

The endoscopic radial artery harvesting is preferred over the open-technique in order to reduce the trauma of the harvest, as well as for cosmetic reasons (28).

A small 3-4 cm incision is made over the distal RA, ending 1 cm proximal from radial styloid prominence. This segment of the artery is dissected under direct vision and isolated from surrounding tissue. Next, a small ultra-retractor with an inserted 5-mm, 30-degree endoscope is placed into the incision over the vessel, and gently forwarded proximally to "unroof" and visualize the radial artery. In addition, an ultrasonic scalpel is placed under the ultra-retractor to coagulate and cut vascular side branches and surrounding areolar tissue just outside the concomitant veins. The fascia between the brachioradialis and flexor carpi radialis muscles is divided anterior to the radial artery to allow more space for proximal insertion of the subcutaneous ultra-retractor. Segmental division of side branches with the ultrasonic means is continued toward the antecubital space until the ulnar artery origin is visualized. Next, a pigtail vessel retractor is advanced from the distal incision proximally under endoscopic vision for verification of a complete isolation of the conduit. The proximal radial artery is clipped just distal to the visualized ulnar artery, transected with endoscopic curved scissors and delivered out through the incision. The distal end is secured and the incision is irrigated with saline solution and closed with 4-0 absorbable subcuticular suture.

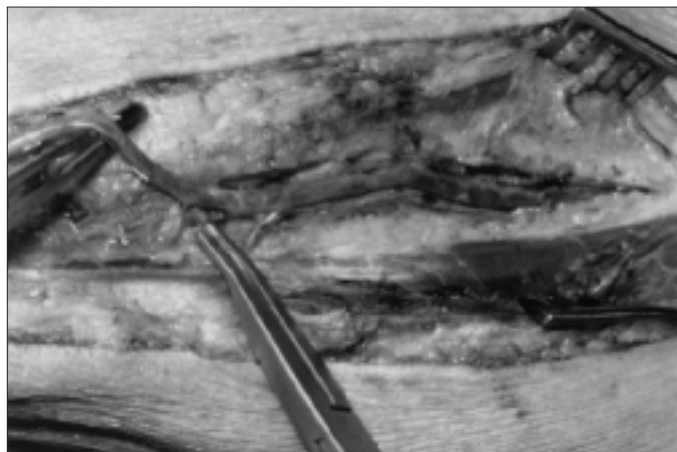


Figure 5. Skeletonization of the radial artery. The fine perforating branch is divided between a pair of small ligaclips

(Reprinted from *ANNALS OF THORACIC SURGERY*, V72: 298-299, Taggart DP et al: "Skeletonization of the ..." © 2001, with permission from Society of Thoracic Surgeons).

The authors have concluded that endoscopic radial artery harvesting technique can result in decreased incidence of hand and forearm numbness and paresthesias, less or none scar hypersensitivity and improved patient satisfaction in comparison to the open technique (28).

Perioperative Antispasmodic Methods

A. Vasoconstriction, vasospasm and its induction

Vasospasm is defined as extreme form of vasoconstriction. The later can be induced by diversity of substances. These include (29): endothelium-derived contracting factors such as endothelin, prostanoids such as thromboxane A2 and prostaglandin F_{2α}, circulating sympathomimetics (α -adrenoceptor agonists) such as norepinephrine and synthetic α 1-adrenoceptor agonists like methoxamine or phenylephrine, platelet-derived substances such as 5-hydroxytryptamine and thromboxane A2, mast cells- or basophils-derived substances like histamine, muscarinic receptor agonists such as acetylcholine, renin-angiotensin system related substances such as angiotensin II and depolarizing potassium ions.

B. Reactivity of the RA

The intrinsic contractility (reactivity) of the radial artery to various agents (endothelin, U46619, norepinephrine, KCl) was studied in vitro by He (29). In comparison with other arteries, He showed that the RA reactivity is between that of the gastroepiploic artery (representative of the splanchnic arteries, highest reactivity) and that of the coronary and somatic arteries (internal mammary artery and inferior epigastric artery, lowest reactivity). He concluded that the RA is prone to spasm, much more than the internal mammary artery.

C. Adrenergic receptors in the RA

In attempt to further investigate the nature of the spastic characteristics of the RA, the effects of the circulating perioperative catecholamines and those of the postoperative β blocker therapy on the RA spasm, He and Yang (30) conducted a study in which they characterized the adrenergic receptors in the human RA. The RA was shown to be α -adrenoceptor-dominant artery with little β -adrenoceptor function. Therefore, it was suggested that the use β -blockers will not likely evoke spasm of the radial artery. Addressing the subtypes of α -adrenoceptors, the radial artery was shown to have a dominant α 1-function. However, the postjunctional α 2-adrenoceptor was also functional. The clinical implication is that the circulating catecholamines will mainly contract the human radial artery, and the contracti-

on is mediated dominantly by activation of the α 1-adrenoceptors and, to lesser extent, the α 2-adrenoceptors. Therefore, such contraction may be efficiently blocked by α 1- and α 2-adrenoceptor antagonists.

D. Antispasmodic solutions

The use of papaverine in prevention of a vessel spasm has been suggested by George Green in 1971 (31). It was initially used on the internal mammary artery and later on the saphenous vein grafts, with very good results. Papaverine is a nonspecific vasodilator substance, which relaxes blood vessels through multiple mechanisms. One of them is through inhibition of phosphodiesterase. Others include decreased calcium influx or inhibition of the release of calcium from intracellular stores. Although this vasodilator may be used topically with good results, its solution is highly acidic at concentrations used during surgery (pH 4.4 at 2.5 mmol/L and pH 4.8 at 0.03 mmol/L (32)). Papaverine hydrochloride is relatively unstable in nonacidic solutions and a white precipitate sometimes forms when papaverine is added to plasmalyte solution (pH=7.4). Acidic solutions have been shown to damage the endothelium (33). This problem may be overcome by mixing papaverine with blood to a final concentration of 1 mmol/L (pH 7.4) or with albumin (34). Its duration of action if used topically is limited to 1 hour (35). Although criticized, papaverine has been used and is still in use as means for preventing spasm by many surgeons. Acar's standard protocol includes diltiazem as systemic vasodilator and papaverine to be used topically during harvesting (3).

Drawn by the thesis that an ideal method for preservation of the RA for CABG should be antispastic and also allow maximum preservation of the endothelial function, He and associates have compared the antispastic (36) and the endothelium-protective features (37) of the verapamil-nitroglycerin (VG) vs Papaverine solution. In both instances, the VG solution demonstrated superior results over the papaverine solution, including more rapid onset, more natural pH, superior receptor- and non-receptor mediated endothelium-dependent relaxation (23.9% vs 3.3%, and 62% vs 40%, VG vs papaverine solutions, respectively) and therefore superior preservation of the endothelial function (Table 1).

After demonstrating the effectiveness of the VG solution, He and associates at the University of Honk Kong (UHK) have developed the UHK protocol for preservation of the radial artery for CABG as demonstrated in table 2 (37).

In their experience, verapamil is more potent vascular smooth muscle relaxant. In addition, it has been suggested to have antiplatelet and antithrombotic effect in patients with coronary

Table 1. Comparison of the antispastic and endothelium-protective features of papaverine, verapamil and glyceryl trinitrate

	Papaverine (undiluted)	Verapamil	GT
Onset of effect	+	++	+++
Duration of effect	++	+++	
Spasm prevention	+	++	-
Spasm reversal	+	++	+++
Block of receptor-mediated contraction (α 1, TXA2 receptor)	+	-	+++
Blockade of depolarizing agent-mediated contraction (K ⁺)	++	+++	++
pH of solution	Acidic		Neutral
Protection of endothelium	+	+++	
None or weak (-); medium (+); strong (++); extra strong (+++)			
GT- glyceryl trinitrate			

artery disease (38), to improve the prognosis in patients who have had an infarction (39), and to inhibit smooth muscle cell proliferation in experimental vein bypass grafts .

The combination of verapamil with glyceryl trinitrate (GT) is effective in both reversing contraction and preventing contraction (spasm). These agents have different mechanisms of actions (40). The underlining mechanism of action of the GT is removal of Ca²⁺ out of the cell, by means of release of nitric oxide and subsequent stimulation of guanylate cyclase to raise cGMP. Therefore, a state of contraction (accumulation of intracellular Ca²⁺) is imperative for the action of this agent. This makes GT an agent for reversing spasm, with little efficiency toward preventing spasm. The spasm, on the other hand can be efficiently prevented by blocking the voltage-operated channels that are responsible for the entry of the Ca²⁺ ions in the cell (the mechanism of action of verapamil) (40). The duration of action of this solution is limited to 5 hours if the radial artery is immersed in it for 15 minutes (35).

Another approach to prevent perioperative spasm of the RA has been recently suggested by Taggart and co-workers and includes use of a non-selective α -adrenoceptor antagonist, like phenoxybenzamine. The theoretical background of this approach comes from the observation that the RA is α -adrenoceptor-dominant artery with prevalent α 1-function but also functional postjunctional α 2-adrenoceptor (37). If these receptors are efficiently blocked, than no adrenoceptor-mediated contraction will occur. However, the effects of the direct contraction-producing agents like K⁺ ions are not addressed. Other non-receptor-dependent contraction mechanisms are not blocked as well, making this approach semi-efficient. The duration of action exceeds 5 hours (35). Another disadvantage to this approach is the fact that it is usually limited to the perioperative period, only. The effects of postoperative administration of this agent, if any, have not been studied yet.

The future will bring other modalities of preventing RA

spasm. As suggested by Cable and associates (41), gene therapy may play a role where classic pharmacologic means for preventing spasm fail. As reported in their study, adenovirus-mediated transfer of bovine endothelial nitric oxide synthase has significantly augmented RA relaxation in vitro.

Early Postoperative Results Reported in Literature

There have been numerous reports on the early postoperative patency rates of the radial artery graft for CABG. Except for the experience in the 70's, they have all demonstrated satisfactory results.

Acar's initial experience since the revival has shown excellent patency rates. The early (two weeks) angiographic controls have depicted average patency rate of 99%, and 92% at one year in the first 75 radial arteries. String signs and stenosis were rarely noted; perfect patency rate was 89.3% for RA grafts (3). Chen and co-workers from New York have studied 60 patients with radial artery bypass grafting. Early postoperative control angiography was performed to assess the patency of 94 grafts. The patency rate of the radial graft in their series was 95.7%. The occlusion of the rest of the grafts was attributed to technical problems, competitive flow of the anastomosed coronary artery, or other unknown reasons. The average internal diameter was 2.51 mm for a 19.5% larger caliber than the anastomosed native coronary artery (5).

Mid- and Long-term Postoperative Results Reported in Literature

The experience of many authors with the RA as a CABG conduit has been satisfactory (Table 3). Gaudino and co-workers (42) in Rome have evaluated the 5 year patency rate of the RA grafts in 87 patients. In the study published in Circulation (42), they have depicted, in addition to the patency rates, the

Table 2. University of Hong Kong protocol for preservation of the RA for CABG

Preoperative	<ol style="list-style-type: none"> Allen test is used for both arms. Doppler flow exam is used for the ulnar artery during the Allen test.
Intraoperative	<ol style="list-style-type: none"> Once the harvesting of the radial artery is started, low-dose verapamil (0.5 mg/hr; 5 mg in 100 ml 5% dextrose in water, intravenously, at the rate of 10 ml/hr) is given systematically. Use VG solution topically during harvesting. The radial artery is removed as soon as it is dissected from the arm. Heparin is administrated before removal of the artery. The RA is stored in the VG solution at room temperature for at least 15 min. A 24-gauge plastic arterial puncture needle sheath is inserted into the radial artery (usually the proximal end) and the artery is gently held with the fingers. No tie is necessary. Clean VG solution is injected through the needle to flush (not distend) the radial artery with the other end freely open. This gentle flush at low pressure will not distend the artery, and its purpose is to flush out any blood clots and to test the patency of the artery. This flushing procedure is not done specifically for detecting side-branch leakage.
Postoperative	<ol style="list-style-type: none"> Intravenous verapamil is given at the same dose until the patient is able to take oral verapamil. Oral verapamil, 240 mg per day, is given for at least 12 months, maybe longer; 120 mg as the initial testing dose is recommended. If not tolerated by the patient, mainly because of bradycardia, the alternative is to give nifedipine (retard preparation), 20 mg per day. No β-blockers are given after the operation to avoid severe bradycardia as it is seen in the combined use of verapamil and β-blockers.
VG solution* components	<ol style="list-style-type: none"> Verapamil hydrochloride 5 mg; Nitroglycerin 2.5 mg; Heparin 500 units; 8.4% NaHCO₃ 0.2 ml; Ringer's solution 300 ml.
<p>* This solution gives a concentration of verapamil or nitroglycerin of about 30 mmmol/L in an isotonic solution with a pH of 7.4. CABG - coronary artery bypass graft surgery, RA - radial artery, VG- verapamil,nitroglycerin (adapted from reference 44 with changes)</p>	

lack of clinical and angiographic effect of prolonged calcium channel blockers therapy after 12 months after the operation. Those patients with continued calcium channel blockers therapy after 12 months did not have significantly higher patency and perfect patency rates (97.7% and 93.3%, respectively) than the others who had their diltiazem stopped at the 12th month postoperatively (97.6% and 95.2%).

Acar and co-workers at the Bichat Hospital and Carpentier and associates at the Broussais Hospital, both in Paris, have performed radial artery CABG on 910 patients until 1997. In a period of 4 to 7 years after the operation, angiographic study was carried out on 50 patients for a total of 64 RA grafts. The findings included 10 occluded grafts, one graft with a string sign, and 53 grafts (83%) with perfect patency rate. A careful search for possible factors that might have contributed to the occlusion of the grafts revealed competitive flow of a significant stenosis-free native coronary artery and poor distal runoff vessel. Other factors influencing graft patency including RA specific factors have not been found. Three cases lacked hemodynamic explanation for the occlusion of the RA graft (43). Calafiore's group in Chieti, Italy has been using the RA for CABG since 1992. In 2001, they have published their long-term results on 164 patients (44). The patency rate of RA at angiographic control, both early and late, was higher than 90%, approaching the values of the internal mammary artery. In their experience, the string sign was not found in the late angiographic control. One possible explanation for this finding is that RA was only grafted to coronary artery with a stenosis of 80% or higher. In addition, they have attempted to address the influence of the proximal grafting strategy on the late patency. The authors did not find significant influence of the site of proximal grafting of the radial conduit (IMA vs. ascending aorta) on the long-term patency. In another study (45), the same group from Chieti, Italy, has attempted to evaluate whether the radial artery provides the same results as the right internal mammary artery in lateral wall revascularization in the long

of 105±9 months, the angiographic results on 90 patients revascularized with the RA showed superior results. All RAs were proximally anastomosed on the ascending aorta. The patency rate was 91.6% and the perfect patency rate was 88%. The comparison with the left internal mammary artery and saphenous vein grafts patency rates is shown in table 4.

The patency and perfect patency difference between LIMA and RA has not reached statistical significance, in contrast to the significantly lower patency rates of the vein grafts when compared to the RA. In addition, the authors have concluded that neither the location of the distal anastomosis nor the long-term use of the calcium channel blockers influenced the patency. In contrast, the only factor that influenced the long-term patency was the severity of the stenosis of the target vessel.

Although vast majority of the knowledge regarding the use of RA as a conduit in CABG came in the last 10 years, there are still unanswered questions and dilemmas. One of them is the controversy regarding the proximal anastomotic site of the RA, whether it has to be a LIMA or the ascending aorta directly. At least one group (19) postulated that placement of a third- or fourth-order artery on the aorta could impose abnormal and potentially harmful shear stress on the conduit, being the radius of the aorta is bigger than the radius of the vessel from which the RA natively originates. Reports from the literature, in which the patency rate of the free IMA grafted proximally to the aorta is uniformly shown lower than the patency rate of in situ IMA, support this hypothesis. This policy is followed by many groups, but still others (5, 6, 43) prefer to anastomose the RA directly on the aorta. Patency rate seems to be satisfactory with both techniques. Apart of the proximal inflow, the nature of the distal outflow may affect the patency to a higher degree. Several groups have observed that the less critical the stenosis of the native coronary is, the lower the patency of the radial graft may be (47). Competitive flow may be the reason. In one of the largest re-

Table 3. The mid-term results with the RA as a CABG conduit vessel from different investigators

Year	Author	RA grafts assessed, n	Patent RA, %	Perfect patency, %
1992	Acar (48)	31	93.5	90.3
1994	Calafiore (39)	17	94.1	94.1
1995	Calafiore (13)	35	94.3	NA
1996	Da Costa (4)	12	100	100
1996	Monasse (14)	57	96.5	64.9
2001	Gaudino (42)	42	97.6	95.2
2003	Possati (38)	90	91.6	88
2004	Desai (40)	440	91.8	84.8

RA- radial artery, NA - not available

term. After a mean of 35±28 months of angiographic follow-up, the patency of the RA was 99% and that of the RIMA was 100%. The overall follow-up was 77±16 months; the event-free survival was 84.2% vs. 88.9% and the actuarial survival was 86.7% vs. 89.6% (RA vs. RIMA, respectively) without statistical significance in the difference.

In the first study published on long-term clinical and angiographic results with the use of the RA for myocardial revascularization, Possati and coworkers from the Catholic University in Rome describe their 10-year-experience (46). After a follow-up

Table 4. Comparison of the patency and perfect patency rates of LIMA, RA and GSV grafts used for myocardial revascularization at 10 years postoperatively

Conduit	Patency, %	Perfect patency, %
LIMA	97.5	96.3
RA	91.6	88
GSV	67.1	53.4

GSV- great saphenous vein, LIMA- left internal mammarian artery, RA- radial artery (adapted from reference 48 with changes)

ports on the use of the RA for coronary surgery, Tatoulis et al. have observed that the patency of the RA was least in the RCA territory, especially in RCA with less than critical stenosis (47). In their extensive experience, the RA was patent in 90.7%, 92.5% and 86.7% when grafted to the left anterior descending, left circumflex or the right coronary system, respectively, for a total patency rate of 90.2%. The authors further speculate that those RAs that are patent and are functioning well, beyond 1 year, should continue to do so into the long term.

To date, most surgeons will agree that the radial artery is better than the vein in terms of durability as conduit for coronary revascularization. It is easy to use and handle, and with proper antispastic measures, will provide satisfactory mid- and long-term patency rates. It is still unclear if the RA is better or inferior than the right internal thoracic artery in terms of long-term patency due to limited data available. Furthermore, its use in reoperations may allow for additional conduit choice, reduce donor site and sternal infections, and may avoid further late venous graft failure.

All these observational studies have answered only few of the questions regarding the role of the radial graft in CABG. Soon, the results from three ongoing large prospective randomized studies, namely the RAPCO (Radial artery patency and clinical outcome), the RAPS (Radial artery patency study) and the VA comparative study, will be available, for a more clear establishment of the role and place of the radial graft in coronary surgery.

References

- Carpentier A, Guernonprez JL, Deloche A, Frechette C, DuBost C. The aorta-to-coronary radial artery bypass graft. A technique avoiding pathological changes in grafts. *Ann Thorac Surg* 1973;16:111-21.
- Curtis JJ, Stoney WS, Alford WC Jr, Burrus GR, Thomas CS Jr. Intimal hyperplasia: a cause of radial artery aortocoronary bypass graft failure. *Ann Thorac Surg* 1975;20:628-35.
- Acar C, Jebara VA, Portoghese M, Beyssen B, Pagny JY, Grare P, et al. Revival of the radial artery for coronary artery bypass grafting. *Ann Thorac Surg* 1992;54:652-60.
- Mert M, Bakay C, Bakir I, Ozkan AA, Okcun B, Aydemir NA. Bilateral internal thoracic artery grafting in diabetic patients: perioperative risk analysis. *Anadolu Kardiyol Derg* 2004;4:290-5.
- Chen AH, Nakao T, Brodman RF, Greenberg M, Charney R, Menegus M, et al. Early postoperative angiographic assessment of radial grafts used for coronary artery bypass grafting. *J Thorac Cardiovasc Surg* 1996;111:1208-12.
- da Costa FD, da Costa IA, Poffo R, Abuchaim D, Gaspar R, Garcia L, et al. Myocardial revascularization with the radial artery: a clinical and angiographic study. *Ann Thorac Surg* 1996;62:475-9.
- Acar C, Jebara VA, Portoghese M, Fontaliran F, Dervanian P, Chachques JC, et al. Comparative anatomy and histology of the radial artery and the internal thoracic artery. Implication for coronary artery bypass. *Surg Radiol Anat* 1991;13:283-8.
- He G-W, Yang C-Q. Comparison among arterial grafts and coronary artery: an attempt at functional classification. *J Thorac Cardiovasc Surg* 1995;109:707-15.
- Ercan E, Tengiz I. Idiopathic radial artery aneurysm. *Anadolu Kardiyol Derg* 2003;3:287.
- Gaudino M, Tondi P, Serricchio M, Spatuzza P, Santoliquido A, Flora R, et al. Atherosclerotic involvement of the radial artery in patients with coronary artery disease and its relation with midterm radial artery graft patency and endothelial function. *J Thorac Cardiovasc Surg* 2003;126:1968-71.
- Tonks AM, Lawrence J, Lovie MJ. Comparison of ulnar and radial arterial blood-flow at the wrist. *J Hand Surg (Br)* 1995;20:240-2.
- Riekkinen HV, Karkola KO, Kankainen A. The radial artery is larger than the ulnar. *Ann Thorac Surg* 2003;75:882-4.
- Johnson M, Ford M, Johansen K. Radial or ulnar artery laceration. Repair or ligate? *Arch Surg* 1993;128:971-4.
- Fuhrman TM, Pippin WD, Talmage LA, Reilley TE. Evaluation of collateral circulation of the hand. *J Clin Monitor* 1992;8:28-32.
- Johnson WH, Cromartie RS, Arrants JE, Wuamett JD, Holt JB. Simplified method for candidate selection for radial artery harvesting. *Ann Thorac Surg* 1998;65:1167.
- Pola P, Serricchio M, Flore R, Manasse E, Favuzzi A, Possati GF. Safe removal of the radial artery for myocardial revascularization: a Doppler study to prevent ischemic complications to the hand. *J Thorac Cardiovasc Surg* 1996;112:737-44.
- Starnes SL, Wolk SW, Lampman RM, Shanley CJ, Prager RL, Kong BK, et al. Noninvasive evaluation of hand circulation before radial artery harvest for coronary artery bypass grafting. *J Thorac Cardiovasc Surg* 1999;117:261-6.
- Brodman RF, Frame R, Camacho M, Hu E, Chen A, Hollinger I. Routine use of unilateral and bilateral radial arteries for coronary artery bypass graft surgery. *J Am Coll Cardiol* 1996;28:959-63.
- Calafiore AM, Di Giammarco G, Toedori G, D'Annunzio E, Vitolla G, Fino C, et al. Radial artery and inferior epigastric artery in composite grafts: improved mid-term angiographic results. *Ann Thorac Surg* 1995;60:517-23.
- Funk GF, Valentino J, McCulloch TM, Graham SM, Hoffman HT. Anomalies of forearm vascular anatomy encountered during elevation of the radial forearm flap. *Head Neck* 1995;17:284-92.
- Manasse E, Sperti G, Suma H, Canosa C, Kol A, Martinelli L, et al. Use of the radial artery for myocardial revascularization. *Ann Thorac Surg* 1996;62:1076-82.
- Reyes AT, Frame R, Brodman RF. Technique of harvesting the radial artery as a coronary artery bypass graft. *Ann Thorac Surg* 1995;59:118-26.
- Mansuroglu D, Omeroglu SN, Gokseded D, Izgi A, Kirali K, İpek G, et al. Does radial artery harvesting cause any changes in the forearm circulation during the postoperative period? An angiographic study. *Anadolu Kardiyol Derg* 2004;4:149-52.
- Taggart DP, Mathur MN, Ahmad I. Skeletonization of the radial artery: advantages over the pedicle technique. *Ann Thorac Surg* 2001;72:298-9.
- Bizzarri F, Frati G. Harvesting of the radial artery: skeletonization versus pedicled technique. *Ann Thorac Surg* 2002;73:1357-61.
- Amano A, Takahashi A, Hirose H. Skeletonized radial artery grafting: improved angiographic results. *Ann Thorac Surg* 2002;73:1880-7.
- Higami T, Maruo A, Yamashita T, Shida T, Ogawa K. Histologic and physiologic evaluation of skeletonized internal thoracic artery harvesting with an ultrasonic scalpel. *J Thorac Cardiovasc Surg* 2000;120:1142-7.
- Connolly ET, Torrillo LD, Stauder MJ, Patel NU, McCabe JC, Loulmet DF, et al. Endoscopic radial artery harvesting: results of first 30 patients. *Ann Thorac Surg* 2002;74:502-6.
- He GW, Yang CQ, Starr A. An overview of the nature of vasoconstriction in arterial grafts for coronary surgery. *Ann Thorac Surg* 1995;59:676-83.
- He GW, Yang CQ. Characteristics of adrenoceptors in the human radial artery: clinical implications. *J Thorac Cardiovasc Surg* 1998;115:1136-41.
- Green GE. Rate of blood flow from the internal mammary artery. *Surgery* 1971;70:809-13.
- Rosenfeldt FL, He GW, Buxton BF, Angus JA. Pharmacology of coronary artery bypass grafts. *Ann Thorac Surg* 1999;67:878-88.
- Constantinides P, Robinson M. Ultrastructural injury of arterial en-

- dothelium. I. Effects of pH, osmolarity, anoxia, and temperature. *Arch Pathol* 1969;88:99-105.
34. Roberts AJ, Hay DA, Jawahar LM, et al. Biochemical and ultrastructural integrity of the saphenous vein conduit during CABG: preliminary results of the effect of papaverine. *Thorac Cardiovasc Surg* 1984;88:39-48.
 35. Mussa S, Guzik TJ, Black E, Dipp MA, Channon KM, Taggart DP. Comparative efficacies and duration of action of Phenoxybenzamine, verapamil/nitroglycerin solution, and papaverine as topical antispasmodics for radial artery coronary bypass grafting. *J Thorac Cardiovasc Surg* 2003;126:1798-805.
 36. He GW, Yang CQ. Use of verapamil and nitroglycerin for preparation of the radial artery for coronary bypass grafting. *Ann Thorac Surg* 1996;61:610-4.
 37. He GW. Verapamil plus nitroglycerin solution maximally preserves endothelial function of the radial artery: comparison with papaverine solution. *J Thorac Cardiovasc Surg* 1998;115:1321-7.
 38. Lacoste L, Lam JYT, Hung J, Waters D. Oral verapamil inhibits platelet thrombus formation in humans. *Circulation* 1994;89:630-4.
 39. The Danish Study Group on Verapamil in Myocardial Infarction. Effect of verapamil on mortality and major events after acute myocardial infarction (The Danish Verapamil Infarction Trial II-DAVIT II). *Am J Cardiol* 1990;66:779-85.
 40. He GW, Rosenfeldt F, Buxton B, Angus JA. Reactivity of human isolated internal mammary artery to constrictor and dilator agents. Implications for treatment of internal mammary artery spasm. *Circulation* 1989;80(Suppl):I-141-50.
 41. Cable DG, Caccitolo JA, Pfeifer EA. Endothelial regulation of vascular contraction in radial and internal mammary arteries. *Ann Thorac Surg* 1999;67:1083-90.
 42. Gaudino M, Glieca F, Luciani N, Alessandrini F, Possati G. Clinical and angiographic effects of chronic calcium channel blockers therapy continued beyond first postoperative year in patients with radial artery grafts. Results of a prospective randomized investigation. *Circulation* 2001;104(suppl I):I64-7.
 43. Acar C, Ramsheyyi A, Pagny JY, Jabara V, Barrier P, Fabiani JN, et al. The radial artery for coronary artery bypass grafting: clinical and angiographic results at five years. *J Thorac Cardiovasc Surg* 1998;116:981-9.
 44. Iaco AL, Teodori G, Giammarco GD, Di Mauro M, Storto L, Mazzei V, et al. Radial artery for myocardial revascularization: long-term clinical and angiographic results. *Ann Thorac Surg* 2001;72:464-9.
 45. Calafiore AM, Di Maura M, D'Alessandro S, Teodori G, Vitolla G, Contini M, et al. Revascularization on the lateral wall: Long-term angiographic and clinical results of radial artery versus right internal thoracic artery grafting. *J Thorac Cardiovasc Surg* 2002;123:225-31.
 46. Possati G, Gaudino M, Prati F, Alessandrini F, Trani C, Glieca F, et al. Long-term results of the radial artery used for myocardial revascularization. *Circulation* 2003;108:1350-4.
 47. Tatoulis J, Royse AG, Buxton BF, Fuller JA, Skillington PD, Goldblatt JC, et al. The radial artery in coronary surgery: A 5 year experience - Clinical and angiographic results. *Ann Thorac Surg* 2002;73:143-8.
 48. Chiu CJ. Why do radial artery grafts for aortocoronary bypass fail? A reappraisal. *Ann Thorac Surg* 1976;22:520-3.