

Acetabular fractures treatment needs in the elderly and nonagenarians

Julia Riemenschneider^{ORCID}, Jan Tilmann Vollrath, Nils Mühlenfeld, Johannes Frank, Ingo Marzi and Maren Janko

Department of Trauma-, Hand- and Reconstructive Surgery, Goethe University, Frankfurt, Germany

Correspondence should be addressed to J Riemenschneider

Email
julia.riemenschneider@kgu.de

- Different treatment options for acetabular fractures in the elderly and nonagenarians exist; a consistent guideline has not been established, yet. The purpose of this study is to give an overview of how those fractures can be handled and compares two different surgical treatment methods.
- A total of 89 patients ≥ 18 years between 2016 and 2021 with acetabular fractures in our department received a surgical intervention with plate fixation via the Stoppa approach or a total hip arthroplasty with a Burch–Schneider ring and integrated cup. 60 patients ≥ 65 were compared in two groups, 29 patients between 65 and 79 and 31 patients ≥ 80 . For comparison, data on operation times, hospitalization, complications during operation and hospital stay, blood loss and postoperative mobilization were collected.
- Characteristics could be found for indications for operative osteosynthesis or endoprosthetics based on the X-ray analysis. There was a tendency to treat simple fractures with osteosynthesis. Patients between 65 and 79 with an osteosynthesis had benefits in almost every comparison. Patients ≥ 80 with a plate fixation had advantages in the categories of postoperative complications, blood loss and transfusion of erythrocyte concentrates. Statistical significant differences were noticed in both groups regarding the operation time. Patients between 65 and 79 with osteosynthesis had significant benefits for postoperative complications, hospitalization, number of blood transfusions and postoperative mobilization.
- Finding the best supportive treatment option is difficult, and decision-making must respect fracture patterns and individual risk factors. This study shows that plate fixation via the Stoppa approach has some benefits.

Keywords

- ▶ acetabular fracture
- ▶ Stoppa approach
- ▶ MUTARS® RS Cup System

EFORT Open Reviews
(2022) 7, 433–445

Acetabular fracture treatment needs in the elderly and nonagenarians

Relevance of acetabular fractures in the elderly

Acetabular fractures are relevant injuries not only in young patients, but also in adults and the elderly population. While acetabular fractures are mostly associated with high-energy injuries, such as falls from great heights and traffic accidents, acetabular fractures in the elderly are more often caused by low-energy trauma, like falls from stairs, lower heights or even bending (1, 2).

The reasons are poor bone quality due to osteoporosis, inactivity, frailty and loss of muscles (3, 4, 5, 6, 7, 8). Mostly these injuries lead to proximal femur fractures and petrochanteric fractures, with largely accepted surgical therapies using various types of hip arthroplasty or gamma-nailing (9, 10, 11). In the elderly population, acetabular

fractures are common and represent 20% of osteoporotic pelvic fractures (12). Nowadays, many different treatment options exist. Due to the high mortality rate between 24 and 44% relating to those fractures, choosing the optimal therapy individually can be very challenging (7). As the older generation increases, the difficulty of finding predictive criteria for choosing conservative or operative treatment methods in acetabular fractures gets more attention. In a statistical analysis of Audretsch *et al.*, the female gender and older age are discussed as negative prognostic values for surgical management (13). Furthermore, osteoporosis or complex fracture patterns could lead to worse postoperative outcomes (14).

Classifications for hip and acetabular fractures

The relevance of pelvic ring fractures in the elderly has been nicely described by Rommens *et al.* introducing a

fragility fractures classification (15). This classification has been widely accepted and led to concept of conservative or surgical therapy (15). As the acetabulum is a part of the pelvis and its stability is dependent on the pelvic ring, acetabular fracture treatment has to respect the pelvic ring stability as well as the congruence of the hip joint. While in young patients mostly the primary reconstruction is the first choice for surgery, this has not been clearly defined for acetabular fractures in the elderly. Over the past decades, various classification systems have been established for describing the various patterns of acetabular fractures. Relating to radiological data (X-rays and 3D CT scans), the Letournel and Judet classification has described the principles of acetabular fracture classification pattern (16). This classification has been adapted and expanded by others, mostly known as the AO classification (17). All of them give an overview of the complexity and stability of acetabular fractures and aim to provide surgical decision-making for young adults, but it is a complex system. However, there is no direct recommendation to facilitate the choice of the right operative treatment (16, 18, 19). The anterior and posterior pillars of the acetabulum and walls must be, as anatomically as possible, reduced and fixed and transverse fractures are observed above or within the hip joint. In addition, the cartilage disruption should be reconstructed as accurately as possible. If not, the development of hip joint arthritis in young patients as well can occur in about 10 % (20), whereas, in the older population, hip arthritis is usually already present.

Acetabular fracture types in the elderly

In older patients, the pattern of acetabular fractures differs, in particular, in posterior instability, dislocation is rare and dual pillar and transverse fracture fewer than in younger patients. On the other hand, protrusion of the femoral head often leads to protrusion of the anterior column and the quadrilateral plate (21, 22). In addition, pre-existent arthritis or additional injury to the head might take place. Thus, the injury patterns of acetabular fractures in the elderly seem more constant, and therefore, the protrusion of the head into the pelvis seems important. Actually, it seems a question of maintenance of the containment of the acetabulum itself and the hold of the femoral head. Thus, there are different patterns of acetabular fractures in the elderly. However, based on the actual literature and orientating to the Letournel classification, the following three acetabular fractures are most frequent: first, both columns fracture (26.4–28 %); secondly, the anterior column fracture with affection of the posterior hemitransverse (ACPHT, 14.9–24 %) and thirdly, the isolated anterior column fracture (11.4–19.2%) (21, 23, 24, 25). Those fractures are illustrated in Fig. 1.

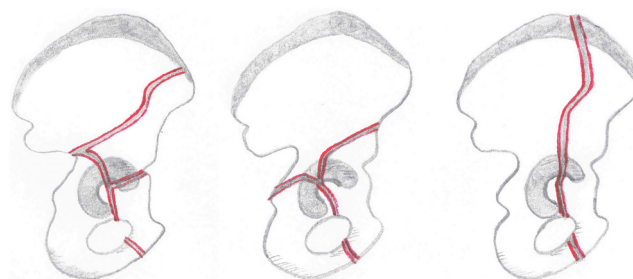


Figure 1

Most frequent fracture pattern in the elderly. Orientating on the Letournel classification from left to right: both column fracture, anterior column and posterior hemitransverse fracture (ACPHT) and single anterior column fracture.

Overview of treatment options for acetabular fractures in the elderly

The treatment options for acetabular fractures in the elderly range from conservative over minimal invasive or open reconstruction to primary or secondary hip replacement. In respect to this, a few overviews in the literature have been published the last years (25, 26). However, during the past decades, operative treatment of acetabular fractures has developed and become a standard nowadays. There are three different principles: reduction and osteosynthesis or primary total hip arthroplasty (THA) without or with a Burch–Schneider ring and lastly combined treatment methods (2, 22, 26, 27). The ideal therapy regime is dependent on fracture pattern, individual risk factors and the availability of the treatment method in the trauma center. Acetabular fractures can generally be treated conservatively or operatively. Conservative treatments have often been performed in former decades due to the difficulty of operative methods. Ochs *et al.* showed in a retrospective analysis of almost 1300 acetabular fractures between 1991 and 2006 that choosing non-operative treatment was reduced from 48 to 28% (2). Moreover McCormick *et al.* reported (2021) that a conservative therapy regime is still performed in 46.14% in a retrospective study with an average age of 72 years (26). Even if the possibility of a conservative therapy regime in acetabular fractures exists, the higher mortality rate in these cases must be considered. This can be 30% higher than in surgically treated acetabular fractures as a result of prolonged bed rest, inconsequent mobilization or bad pain management (7, 12, 23, 27). Indications for a conservative therapy are simple, not dislocated fractures or inoperable, moribund patients (12). A radiological example can be seen in Fig. 2. Comparisons of operative treatments of acetabular fractures in the elderly have shown that open reduction and internal fixation (ORIF) has been more often performed and the ilioinguinal and the intrapelvic approaches are the most commonly

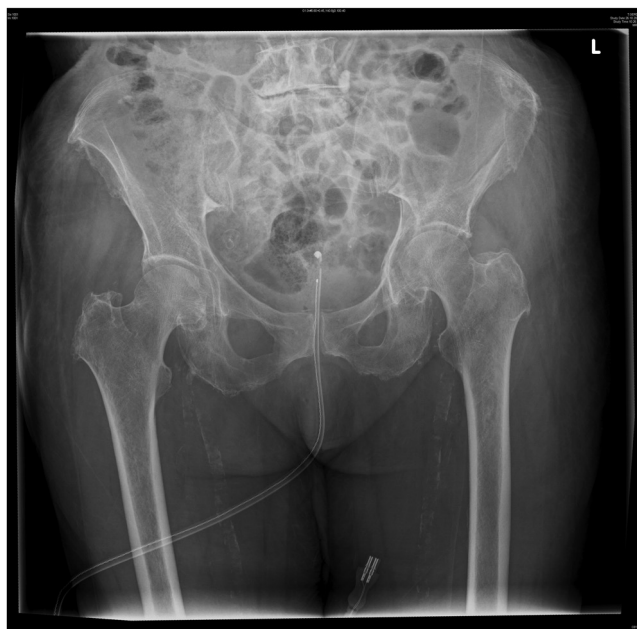

Figure 2
X-ray of a conservatively treated acetabular fracture: acetabular fracture on the left of 80 years old female after low-energy trauma. An operative treatment had been discussed with the patient, but due to her age, she wanted to try a conservative treatment. With the help of a physiotherapist, she was able to walk under partial weight-bearing on the left with crutches. A post mobilization X-ray did not show any further dislocation of fracture fragments.

used (2, 22, 26). Besides those results, McCormick *et al.* mentioned further opportunities for treating acetabular fractures in combined (ORIF+THA) proceedings with an incidence of 3.7% or a closed reduction and percutaneous pinning (CRPP) under CT navigation with an incidence of

5.6% (26). The division of all treatment options can be seen in Fig. 3.

The approach to the acetabulum and reconstruction in the elderly

Depending on the fracture location, there are tendencies of performing one or the other approach. For example, in case of an affection of the anterior column/wall and transverse fractures for a long time, the ilioinguinal approach has been chosen and was the method of choice over decades for stabilization of the anterior column (2, 16, 20, 28). In case of an impression of the quadrilateral surface and protrusion of the femoral head, the modified Stoppa (intrapelvic) or pararectus approach has gained popularity (2, 22, 28). Another one is the dorsal approach. While dorsal stabilization of the acetabulum, or even more complex reconstruction with other approaches, is less often required in elderly but more often in younger patients, this will not be further discussed here (21). However, after the introduction of the modified Stoppa approach and the development of surgical instruments and implants for that, this approach has become the most popular access (20, 28, 29). The major advantage of the modified Stoppa approach, or the pararectal approach respectively (30, 31), is the far better reduction and buttressing of the displaced anterior column, the os pubis and the quadrilateral plate. Due to the importance of this study, the modified Stoppa approach will be more discussed in the following: fracture preparation includes the Pfannenstiel incision, superficial and deep preparation, finding the Retzius space. Protection of the bladder is as important as developing the corona mortis, the femoral and obturator nerve and the external iliac and obturator vessels. Problems affecting these are typical complications of this technique (28, 31, 32), but on

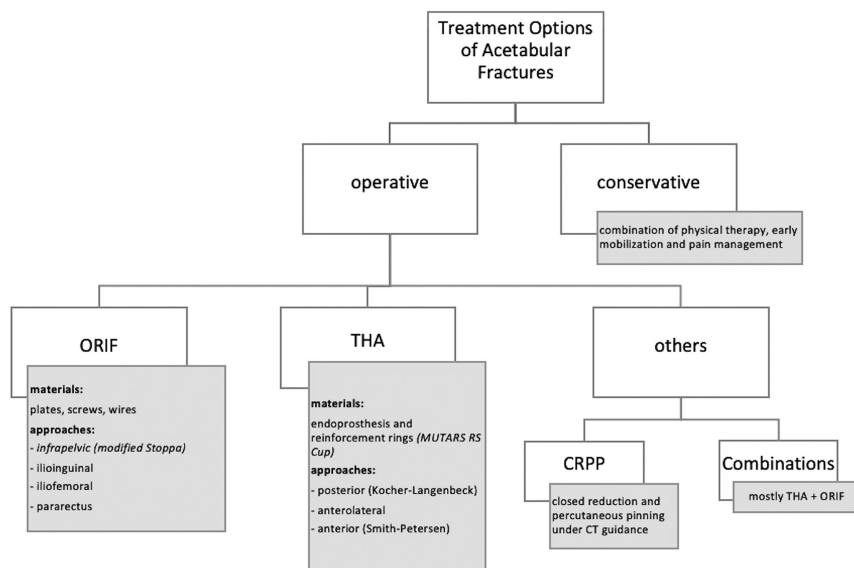


Figure 3
Treatment options. This graphic shows the different treatment options of acetabular fractures described in the actual literature for elderlies and nonagenarians.

the other hand, a stable fixation of the acetabulum allows sometimes full weight-bearing in older patients. However, severe osteoporosis may not allow a good grip on the screws, so that there are limitations to its use (4, 23). This is the result of a retrospective study by Anglen *et al.* 2003 when they reasoned that due to osteopenic bone, patients did not have satisfying radiological outcomes after open reduction and internal fixation alone (4).

Extended total hip arthroplasty in acetabular fractures

Due to the benefit of post-operative possible full mobilization, total hip arthroplasty (THA) is often proposed for acetabular fractures in the elderly population. In addition, pre-existent hip joint degenerations support the idea of immediate – one step – THA (23, 26, 33). As well as for ORIF for the THA, different approaches exist. The most frequently used is the posterior (Kocher–Langenbeck) with the anterolateral and anterior (Smith–Peterson) following (34). However, a THA is only possible with a standard uncemented or cemented acetabular cup if the containment of the acetabulum is stable enough (2). If not, this approach is not possible and additional measures are necessary, with additional plate osteosynthesis of the pelvic ring or acetabulum and subsequent immediate (26, 33) or rather later the implantation of an acetabular cup (35, 36, 37, 38). As an alternative, the implantation of a Burch–Schneider ring is possible in many cases, in particular when the os ischium is intact and a fracture of the os ileum can be overcome by this ring (37, 39, 40). In those cases, usually a low-profile polyethylene cup is cemented into a Burch–Schneider ring (38, 39, 40, 41).

A newer but less frequently used technique is the use of a MUTARS RS cup system via the anterolateral approach instead. It is mainly associated with indications for operative revision surgery of THA with concomitant bone defects. In the author's experience, it also has been an established treatment option for primary acetabular fracture stabilization (38). The advantage of such a system is the integration of a cup into the Burch–Schneider ring, so that there will be no cement as additional interface. Both the Burch–Schneider ring and the MUTARS® RS cup are also associated with complications like increased blood loss and prosthetic dislocation (39, 40).

As a solution, a tripolar avoiding dislocation of the hip joint is an additional option. Janko *et al.* mentioned recently that a tripolar cup is a good alternative for recurrent dislocation after THA or in unstable situations. It is a bipolar anchoring system, which can be added to the cup. Unfortunately, it is not compatible with a Burch–Schneider ring (38).

A secondary THA after a conservatively treated acetabular fracture or the primary trial of ORIF is hardly discussed in the literature. The initial trauma tissue damage or osteonecrosis caused due to earlier operations

results in even more complicated revisions. This increases the intraoperative risk of bleedings and further intra- and postoperative complications (23, 33, 42).

Comparison of osteosynthesis via Stoppa approach and THA with an integrated Burch–Schneider ring for the treatment of acetabulum in the elderly population and nonagenarians

Due to the still unclear decision-making how to treat displaced acetabular fractures in old people, we retrospectively evaluated our patients over the last 6 years. Actually, we compared the cases with osteosynthesis applying the modified Stoppa approach with those receiving an integrated Burch–Schneider ring with an acetabular cup, in respect of surgery, postoperative course, complications and short-term outcome.

Acetabular reconstruction or THA – in the elderly – a retrospective study

Study design and setting

Prior to performing this retrospective study, the approval from the institutional review board and ethics committee of the Goethe University medical faculty (01/22) was obtained. The authors followed the STROBE guidelines for observational studies (Strengthening the Reporting of Observational Studies in Epidemiology) and the RECORD guidelines (Reporting of studies Conducted using Observational Routinely collected Data) (43). A retrospective review was performed on a consecutive cohort of all patients with an isolated fracture of the acetabulum that was treated surgically at the authors' institution between January 2016 and December 2021 around the age of 65 and older. Two groups were built for a better comparison – one group of patients between 65 and 79 and another ≥ 80 including nonagenarians. Patients were identified via a retrospective systematical query in the Hospital Information System (HIS) using the International Statistical Classification of Diseases and Related Health Problems Version 10 (ICD-10) codes of the German Diagnosis-Related Groups (G-DRG). Patients' characteristics as well as disease-specific aspects were manually transferred from the patient's history HIS to a digital database. Every patient was checked twice in view of G-DRG code and clinical information to exclude falsely coded patients.

Primary diagnostic and operative treatment

In this retrospective study, patients with isolated acetabular fractures with only minor additional injuries (e.g. sacral or radial fractures) but excluding difficult polytrauma were included. Inclusion time was between January 2016 and December 2021 and the need for

operative treatment. Every patient was primary or secondly surveyed in the emergency department of the Department of Trauma, Hand and Reconstructive Surgery at the University Hospital in Frankfurt am Main, Germany, and treated in our institution. Following primary care, preoperative preparation of the operative procedure was performed. After the operation, further treatment was usually carried out at a surgical ICU or intermediate care unit and last data were obtained prior to discharge from the hospital.

The indication for reconstruction or replacement was taken during the regular trauma board meetings. However, as it is a retrospective study, the final reasons for method undertaken were multifactorial, depending mostly on the anatomical situation and also on bone stock and the possible compliance of the patients.

For osteosynthesis suprapectineal plates, infrapectineal plates (Fa. Stryker GmbH & Co. KG, Duisburg, Germany) or reconstruction plates (Depuy Synthes Fa. Johnson&Johnson Medical GmbH, Norderstedt, Germany) were used via the modified Stoppa approach (group Stoppa). For joint replacement, the MUTARS® RS Cup System with an integrated Burch–Schneider ring (Implantcast GmbH, Buxtehude, Germany) was applied in a THA (group MUTARS). We compared patients aged between 65 and 79 and patients ≥ 80 years old including nonagenarians.

For the analysis of the single-post traumatic x-rays, we included patients with acetabular fractures younger than 65 in interest to produce larger cohorts.

Outcome data

The main criteria for comparing those two types of surgical interventions are the operation time, days of hospitalization before and after the operative treatment, the difference in hemoglobin levels between the date of admission and discharge and the need for transfusions by erythrocyte concentrate. We also compared the appearance of intraoperative and postoperative complications and if every single patient could reach the performance target at discharge from the hospital by looking at the postoperative strain arrangements. Patients treated with a plate fixation in the Stoppa group were – depending on the type of fracture – allowed to be mobilized with 20% partial weight-bearing or sole contact for the first 6–8 weeks. In the MUTARS group, half of the group was allowed to be mobilized by full weight-bearing and the other half by 20% partial weight-bearing.

Regarding the X-ray analysis, for finding particular criteria for one or the other treatment option, patients were divided into different groups based on fracture patterns.

Statistical analysis

The measured values are given in mean and s.d.. The data were not normally distributed; so for statistical comparison, the Mann–Whitney *U* test was performed (IBM SPSS Statistics, Version 27). Statistical significance was considered at $P < 0.05$.

Results

Demographics

Between January 2016 and December 2021, 89 patients with acetabular fractures were treated surgically in the author’s department. Final data for statistical analyses included 60 patients ≥ 65 years. The average age at time of operation was 80.15 ± 36.45 years (range: 66–96 years) and 21 were female and 39 male.

Mode of surgical treatment

We included fractures caused by direct trauma, pathological trauma and periprosthetic trauma in both groups.

In this retrospective study, 60 patients were recruited – 38 were treated with a plate fixation – 23 suprapectineal plates (Fa. Stryker GmbH & Co. KG, Duisburg, Germany), 13 infrapectineal plates (Fa. Stryker GmbH & Co. KG, Duisburg, Germany), 2 different reconstruction plates (Depuy Synthes Fa. Johnson&Johnson Medical GmbH, Norderstedt, Germany via the modified Stoppa-approach (group Stoppa) or 22 with the MUTARS® RS Cup System (Implantcast GmbH, Buxtehude, Germany) in a THA (group MUTARS) in our department during the last 6 years. We compared patients between 65 and 79 years old and all with an age ≥ 80 .

Outcome data of patients between 65 and 79 years

The following results are listed in detail in [Table 1](#).

The mean age of all 29 patients in this group was 72.97 ± 4.31 years – 6 were females and 23 males.

Mean operation time in all 22 cases using the Stoppa approach and a plate fixation was 120.82 ± 59.04 min (min) and in all 7 cases using the MUTARS® RS Cup System was 139.86 ± 25.91 min. With $P = 0.037$, there was a statistical significant difference.

The hospitalization in the ‘Stoppa’ group was in average 18.45 ± 5.01 days (d) and postoperative 13.32 ± 4.26 d, whereas in the ‘MUTARS’ group, it was 28.0 ± 9.97 d and 21.43 ± 8.68 d. With $P = 0.015$ for the hospitalization in total and $P = 0.021$ postoperative, there were statistical significant differences. In the ‘Stoppa’ group, there was a difference in hemoglobin levels (g/dL) between date of admission and discharge of -2.26 ± 1.52 g/dL and in the ‘MUTARS’ group of -3.23 ± 1.1 g/dL. There was

Table 1 Comparison of patients between 65 and 79 years. The results of the ‘MUTARS’ and ‘Stoppa’ group are given in mean ± s.d. Statistical significant difference was only noticed in the operation time. Benefits of the ‘Stoppa’ group were documented in every comparison.

	Stoppa	MUTARS	P-values
n	22	7	
Age, years	72.23 ± 4.45	75.29 ± 2.98	0.101
Operation time, minutes	120.82 ± 59.04	139.86 ± 25.91	0.037
Intraoperative complications	0.14 ± 0.35	0	0.6
Postoperative complications			
Total	0.45 ± 0.8	1.29 ± 1.25	0.149
Operative relevance	0.23 ± 0.53	0.57 ± 0.53	0.67
Operative irrelevance	0.18 ± 0.39	0.71 ± 0.76	0.036
Hospitalization, days			
Total	18.45 ± 5.01	28 ± 9.97	0.015
Postoperation	13.32 ± 4.26	21.43 ± 8.68	0.021
Difference in Hb levels (g/dL)	2.26 ± 1.52	3.23 ± 1.1	0.149
Erythrocyte concentrates			
Intraoperation	0.41 ± 1.22	0.57 ± 0.53	0.135
Postoperation	0.32 ± 0.72	2.14 ± 1.35	0.00012
Mobilization	0.77 ± 0.43	0.14 ± 0.38	0.003

no statistical significant difference with $P = 0.149$. In the ‘Stoppa’ group in mean, 0.41 ± 1.22 pieces (pcs.) of erythrocyte concentrate were needed intra-operatively and 0.32 ± 0.72 pcs. postoperatively. In the ‘MUTARS’ group, it was 0.57 ± 0.53 pcs. intraoperatively and 2.14 ± 1.35 pcs. postoperatively. For the intraoperative transfusions, it was $P = 0.135$ and for the postoperative, it was $P = 0.00012$.

The main intra-operative complications were vascular bleedings. In the ‘Stoppa’ group, vascular bleedings were documented in 13.64% ($n = 3$). Origins were the femoral vein in two cases, and the vasa obturatoria in one case. In the ‘MUTARS’ group, no intraoperative complications were documented. With $P = 0.6$, there was no statistical significant difference.

Postoperative complications in both groups were split into subgroups due to the operative treatment (op relevant) or in correlation to the hospitalization

Table 2 Postoperative complications in the 65–79 years group. Op relevant and irrelevant complications comparing all patients ≥ 80.

	Stoppa (n = 22)	MUTARS (n = 7)
OP relevant		
Wound infection	0/22	1/7
Material failure (e.g. dislocation)	0/22	1/7
Hematoma	1/22	1/7
Hypaesthesia/loss of power (ipsilateral leg)	1/22	0/7
Vein thrombosis/pulmonary embolism	3/22	1/7
OP irrelevant		
Hospital-acquired urinary tract infection	2/22	1/7
Hospital-acquired pneumonia	1/22	3/7
Electrolyte derailment	1/22	1/7
Delirious	0/22	0/7
Paralytic Ileus	0/22	0/7
Clostridial infection	0/22	0/7

Group ‘Stoppa’, stabilization with plate fixation via the Stoppa-approach; group ‘MUTARS’, stabilization with THA (MUTARS® RS CUP system).

(op irrelevant). In total in the ‘Stoppa’ group, eight different postoperative complications were documented, and in the ‘MUTARS’ group, nine were documented.

Documented op-relevant complications were wound infections, hematoma, neurological issues (e.g. hypesthesia) or material failure (e.g. luxation of prosthesis) deep vein thrombosis or pulmonary embolism. Op-relevant complications occurred in 22.73% ($n = 5$) in the ‘Stoppa’ group and in the ‘MUTARS’ group, in 57.14% ($n = 4$). Operative revision was needed in case of an infected hematoma in the ‘Stoppa’ group and in cases of one wound infection, one infected hematoma and in case of cup dislocation in the ‘MUTARS’ groups. Unrelated complications were hospital-acquired infections of the urinal tract or pneumonia, electrolyte derailment, delirious, paralytical ileus and clostridial infections. Non-operative complications occurred in 18.18% ($n = 4$) of all cases in the ‘Stoppa’ group and 71.43% ($n = 5$) in the ‘MUTARS’ group. With $P = 0.149$ for the postoperative complications in total and $P = 0.67$ for the op-relevant, there were no statistical significant differences. For the comparison of the non-operative complications, there was a statistical significant difference with $P = 0.036$. The single incidences are given in Table 2.

According to the different postoperative protocols – as described in ‘outcome data’ above – until discharge 72.3% ($n = 16$) in the ‘Stoppa’ group, while in the ‘MUTARS’ group 14.29% ($n = 1$) could be mobilized considering the surgeon’s weight-bearing arrangements and mobilization goals. Due to the good intraoperative reduction result, one could already be mobilized under full weight-bearing. It is a statistical significant difference with $P = 0.003$.

Outcome data of patients aged ≥80

The following results are listed in detail in Table 3.

The mean age of all 31 patients in this group was 86.54 ± 1.33 years – 15 were females and 16 males.

The mean operation duration in all 16 cases of the group using the Stoppa approach and a plate fixation was 108.5 ± 26.01 min and in all 15 cases of the group using the MUTARS® RS Cup System was 138.07 ± 33.72 min. With $P = 0.003$, there was a significant difference.

The hospitalization at all in the ‘Stoppa’ group was on average 24.94 ± 8.58 days and postoperative 17.06 ± 5.89 d, whereas in the ‘MUTARS’ group, it was 21.63 ± 7.74 d and 15.8 ± 7.53 d. With $P = 0.281$ for the hospitalization in total and $P = 0.401$ postoperative, there were no statistical significant differences.

In the ‘Stoppa’ group, there was a difference in hemoglobin levels (g/dL) between date of admission and discharge of -0.47 ± 2.31 and in the ‘MUTARS’ group, -1.39 ± 1.36 . There was no statistical significant difference with $P = 0.129$.

Table 3 Comparison of patients >80 years. The results of the ‘MUTARS’ and ‘Stoppa’ group are given in mean ± s.d. Statistical significant difference was only noticed in the operation time. Benefits of the ‘Stoppa’ group were documented for postoperative complications, blood loss and transfusion of erythrocyte concentrates and in the ‘MUTARS’ group for intraoperative complications, hospitalization and mobilization.

	Stoppa	MUTARS	P-values
n	16	15	
Age, years	84.81 ± 3.23	88.27 ± 4.83	0.122
Operation time, minutes	108.5 ± 26.01	138.07 ± 33.72	0.003
Intraoperative complications	0.13 ± 0.34	0.07 ± 0.26	0.589
Postoperative complications			
Total	0.5 ± 0.73	1.07 ± 0.88	0.055
Operative relevance	0.13 ± 0.34	0.33 ± 0.62	0.3
Operative irrelevance	0.44 ± 0.63	0.73 ± 0.59	0.144
Hospitalization, days			
Total	24.94 ± 8.58	21.53 ± 7.74	0.281
Postoperation	17.06 ± 5.89	15.8 ± 7.53	0.401
Difference in Hb levels (g/dL)	0.47 ± 2.31	1.39 ± 1.36	0.129
Erythrocyte concentrates			
Intraoperation	0.88 ± 1.86	1.13 ± 0.92	0.71
Postoperation	1.19 ± 1.05	2.33 ± 2.06	0.08
Mobilization	0.38 ± 0.5	0.6 ± 0.51	0.218

In the ‘Stoppa’ group in mean, 0.88 ± 1.186 pcs. of erythrocyte concentrate were needed intra-operative and 1.19 ± 1.05 pcs. postoperative. In the ‘MUTARS’ groups, it was 1.13 ± 0.92 pcs. intraoperative and 2.33 ± 2.06 pcs. postoperative. In both comparisons, there were no statistical significant differences.

The main complications in intra-operative in both groups were vascular or diffuse bleedings. In the ‘Stoppa’ group, vascular bleedings in 12.5% ($n=2$) were documented. Origins were the external iliac artery one time and vasa obturatoria one time. In the ‘MUTARS’ group, in only 6.67% ($n=1$) of all cases diffuse bleeding was documented. With $P=0.589$, there was no statistical significant difference.

Operative and irrelevant complications were the same as mentioned above in the comparison of the patients

Table 4 Postoperative complications in the >80 years group. Op relevant and irrelevant complications comparing all patients ≥ 80.

	Stoppa (n = 16)	MUTARS (n = 15)
OP relevant		
Wound infection	0/16	0/15
Material failure (e.g. dislocation)	0/16	4/15
Hematoma	0/16	1/15
Hypaesthesia/loss of power (ipsilateral leg)	0/16	0/15
Vein thrombosis/pulmonary embolism	1/16	0/15
OP irrelevant		
Hospital-acquired urinary tract infection	2/16	4/15
Hospital-acquired pneumonia	2/16	4/15
Electrolyte derailment	1/16	1/15
Delirious	1/16	2/15
Paralytic Ileus	1/16	0/15
Clostridial infection	1/16	0/15

Group ‘Stoppa’, stabilization with plate fixation via the Stoppa-approach; group ‘MUTARS’, stabilization with THA (MUTARS® RS CUP system).

between 65 and 79 years. In total, in the ‘Stoppa’ group, 8 different postoperative complications were documented, whereas, in the ‘MUTARS’ group, it was 16. There was no statistical significant difference with $P=0.055$. In the ‘Stoppa’ group, operative complications (e.g. wound infections, hematoma, thrombosis or material failure) occurred in 6.25 % ($n=1$) and in 33.33 % ($n=5$) in the ‘MUTARS’ group. In all five cases in the ‘MUTARS’ group, an operative revision was necessary. Non-operative complications (e.g. hospital-acquired infections, electrolyte derailment, delirious) occurred in 50.00% in the ‘Stoppa’ group and 73.33% in the ‘MUTARS’ group. There were no statistical significant differences in the single subgroups with $P=0.30$ and $P=0.144$. The single incidences are recorded in [Table 4](#).

Until discharge, 43.75% ($n=7$) in the ‘Stoppa’ group could be mobilized according to the postoperative protocol. Due to the good intraoperative reduction result, one could already be mobilized under full weight-bearing.

In the ‘MUTARS’ group, 60.0% ($n=9$) could be mobilized considering the postoperative protocol. With $P=0.218$, there was no statistical significant difference.

In this group, nine patients (five females and four males) were nonagenarians. The average age was 92.13 ± 2.03 .

Only one patient was treated with a suprapectineal plate osteosynthesis via the Stoppa approach, whereas in the other eight, a THA with a MUTARS prosthesis was performed. In none of these nine cases, intraoperative complications were noted but seven of nine cases had postoperative complications. In every case, intra- and postoperative transfusions of erythrocyte concentrations were needed and five patients were able to walk with the help of walkers before discharge. The total hospitalization time was between 11 and 29 days. A statistical analysis was not possible due to the uneven group sizes – an overview about mean and s.d. in the ‘MUTARS’ group is given in [Table 5](#).

Indications based on X-ray analyses

Retrospectively, we reviewed 72 X-rays of the initial acetabular fractures postinjury of all 89 patients where only 17 patients had CT scans before operation.

Depending on the fracture severity and the main fracture parts, we discriminated six different groups: simple acetabular fractures (mainly the anterior column was affected), complex fractures (combined fractures of anterior and posterior column, severe arthrosis, multiple fracture fragments), complex fractures with a severe affection of the anterior pelvic ring, fractures focused on a defect of the quadrilateral surface, periprosthetic fractures with dual head prosthesis and others (two special cases when we found a completely destructed femoral head and a dislocated cup of a THA). An overview of the

different fracture types on which operative treatment was performed is given in Table 6.

Only looking at the X-rays, we deduced that there is a clear tendency to choose the plate fixation via the Stoppa approach when there is a simple acetabular fracture.

In all complex fractures, already inserted dual-head prosthesis and in the above-described special cases, a MUTARS® RS Cup prosthesis was indicated both initially and during our analysis.

There is no clear comprehensive explanation for choosing a certain operative treatment in the groups of complex fractures with or without anterior pelvic ring affection.

In cases of fractures of the quadrilateral surface, there is a tendency to treat those types of fractures with a plate-fixation. Examples for every group are given in Figs 3, 4, 5, 6, 7, 8, 9 and 10.

Discussion

Resulting from this retrospective study, the open reduction and internal fixation via the Stoppa approach have favorable outcomes compared to THA with a MUTAR® RS Cup System.

Comparing the ORIF via the modified Stoppa approach and the MUTARS® RS CUP System in this study, there were statistically significant shorter operation times in the Stoppa groups for all patients.

In the 65–79 years group, the Stoppa osteosynthesis was superior in every comparison. In line with this, in the comparison of patients ≥ 80 years in the ‘Stoppa’ group, less postoperative complications were documented for example, hospital-acquired infections when using the ORIF in this study. Wound infections, blood loss or the need for blood transfusions were documented as too less in our study compared to the Mutars-THA patients. No material

Table 5 Comparison of all patients >90 years. In the ‘Stoppa’ group, only one patient was older than 90 years; here, the individual results are listed. The results of the ‘MUTARS’ group are given as mean ± s.d. A statistical comparison was not possible due to missing of few patients in the ‘Stoppa’ group.

	Stoppa	MUTARS
n	1	8
Age, years	92	92.13 ± 2.03
Operation time, minutes	84	128.88 ± 31.32
Intraoperative complications	0	0
Postoperative complications		
Total	1	1.25 ± 1.04
Operative relevance	0	0.38 ± 0.52
Operative irrelevance	1	0.88 ± 0.64
Hospitalization, days		
Total	29	19.75 ± 5.5
Postoperation	22	14 ± 5.95
Difference in Hb levels (g/dL)	0.7	1.6 ± 0.86
Erythrocyte concentrates		
Intraoperation	3	1.38 ± 0.74
Postoperation	3	2.5 ± 1.6
Mobilization	0	0.75 ± 0.46

issues were documented during the postoperative stay in hospital. However, there were some severe complications after the use of MUTARS® RS CUP prosthesis in, particularly, hip dislocations. There are rare indications for the use of a THA in acetabular fractures. On the other hand, in this group, some positives were documented for the ‘MUTARS’ group: intraoperative complications were less, the hospitalization was shorter and mobilization could be performed more successfully.

Those results can be partially transferred to nonagenarians. Above all, the greatest benefit of the ‘MUTARS’ groups for patients older than 80 years is the easier and faster mobilization due to the possibility of postoperative full weight-bearing.

Based on the X-ray analysis, there are no precise characterizations for choosing one or the other operative treatment. Apart from complex fractures of the quadrilateral surface, affections of the femoral head or periprosthetic acetabular fractures with residual instability, a plate fixation appears to be a sufficient operative treatment for primary stabilization of acetabular fractures.

Nevertheless, it is important not only to decide on an operative method depending on the radiological diagnostic report but also give consideration to the patients’ personal circumstances (age, weight, mobility, etc.).

Considerations and conclusion

Fracture classification

Nowadays, the indications for an operative or non-operative treatment of acetabular fractures are not completely clear, since, to date, there is no evidence-based guideline for acetabular fractures and the surgical treatment in the literature. Based on retrospective and follow-up studies, complications and functional outcomes have been compared. Indeed, there have been good results for non-operatively treated acetabular fractures, but due to the complexity of these fractures, operation is often necessary (27, 44).

Fracture classifications have been established for acetabular fractures during the past decades, but treatment guidelines resulting from the fracture patterns are still missing. There have been trials for developing classification systems that can help to choose between the different operation methods. For example, Tannast *et al.* tried to create a nomogram predicting the necessity of THA 2 years after primary operative stabilization after trauma based on the fracture pattern, its morphology and the patient’s age for the indication (45). In their conclusion, Audretsch *et al.* tried to figure out negative prognostic values such as the female gender or older age for the critical evaluation of choosing a THA as treatment option in acetabular fractures (13). Moreover, Capone

Table 6 Characterizations result of the X-ray analyses of 72 patients between 18 and 96 years old and the numbers of operative treatments performed.

	Total	Stoppa PLO	MUTARS THA
Simple fracture of the anterior column	22	22	0
Complex fractures	14	3	11
Additional fracture of the anterior pelvic ring	11	9	2
Fracture of the quadrilateral surface	19	18	1
Acetabular fracture with dual head prosthesis	4	0	4
Others	2	0	2

MUTARS THA, Total Hip Arthroplasty with MUTARS® RS CUP system; Stoppa PLO, plate osteosynthesis via the Stoppa approach. In the groups ‘simple fractures of the anterior column’, ‘additional fracture of the anterior pelvic ring’ and ‘others’, the performed and guessed treatments correspond. In the other groups, there were deviations from guessing and performing.

et al. declared osteoporosis and complex fracture patterns as negative prognostic values (14).

Role of Stoppa approach and osteosynthesis

An ORIF via the modified Stoppa approach is, in the author’s experience, a viable and regularly used method for treating complex acetabular fractures. In recent trends, it is performed more often than osteosynthesis via the common ilioinguinal approach, as it provides a better intraoperative view and is less associated with complications (28, 46). We could show that one of the most frequent intraoperative complications of this method is blood loss based on vascular bleedings. The careful surgical preparation therefore is most important due to the anatomical vicinity of greater blood vessels. Additionally, a complication with a high frequency is an affection of the obturator nerve. This complication which is a definite result of the surgical method was not documented in our data. Based on the current literature, they are however very rare (28, 31, 46, 47). This method has many benefits especially for patients younger than 80 years as described above. Nevertheless, an often discussed long-term complication is the posttraumatic osteoarthritis and need for secondary

THA. Depending on different sources, the revision rate of implanting a hip endoprosthesis is 10–30% (5, 22, 48).

Role of THA

THA is an often performed treatment option for patients with acetabular fractures.

For the ideal stabilization, additional internal fracture fixations are needed if using regular THAs. On the one hand, there are stabilization options such as a Burch–Schneider ring (35, 39, 49) or further developed reinforcement rings such as the MUTARS® RS Cup system or the trabecular metal revision shell (cup-cage construct) (37, 38); those are very new and prospective studies have been not yet been performed. On the other hand, additional plate fixations via further approaches are used for better reduction results. Depending on the kind of pattern beside common ORIF via the Stoppa or the ilioinguinal approach in case of affection of the posterior column plate fixation via a Kocher–Langenbeck approach can give a better stabilization (5).

A huge benefit of THA is the possibility of mobilization with full weight-bearing after the surgical intervention, which is a big advantage especially for the elderly patient.

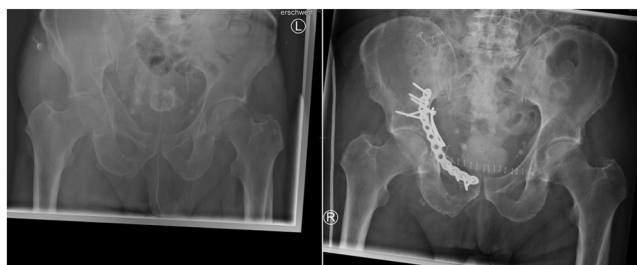

Figure 4 Simple acetabular fracture of the anterior column on the right side pre- and post-operative. For stabilization, a suprapectineal plate fixation (Fa. Stryker) was used: 69 years old male patient suffering from an acetabular fracture caused by falling from a bicycle. In the X-ray, one can see a fracture of the anterior column. In the additional CT scans, there is further affection of the quadrilateral surface without major dislocations. Intraoperatively, suprapectineal plate fixation with a plate by Stryker was chosen. Postoperatively, the patient could be mobilized on crutches under 20% partial weight-bearing.

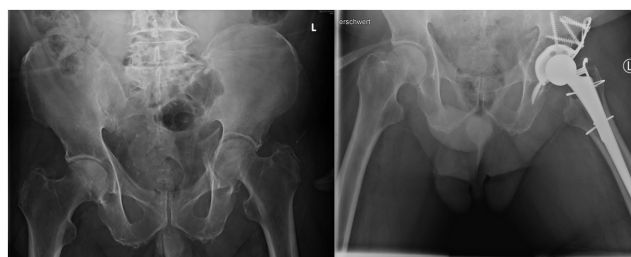


Figure 5 Complex acetabular fracture pre- and post-operative. For stabilization, a THA with MUTARS® RS CUP system was used: this fracture with affection of the major trochanter of a 76 years old male patient based on an epileptic seizure. In the CT scans and intraoperatively, there was a problem of multiple dislocated fracture fragments of the acetabular bottom. After an acetabular bottom plastic, an MUTARS® RS CUP and a CLS® stem were inserted. After the operation, mobilization was only allowed by partial weight-bearing on the left side which was not possible to realize for the patient.

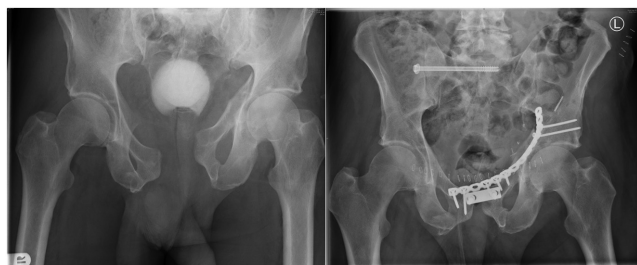

Figure 6

Complex acetabular fracture with affection of the anterior pelvic ring and cross-over posterior pelvic ring fracture pre- and post-operative. For stabilization, a sacral screw, a dual-, and a 14-hole-reconstructive plate by Synthes were necessary: after a pelvic contusion during woodcutting, this male 59 years old patient was suffering from a severe acetabular fracture with great separation of the pubic symphysis and a fracture of the right sacral bone. Furthermore, there was a rupture in the urethra. Primary fracture was stabilized by an external pelvic fixator and a suprapubic catheter was inserted. In the second operation, the external fixator was removed and the single fractures finally stabilized by a sacral screw, a dual-, and a 14-hole-reconstructive plate by Synthes. Before the patient was discharged, he was already able to walk by partial weight-bearing on a walker. The urethra was afterwards reconstructed.

Comparing the patients older than 79 years in our study, they were more easily mobilized with THA. This could be a reason for the shorter hospitalization in this group as we can see in our results and the results in the present literature (35, 49).

Currently, there are not much data about the mobilization and weight-bearing after internal fixation with plates in patients with acetabular fractures directly after operation. Our results demonstrate that in the comparison of patients between 65 and 79 years – probably based on the younger average age – patients with an internal

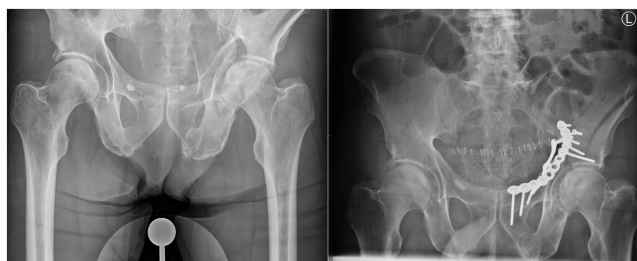

Figure 7

Complex acetabular fracture with impaction in the quadrilateral surface pre- and post-operatively. For stabilization, a THA with MUTARS® RS CUP system was used: after a bicycle accident, this 63 years old male was suffering from an acetabular fracture with affection of the left iliac wing. In addition to CT scans and intraoperation, a complex fracture of the quadrilateral surface with protrusion of the femoral head was determined. After reduction, the fracture was stabilized by a suprapectineal plate by Stryker. Postoperatively, the patient was mobilized on the rollator under partial weight-bearing.

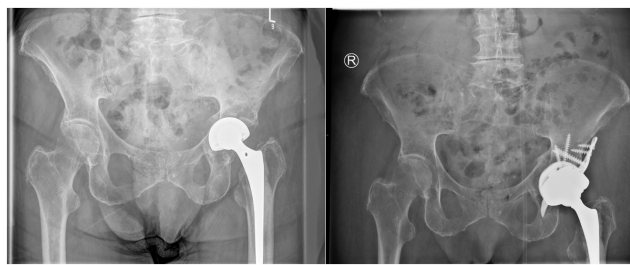

Figure 8

Acetabular fracture with dual-head prosthesis pre- and post-operatively. For stabilization, a THA with MUTARS® RS CUP was used: this acetabular fracture and protrusion of the dual-head prosthesis were caused by a fall of a 90 years old female. This fracture was treated by MUTARS® RS CUP and change of the prosthesis' head (Implacross EcoFit2M). A not dislocated fracture of the anterior pelvic ring did not have to be stabilized. Before returning to nursing home, the patient was able to walk under full body-bearing on the left.

fixation had less problems with mobilization with partial weight-bearing. Therefore, a larger proportion was able to meet the postoperative requirements, set by the surgeon. In contrast to those patients, 80 years and older showed better mobilization results when treated by THA. This matches with the results of further performed studies (5).

However, a common postoperative complication as we could see on our research is a dislocation of the prosthesis. Morison *et al.* even showed that those complications are more likely when THA is performed in patients with an acetabular fracture compared to the control group (50).

Role of stability of pelvic ring and acetabulum for THA

Regarding to all 72 X-rays without any further radiological investigation, it was not possible to identify the single

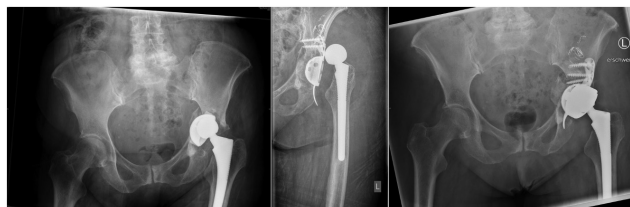

Figure 9

An 84 year old female with acetabular fracture and dislocated cup of a total endoprosthesis after fall on the left hip. Due to the dislocated cup of the endoprosthesis only stabilization of the acetabular fracture by a MUTARS prosthesis was possible. After an acetabular roof plastic with allogeneic bone material was performed, a MUTARS® RS CUP was inserted and the femoral head prosthesis was changed. Due to a diffuse bleeding from the left external iliacal artery, a coil embolization was necessary. Ten days after the first operation, the prosthesis was dislocated (second picture) and revision with exchange of the cup into a tripolar was performed (third picture). The patient walked under full body-bearing on the left side on the rollator afterwards again.

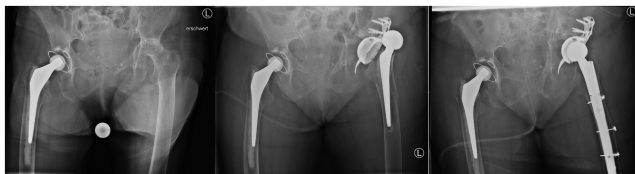

Figure 10

Complex acetabular fracture with severe necrosis of the left femoral head of a 93-year old female. After implantation of a MUTARS® RS CUP and a cemented stem, there was a dislocation of the prosthesis 5 days after the operation (second picture). In a revision operation, a partial explantation and implantation of a Revitan stem were performed (third picture). The patient was suffering from a hospital-acquired pneumonia and urogenital infection and could only be mobilized into standing after revision.

fracture patterns differing from the Letournel classification. This is the reason why we built different groups.

When analyzing the post traumatic X-rays, we realized a tendency to treat acetabular fractures – not regarding the patient's age or circumstances – for primary ORIF when a good fracture reduction seemed to be possible. Further exceptions were severe bone degenerations. As those fractures are often combined with anterior pelvic fractures, it appears that the use of a THA is not feasible because of a difficult cup implantation. Especially for the elderly population, these results have been found in studies by Carroll *et al.* and Matta *et al.* For the primary stability of acetabular fractures, a plate fixation seems to be better even if an insufficient fracture reduction causes arthrosis and leads to a later need for THA (51, 52).

Capone *et al.* performed a systematic review comparing the results of ORIF and THA in patients in mean older than 70 years old with acetabular fractures. They found out that patients treated with ORIF had a higher mortality rate 1 year after operation, and in this group, revisions were more often needed (14). In general, several authors came to the conclusion that THA is a better treatment option than ORIF due to shorter operation times (this is not matching with our results), easier mobilization postoperative and less revisions. For a long time, combinations of ORIF and THA were needed for optimizing reduction results and the best possible stabilization of the acetabular surface. Nowadays, a plate fixation and, in this context, needed additional approaches are not necessary anymore because of further developed reinforcement rings such as the MUTARS RS Cup system or the trabecular metal revision shell (cup-cage construct) (37, 38).

Considerations for the treatment of acetabular fractures in the elderly and nonagenarians

Finding a homogenous treatment for different patterns of acetabular fractures in elderly and nonagenarians is very complicated and complex. Due to the demographic

change, the population worldwide is aging and how to handle geriatric fractures becomes a more important question. Considering acetabular fractures, many authors tried to define radiographic guidelines or predictive criteria for choosing the correct therapy concept. There have been different reports of bad prognostic factors (female gender, osteoporosis, higher age, complex fracture patterns) when choosing an operative treatment (13, 14). But due to the fact that in the elderly and nonagenarian population comorbidities, resiliencies and lifestyles differ immensely and the life expectation is not calculatable; all authors concluded that an individual decision-making is most important (7, 53).

The indications for a conservative therapy are very rare due to higher mortality rates compared to operative treatment options (12, 27).

In our study the over 80 years old patients could profit from shorter operations times and postoperative complications with postoperative necessary revision operations due to material failures in the Stoppa groups. However, contrary to this, revisions might be necessary later when using a PLO because of the common complication of postoperative osteoarthrosis (22).

Nevertheless, in cases of acetabular fracture, we recommend an ORIF via the modified Stoppa approach whenever possible, especially for patients between 65 and 79 years old.

This study has several limitations. First, this is a retrospective and monocentric design. However, because complex acetabular fractures are not very frequent compared to other fracture types and THA is not common in many cases, the group sizes are unequal in the comparison of patients with 65–79 years. Since the use of the MUTARS® RS CUP system in acetabular fractures as primary fracture treatment is new, no comparable literature could be found.

Also, of concern is the potential observer bias.

Based on the current literature, this is the first study comparing the ORIF via the Stoppa approach with THA using the MUTARS® RS CUP system for stabilizing acetabular fractures.

Further studies with a larger number of cases observed over a longer period of time as well as controlled, prospective interventional studies comparing ORIF with MUTARS® RS CUP and THA are necessary in the future.

For a better comparison of these two operative methods, further studies are needed for clarification of the disadvantages of long-term complications and economic advantages.

ICMJE Conflict of Interest Statement

The authors declare that there is no have conflict of interest that could be perceived as prejudicing the impartiality of this study.

Funding Statement

This work did not receive any specific grant from any funding agency in the public, commercial, or not-for-profit sector.

Ethics approval

The study had the approval of the local ethics committee (Frankfurt am Main, approval 01/2022).

Author contribution statement

All authors contributed equally to this work.

References

1. Gary JL, Paryavi E, Gibbons SD, Weaver MJ, Morgan JH, Ryan SP, Starr AJ & O’Toole RV. Effect of surgical treatment on mortality after acetabular fracture in the elderly: a multicenter study of 454 patients. *Journal of Orthopaedic Trauma* 2015 **29** 202–208. (<https://doi.org/10.1097/BOT.0000000000000223>)

2. Ochs BG, Marintschev I, Hoyer H, Rolauffs B, Culemann U, Pohlemann T & Stuby FM. Changes in the treatment of acetabular fractures over 15 years: analysis of 1266 cases treated by the German Pelvic Multicentre Study Group (DAO/DGU). *Injury* 2010 **41** 839–851. (<https://doi.org/10.1016/j.injury.2010.04.010>)

3. Laflamme GY, Hebert-Davies J, Rouleau D, Benoit B & Leduc S. Internal fixation of osteopenic acetabular fractures involving the quadrilateral plate. *Injury* 2011 **42** 1130–1134. (<https://doi.org/10.1016/j.injury.2010.11.060>)

4. Anglen JO, Burd TA, Hendricks KJ & Harrison P. The ‘gull sign’. A Harbinger of failure for internal fixation of geriatric acetabular fractures. *Journal of Orthopaedic Trauma* 2003 **17** 625–634. (<https://doi.org/10.1097/00005131-200310000-00005>)

5. Lont T, Nieminen J, Reito A, Pakarinen TK, Pajamäki I, Eskelinen A & Laitinen MK. Total hip arthroplasty, combined with a reinforcement ring and posterior column plating for acetabular fractures in elderly patients: good outcome in 34 patients. *Acta Orthopaedica* 2019 **90** 275–280. (<https://doi.org/10.1080/17453674.2019.1597325>)

6. Delsmann MM, Schmidt C, Mühlenfeld M, Jandl NM, Boese CK, Beil FT, Rolvien T & Ries C. Prevalence of osteoporosis and osteopenia in elderly patients scheduled for total knee arthroplasty. *Archives of Orthopaedic and Trauma Surgery* 2021. (<https://doi.org/10.1007/s00402-021-04297-x>)

7. Firoozabadi R, Cross WW, Krieg JC & Rutt MLC. Acetabular fractures in the senior population—epidemiology, mortality and treatments. *Archives of Bone and Joint Surgery* 2017 **5** 96–102. (<https://doi.org/10.22038/abjs.2016.7933>)

8. Delsmann MM, Strahl A, Mühlenfeld M, Jandl NM, Beil FT, Ries C & Rolvien T. High prevalence and undertreatment of osteoporosis in elderly patients undergoing total hip arthroplasty. *Osteoporosis International* 2021 **32** 1661–1668. (<https://doi.org/10.1007/s00198-021-05881-y>)

9. Codesido P, Mejía A, Riego J & Ojeda-Thies C. Subtrochanteric fractures in elderly people treated with intramedullary fixation: quality of life and complications following open reduction and cerclage wiring versus closed reduction. *Archives of Orthopaedic and Trauma Surgery* 2017 **137** 1077–1085. (<https://doi.org/10.1007/s00402-017-2722-y>)

10. Johnell O & Kanis J. Epidemiology of osteoporotic fractures. *Osteoporosis International* 2005 **16** (Supplement 2) S3–S7. (<https://doi.org/10.1007/s00198-004-1702-6>)

11. Roberts KC & Brox WT. From evidence to application: AAOS clinical practice guideline on management of hip fractures in the elderly. *Journal of Orthopaedic Trauma* 2015 **29** 119–120. (<https://doi.org/10.1097/BOT.0000000000000272>)

12. Mohan K, Broderick JM, Raza H, O’Daly B & Leonard M. Acetabular fractures in the elderly: modern challenges and the role of conservative management. *Irish Journal of Medical Science* 2021 In Press. (<https://doi.org/10.1007/s11845-021-02711-2>)

13. Audretsch C, Trulson A, Höch A, Herath SC, Histing T & Küper MA. Evaluation of decision-making in the treatment of acetabular fractures. *EFORT Open Reviews* 2022 **7** 84–94. (<https://doi.org/10.1530/EOR-20-0149>)

14. Capone A, Peri M & Mastio M. Surgical treatment of acetabular fractures in the elderly: a systematic review of the results. *EFORT Open Reviews* 2017 **2** 97–103. (<https://doi.org/10.1302/2058-5241.2.160036>)

15. Rommens PM & Hofmann A. Comprehensive classification of fragility fractures of the pelvic ring: recommendations for surgical treatment. *Injury* 2013 **44** 1733–1744. (<https://doi.org/10.1016/j.injury.2013.06.023>)

16. Letournel E. Acetabulum fractures: classification and management. *Clinical Orthopaedics and Related Research* 1980 **151** 81–106. (<https://doi.org/10.1097/00003086-198009000-00012>)

17. Meinberg EG, Agel J, Roberts CS, Karam MD & Kellam JF. Fracture and dislocation classification compendium – 2018. *Journal of Orthopaedic Trauma* 2018 **32** (Supplement 1) S1–S170. (<https://doi.org/10.1097/BOT.0000000000001063>)

18. Wollmerstädt J, Pieroh P, Schneider I, Zeidler S, Höch A, Josten C & Osterhoff G. Mortality, complications and long-term functional outcome in elderly patients with fragility fractures of the acetabulum. *BMC Geriatrics* 2020 **20** 66. (<https://doi.org/10.1186/s12877-020-1471-x>)

19. Wu H, Shao Q, Shang R, Song C, Liu X & Cai X. Open reduction and internal fixation of quadrilateral plate fractures in the elderly: association between initial fracture pattern and outcomes. *BMC Musculoskeletal Disorders* 2021 **22** 122. (<https://doi.org/10.1186/s12891-021-04002-4>)

20. Pohlemann T, Herath SC, Braun BJ, Rollmann MF, Histing T & Pizanis A. Anterior approaches to the acetabulum: which one to choose? *EFORT Open Reviews* 2020 **5** 707–712. (<https://doi.org/10.1302/2058-5241.5.190061>)

21. Ferguson TA, Patel R, Bhandari M & Matta JM. Fractures of the acetabulum in patients aged 60 years and older: an epidemiological and radiological study. *Journal of Bone and Joint Surgery: Series B* 2010 **92** 250–257. (<https://doi.org/10.1302/0301-620X.92B2.22488>)

22. Vipulendran K, Kelly J, Rickman M & Chesser T. Current concepts: managing acetabular fractures in the elderly population. *European Journal of Orthopaedic Surgery and Traumatology* 2021 **31** 807–816. (<https://doi.org/10.1007/s00590-021-02931-3>)

23. Soni A, Gupta R & Sen R. Acetabulum fractures in elderly patients: a review. *Chinese Journal of Traumatology* 2021 In Press. (<https://doi.org/10.1016/j.cjtee.2021.12.004>)

24. Wilke H-J, Schmidt H & Kienle A. Biomechanische forschung – von der testung zur klinischen anwendung. *Trauma und Berufskrankheit* 2013 **15** 249–258. (<https://doi.org/10.1007/s10039-013-2044-4>)

25. Daurka JS, Pastides PS, Lewis A, Rickman M & Bircher MD. Acetabular fractures in patients aged > 55 years: a systematic review of the literature. *Bone and Joint Journal* 2014 **96-B** 157–163. (<https://doi.org/10.1302/0301-620X.96B2.32979>)

26. McCormick BP, Serino J, Orman S, Webb AR, Wang DX, Mohamadi A, Mortensen S, Weaver MJ & Von Keudell A. Treatment modalities and outcomes following acetabular fractures in the elderly: a systematic review. *European Journal of Orthopaedic Surgery and Traumatology* 2021. (<https://doi.org/10.1007/s00590-021-03002-3>)

- 27. Boudissa M, Francony F, Drevet S, Kerschbaumer G, Ruatti S, Milaire M, Merloz P & Tonetti J.** Operative versus non-operative treatment of displaced acetabular fractures in elderly patients. *Aging Clinical and Experimental Research* 2020 **32** 571–577. (<https://doi.org/10.1007/s40520-019-01231-5>)
- 28. Chesser TJS, Eardley W, Mattin A, Lindh AM, Acharya M & Ward AJ.** The modified ilioinguinal and anterior intrapelvic approaches for acetabular fracture fixation: indications, quality of reduction, and early outcome. *Journal of Orthopaedic Trauma* 2015 **29** (Supplement 2) S25–S28. (<https://doi.org/10.1097/BOT.0000000000000268>)
- 29. Marzi I.** Focus on non-union of fractures. *European Journal of Trauma and Emergency Surgery* 2019 **45** (Supplement1) 1–2. (<https://doi.org/10.1007/s00068-019-01079-4>)
- 30. Keel MJB, Siebenrock KA, Tannast M & Bastian JD.** The pararectus approach a new concept. *JBJS Essential Surgical Techniques* 2018 **8** e21. (<https://doi.org/10.2106/JBJS.ST.17.00060>)
- 31. Tannast M, Keel MJB, Siebenrock KA & Bastian JD.** Open reduction and internal fixation of acetabular fractures using the modified Stoppa approach. *JBJS Essential Surgical Techniques* 2019 **9** e3. (<https://doi.org/10.2106/JBJS.ST.18.00034>)
- 32. Kelly J, Ladurner A & Rickman M.** Surgical management of acetabular fractures – a contemporary literature review. *Injury* 2020 **51** 2267–2277. (<https://doi.org/10.1016/j.injury.2020.06.016>)
- 33. Antell NB, Switzer JA & Schmidt AH.** Management of acetabular fractures in the elderly. *Journal of the American Academy of Orthopaedic Surgeons* 2017 **25** 577–585. (<https://doi.org/10.5435/JAAOS-D-15-00510>)
- 34. Meermans G, Konan S, Das R, Volpin A & Haddad FS.** The direct anterior approach in total hip arthroplasty a systematic review of the literature. *Bone and Joint Journal* 2017 **99-B** 732–740. (<https://doi.org/10.1302/0301-620X.99B6.38053>)
- 35. Butterwick D, Papp S, Gofton W, Liew A & Beaulé PE.** Acetabular fractures in the elderly evaluation and management. *Journal of Bone and Joint Surgery: American Volume* 2015 **97** 758–768. (<https://doi.org/10.2106/JBJS.N.01037>)
- 36. Tidermark J, Blomfeldt R, Ponzer S, Söderqvist A & Törnkvist H.** Primary total hip arthroplasty with a Burch-Schneider antiprotrusion cage and autologous bone grafting for acetabular fractures in elderly patients. *Journal of Orthopaedic Trauma* 2003 **17** 193–197. (<https://doi.org/10.1097/00005131-200303000-00007>)
- 37. Malhotra R & Gautam D.** Cup-cage construct using porous cup with Burch-Schneider cage in the management of complex acetabular fractures. *Hip Pelvis* 2019 **31** 87–94. (<https://doi.org/10.5371/hp.2019.31.2.87>)
- 38. Janko M, Verboket R, Genari M, Frank J, Marzi I.** Primary or revision arthroplasty with an integrated acetabular cup – MUTARS® RS Cup system. *European Journal of Trauma and Emergency Surgery* 2022 In Press. (<https://doi.org/10.1007/s00068-022-01956-5>)
- 39. Liaw F, Govilkar S, Banks D, Kankanalu P, Youssef B & Lim J.** Primary total hip replacement using Burch-Schneider cages for acetabular fractures. *Hip International* 2020 In press. (<https://doi.org/10.1177/1120700020957642>)
- 40. Enocson A & Blomfeldt R.** Acetabular fractures in the elderly treated with a primary burch-schneider reinforcement ring, autologous bone graft, and a total hip arthroplasty: a prospective study with a 4-year follow-up. *Journal of Orthopaedic Trauma* 2014 **28** 330–337. (<https://doi.org/10.1097/BOT.0000000000000016>)
- 41. Regis D, Sandri A & Bonetti I.** Acetabular reconstruction with the Burch-Schneider antiprotrusion cage and bulk allografts: minimum 10-year follow-up results. *BioMed Research International* 2014 **2014** 194076. (<https://doi.org/10.1155/2014/194076>)
- 42. Marongiu G, Podda D, Mastio M & Capone A.** Long-term results of isolated acetabular revisions with reinforcement rings: a 10- to 15-year follow-up. *Hip International* 2019 **29** 385–392. (<https://doi.org/10.1177/1120700018802750>)
- 43. Vandembroucke JP, Von Elm E, Altman DG, Gøtzsche PC, Mulrow CD & Pocock SJ.** Strengthening the reporting of observational studies in epidemiology (STROBE): explanation and elaboration. *Epidemiology* 2007 **18** 805–835. (<https://doi.org/10.1097/EDE.0b013e3181577511>)
- 44. Ryan SP, Manson TT, Sciadini MF, Nascone JW, LeBrun CT, Castillo RC, Muppavarapu R, Schurko B & O'Toole RV.** Functional outcomes of elderly patients with nonoperatively treated acetabular fractures that meet operative criteria. *Journal of Orthopaedic Trauma* 2017 **31** 644–649. (<https://doi.org/10.1097/BOT.0000000000000990>)
- 45. Tannast M, Najibi S & Matta JM.** Two to twenty-year survivorship of the hip in 810 patients with operatively treated acetabular fractures. *Journal of Bone and Joint Surgery: Series A* 2012 **94** 1559–1567. (<https://doi.org/10.2106/JBJS.K.00444>)
- 46. Singh SV, Chopra RK, Puri G, Pheroz M, Kumar S, Bansal A, Gupta S, Sodhi S & Samanta P.** Clinico-radiological evaluation of modified Stoppa approach in treatment of acetabulum fractures. *Cureus* 2020 **12** e10193. (<https://doi.org/10.7759/cureus.10193>)
- 47. Isaacson MJ, Taylor BC, French BG & Poka A.** Treatment of acetabulum fractures through the modified Stoppa approach: strategies and outcomes. *Clinical Orthopaedics and Related Research* 2014 **472** 3345–3352. (<https://doi.org/10.1007/s11999-014-3460-x>)
- 48. Tannast M, Najibi S & Matta JM.** Two to twenty-year survivorship of the hip in 810 patients with operatively treated acetabular fractures. *Journal of Bone and Joint Surgery* 2013 **94** 1559–1567.
- 49. Rickman M, Young J, Trompeter A, Pearce R & Hamilton M.** Managing acetabular fractures in the elderly with fixation and primary arthroplasty: aiming for early weightbearing. *Clinical Orthopaedics and Related Research* 2014 **472** 3375–3382. (<https://doi.org/10.1007/s11999-014-3467-3>)
- 50. Morison Z, Moojen DJF, Nauth A, Hall J, McKee MD, Waddell JP & Schemitsch EH.** Total hip arthroplasty after acetabular fracture is associated with lower survivorship and more complications. *Clinical Orthopaedics and Related Research* 2016 **474** 392–398. (<https://doi.org/10.1007/s11999-015-4509-1>)
- 51. Carroll EA, Huber FG, Goldman AT, Virkoo WW, Pagenkopf E, Lorich DG & Helfet DL.** Treatment of acetabular fractures in an older population. *Journal of Orthopaedic Trauma* 2010 **24** 637–644. (<https://doi.org/10.1097/BOT.0b013e3181ceb685>)
- 52. Matta JM.** Fractures of the acetabulum: accuracy of reduction and clinical results in patients managed operatively within three weeks after the injury. *Journal of Bone and Joint Surgery: Series A* 1996 **78** 1632–1645. (<https://doi.org/10.2106/00004623-199611000-00002>)
- 53. de Groot R, Nijmeijer WS, Folbert EC, Vollenbroek-Hutten MMR & Hegeman JH.** 'Nonagenarians' with a hip fracture: is a different orthogeriatric treatment strategy necessary? *Archives of Osteoporosis* 2020 **15** 19. (<https://doi.org/10.1007/s11657-020-0698-7>)