

Aus dem
CardioVasculären Centrum Sankt Katharinen
Frankfurt am Main
(Leiter: Prof. Dr. med. Horst Sievert)

**The Safety and Performance of the New Nitinol Stent in the Treatment
of Carotid Artery Stenosis - One and Six Month Follow-up**

Dissertation zur Erlangung des Doktorgrades der Medizin
des Fachbereichs Medizin der
Johann Wolfgang Goethe-Universität Frankfurt am Main

vorgelegt von
Jennifer Franke
aus Los Gatos, USA

Frankfurt am Main, 2007

Dekan: Prof. Dr. J. Pfeilschifter
Referent: Prof. Dr. H. Sievert
Koreferent: Prof. Dr. F. Zanella
Tag der mündlichen Prüfung: 16.02.2009

TABLE OF CONTENTS

1	ZUSAMMENFASSUNG	- 5 -
2	ABSTRACT.....	- 7 -
3	INTRODUCTION	- 8 -
3.1	NATURAL HISTORY OF CAROTID DISEASE.....	- 8 -
3.2	MORPHOLOGY AND PATHOPHYSIOLOGY	- 8 -
3.3	NEUROVASCULAR ANATOMY	- 10 -
3.4	HISTORICAL PERSPECTIVE OF CAROTID ENDARTERECTOMY (CEA).....	- 11 -
3.5	POTENTIAL COMPLICATIONS OF CAROTID ENDARTERECTOMY.....	- 12 -
3.6	HISTORICAL PERSPECTIVE OF CAROTID STENTING.....	- 12 -
3.7	POTENTIAL BENEFITS OF CAROTID STENTING	- 13 -
3.8	EMBOLIC PROTECTION DEVICES	- 13 -
3.8.1	<i>Types of Embolic Protection Devices.....</i>	<i>- 13 -</i>
3.8.1.1	Distal Occlusion Balloons.....	- 13 -
3.8.1.2	Filter Devices.....	- 14 -
3.8.1.3	Distal Occlusion Balloons.....	- 15 -
3.9	THE PROCAR TRIAL: PROTÉGÉ STENT IN THE TREATMENT OF CAROTID ARTERY STENOSIS WITH ADJUNCTIVE USE OF A FILTER EMBOLIC PROTECTION DEVICE	- 15 -
4	METHODS	- 17 -
4.1	STUDY DESIGN AND OBJECTIVES.....	- 17 -
4.2	STUDY REQUIREMENTS.....	- 18 -
4.3	OUTCOME ANALYSIS.....	- 22 -
4.4	PROCEDURE MANAGEMENT.....	- 23 -
4.5	POST-PROCEDURE MANAGEMENT.....	- 25 -
4.6	DESCRIPTION OF STENT.....	- 26 -
4.7	DESCRIPTION OF FILTERS USED IN THE TRIAL.....	- 30 -
5	RESULTS	- 33 -
5.1	PATIENT CHARACTERISTICS.....	- 33 -
5.2	TECHNICAL SUCCESS	- 36 -
5.3	PATIENT OUTCOMES AT ONE MONTH.....	- 37 -

5.4	PATIENT OUTCOMES AT SIX MONTHS.....	- 38 -
6	DISCUSSION.....	- 40 -
6.1	SURGICAL TRIALS	- 40 -
6.2	CLINICAL SERIES OF CAROTID STENTING	- 41 -
6.3	- 43 -RANDOMIZED TRIALS	- 43 -
6.4	CLINICAL TRIALS WITH USE OF THE PROTÉGÉ STENT.....	- 45 -
7	CONCLUSION.....	- 47 -
8	REFERENCES	- 48 -
9	GLOSSAR	- 55 -
10	ATTACHMENTS.....	- 56 -
10.1	ACKNOWLEDGEMENTS.....	- 56 -
10.2	SCIENTIFIC ACHIEVEMENTS	- 57 -
10.2.1	<i>Publications</i>	- 57 -
10.2.2	<i>Book Chapters</i>	- 58 -
10.2.3	<i>Awards/ Nominations</i>	- 59 -
10.2.4	<i>Invited Lectures</i>	- 60 -
10.2.5	<i>Scientific Presentations</i>	- 62 -
11	CURRICULUM VITAE.....	- 68 -
12	EHRENWÖRTLICHE ERKLÄRUNG.....	- 71 -

TABLE OF FIGURES

Figure 1: Stroke Classification - 17 -

Figure 2: Inclusion Criteria..... - 19 -

Figure 3: Exclusion Criteria..... - 20 -

Figure 4: Overall Study Design - 21 -

Figure 5: Protégé GPS Stent - Straight Version - 28 -

Figure 6: Protégé GPS Stent - Tapered Version..... - 28 -

Figure 7: Stent Release System - 29 -

Figure 8: Rounded Radiopaque Markers - 29 -

Figure 9: Protégé Stent Measurements - 30 -

Figure 10: Spider Filter (ev3) - 31 -

Figure 11: Filterwire (Boston Scientific)..... - 32 -

Figure 12: Patient Characteristics - 34 -

Figure 13: Neurological History..... - 36 -

Figure 14: Angiographic Images of Intervention - 37 -

1 ZUSAMMENFASSUNG

Hintergrund

Ziel der Untersuchung war es die Sicherheit und Funktion des neuen Protégé Stents bei der Behandlung von Stenosen der Arteria Carotis communis und der Arteria Carotis interna zu evaluieren.

Methodik

Der Protégé GPS Stent ist ein selbst-expandierender Nitinol Stent. Er ist montiert auf einem 6 Fr (6-9mm Stent) oder 7 Fr (10mm Stent) Over-the-Wire-Deliverysystem und besitzt ein neuartiges Stentfreisetzungssystem um eine exakte Platzierung zu ermöglichen.

77 Patienten wurden in die Studie eingeschlossen. Die Patienten wurden vor dem Eingriff, während des Eingriffs, vor Entlassung, nach einem und nach sechs Monaten klinisch und mittels Duplexsonographie untersucht.

Ergebnisse

Siebenundsiebzig Stenosen wurden behandelt. 31 Stenosen waren symptomatisch, 46 asymptomatisch. Der Eingriff war technisch erfolgreich bei 76 (99%) Patienten. Der Stenosegrad wurde von $86 \pm 7 \%$ auf $16 \pm 8 \%$ reduziert. In einem Fall war der Eingriff erfolglos, da das Embolieprotektionssystem nicht zurückgezogen werden konnte und infolgedessen operativ entfernt werden musste. Innerhalb der ersten 30 Tage ereigneten sich 4 (5,2%) Major Adverse Neurological Events (MANEs). Drei der MANEs waren Major Strokes (3,9%), 1 Minor Stroke. Das fünfte MANE ereignete sich vor der 6-Monatsuntersuchung; dieser Patient hatte einen Major Stroke am Tag 75 nach dem Eingriff und verstarb 36 Tage später. Ein weiterer Patient verstarb an einer Urosepsis.

Schlussfolgerung

Die Untersuchungen haben gezeigt, dass der Protégé Stent die Sicherheits- und Funktionskriterien der Behandlung von Stenosen der Arteria Carotis interna erfüllt.

Die Komplikationsrate war vergleichbar mit derjenigen in anderen Carotis Stent- sowie Carotis Endarterektomie Studien.

2 ABSTRACT

Background

The purpose of the trial was to evaluate the safety and performance of the new Protégé stent in the treatment of common and/or internal carotid artery stenoses.

Methods

The Protégé® GPS stent is a self-expanding Nitinol stent system. It is mounted on a 6 Fr 0.018” (6-9mm stent) or 7 Fr, 0.035” (10mm stent) over-the-wire-delivery system and includes a new stent release system which allows exact placement of the stent.

Seventyseven patients were enrolled in the trial. Study patient assessments were conducted clinically and by duplex scan at baseline, peri-procedure, discharge, one and six months post procedure.

Results

Seventyseven lesions were treated. Thirtyone lesions were symptomatic, 46 lesions were asymptomatic. The procedure was technically successful in 76 (99%) lesions. The percentage of stenosis was reduced from $86 \pm 7 \%$ to $16 \pm 8 \%$. One procedure failed because the embolic protection device could not be retrieved and the patient was sent to surgery. Within 30 days there were 4 (5.2%) Major Adverse Neurological Events (MANEs). Three of the MANEs were major strokes (3.9%), one a minor stroke. The fifth MANE occurred prior to the six month follow-up visit; this patient had a major stroke 75 days after the procedure and died 36 days later. One additional death occurred due to urosepsis.

Conclusions

The trial shows that the Protégé stent satisfies safety and performance criteria for the treatment of carotid artery stenosis. The complication rate was comparable to the incidence of these events in other recent carotid stent and endarterectomy studies.

3 INTRODUCTION

3.1 Natural History of Carotid Disease

In the aging population, stroke is the most common and disabling neurological disorder, with more than half a million annual strokes in the United States alone. It is the third most common cause of death on industrial nations. There are approximately one million stroke-related events each year, including 500,000 new strokes, 200,000 recurrent strokes, and 240,000 TIAs. On average, someone has a stroke every 45 s and someone dies of stroke every three minutes [1]

Ischemic events are the cause of the vast majority of strokes (80 to 85%). Epidemiological trials have shown that ischemic events occur approximately four times as often as intracerebral bleeding [2]. It is known that the incidence of ischemic strokes significantly increases with age (33% in patients under 45 years of age and 80% in patients over 50 years of age). Of these, almost one third of all ischemic strokes are caused by carotid artery disease. More than 80% of clinical symptoms are due to embolism originating from arteriosclerotic plaques in carotid artery stenoses. In approximately 20% the strokes occur because of hemodynamic impairment of the cerebral circulation. The pattern of progression of carotid stenosis has shown to be unpredictable as the disease may progress swiftly or slowly, or remain stable for many years. [3, 4]

3.2 Morphology and Pathophysiology

Atherosclerotic disease is known to be a systemic disease. In most cases it not limited to a singular vascular bed, but instead affects all arteries throughout the body. Patients who suffer from symptomatic atherosclerosis in one vascular bed, for example patients with coronary heart disease are not only at risk of myocardial infarction, but are also at

risk of atherosclerotic disease of supraaortal and cerebral arteries leading to stroke, as well as atherosclerotic disease of peripheral arteries leading to limb ischemia.

Although atherosclerosis is the most common disease of the carotid arteries, it is important to be aware of further conditions associated to cerebral ischemia and infarction. These conditions include diseases of the aorta (dissection, aneurysm, aortitis), arteritis, fibromuscular dysplasia, dissection, dolichoectasia, primary vascular tumors, trauma, and complications of neck and head tumors.

Carotid atherosclerosis can produce retinal and cerebral symptoms by one of two major mechanisms, including progressive carotid stenosis leading to in-situ occlusion and hypoperfusion, or intracranial arterial occlusion resulting from embolization. Patients with carotid stenosis may develop symptomatic cerebral hypoperfusion from systemic causes. Patients in whom carotid distribution cerebral ischemia is suspected, should be closely evaluated for treatable causes, including sources of thrombogenic emboli from the carotid arteries, heart, and aortic arch [5].

The degree of carotid stenosis is associated with the risk of suffering stroke. Carotid stenoses greater than or equal to 50% have been identified in 7% of men and 5% of women older than 65 years. If there is slow flow through a severe stenosis a bruit may be absent. Therefore, cervical bruits are neither specific nor sensitive for identifying severe carotid artery disease. The risk of progression of carotid stenosis is 9.3% per year. Risk factors for progression include ipsilateral or contralateral ICA stenosis greater than 50%, ipsilateral ECA stenosis greater than 50%, and systolic blood pressure greater than 160 mm Hg. The annual stroke risk in patients with carotid stenosis is most dependent on the patient's symptom status and stenosis severity. However, it is also influenced by the presence of silent cerebral infarction, contralateral carotid disease, extent of collaterals, the presence of atherosclerotic risk factors, plaque morphology, and other clinical features as well. [5, 6, 7]

Atherosclerotic disease in the internal carotid artery begins as thickening of the vessel wall. When the intima-media complex is measured >1 mm the term plaque is used. Significant narrowing of the internal carotid artery or plaque rupture may lead to an ischemic occlusion of cerebral arteries. In cases of unstable atherosclerotic lesions, thrombus formations can be released, which then result in cerebral embolism. These situations mostly result in a stroke. In 2004, Biasi et al reported on the index of echogenicity, named the grey-scale median as a risk indicator of stroke during carotid stenting. [8] They concluded that carotid plaque echolucency, as measured by grey-scale median ≤ 25 , increases the risk of stroke in carotid artery stenting.

3.3 Neurovascular Anatomy

Knowledge of the extra- and intracerebral anatomy is fundamental. The left common carotid artery arises from the aortic arch, while the right arises from the bifurcation of the brachiocephalic trunk. Neither common carotid artery has side branches, but each divides into the internal and external carotid artery at the level of the upper border of the thyroid cartilage. The external carotid artery starts at the bifurcation of the common carotid artery supplying the jaw, face, neck and meninges. The two terminal branches of the external carotid artery are the superficial temporal artery and maxillary artery. These two branches in addition to the occipital artery can serve as collateral channels for blood supply to the brain if the internal carotid artery or the vertebral artery is occluded. Vertebral arteries provide the brain with only a small amount of blood but can become more important if the carotid arteries are narrowed or blocked. The internal carotid artery ascends laterally behind the hypopharynx where it can be palpated. It bifurcates into the anterior cerebral artery and the larger middle cerebral artery. The extracranial segment of the internal carotid artery does not have significant branches visible. The first major intracranial branch is the ophthalmic artery.

In young adults and children the aortic arch is symmetrically curved and the origins of the brachiocephalic arteries are aligned in straight lines and courses superiorly. [9] The aging and arteriosclerotic process elongate and distend the aortic arch. The ostia of the

brachiocephalic arteries are shifted - the Aortic knob becomes more superior and posterior. It becomes more difficult to selectively catheterize these vessels. Furthermore, the internal carotid arteries themselves develop tortuosities during the aging process. This has to be considered during the intervention, as it can make the cannulation of the artery as well as filter and stent placement very challenging.

The most important intracranial collateral pathway is the circle of Willis, connecting through the anterior and posterior communicating arteries the anterior, middle and posterior cerebral arteries. In situations where the atherosclerotic process develops gradually, this circle can compensate an occluded internal carotid artery. Yet it is essential to know that the circle of Willis is not complete in all patients. In these patients, even a short, temporary occlusion of the internal carotid artery can result in a disabling stroke.

3.4 Historical Perspective of Carotid Endarterectomy (CEA)

The intention of interventional or surgical treatment of the carotid artery is focused on removing debris that is likely to cause distal embolisation or a hemodynamic significant vessel lumen narrowing.

Surgical treatment for carotid artery stenosis is the traditional standard of care, initially performed in the 1950's by pioneers such as DeBakey, Eascott, and Cooley [10, 11]. Initial surgical trials were prematurely stopped due to high morbidity and mortality rates [12, 13, 14]. By the early 1980s, Carotid endarterectomy was the most frequently performed vascular surgical procedure. However, the failure of the external carotid–internal carotid bypass operation to prevent stroke and the absence of clinical trial data provoked challenges about the safety and efficacy of CEA [15, 16].. Only in the nineties randomized trials could prove benefit of carotid endarterectomy compared to medical treatment. One of these trials, the NASCET Trial [17, 18], demonstrated a 30 day death and stroke rate of 5.8% in patients with severe stenosis of more than 70%.

This rate increased to only 6.7% at eight years of follow up. However, the only high-risk group included was patients with contralateral occlusion. A sub-analysis of this patient group showed a higher combined stroke and death rate of 14%. On the other hand, it was shown that patients with stenoses of less than 50% did not benefit from surgery [19].

The results found in the ECST Trial could also confirm the superiority of CEA compared to medical therapy. The perioperative stroke and death rate was 7.5% in the surgical arm. CEA could further reduce the 3 year rate of stroke and death to 14.9% compared to medical therapy with 26.5% [20].

3.5 Potential Complications of Carotid Endarterectomy

Potential complications after CEA include cardiovascular complications (vasovagal and vasodepressor reaction, myocardial infarction), neurological complications (stroke, hyperperfusion syndrome, intracranial hemorrhage, seizures, cranial nerve injury), wound problems (infection, hematoma), injury to the carotid artery (dissection, thrombosis, restenosis), and death.

3.6 Historical Perspective of Carotid Stenting

In the past several years, carotid stenting has rapidly developed into an alternative to surgery and is increasingly the preferred method in surgically high-risk patients [21, 22, 23, 24]. Many patients tend to favor stenting to surgery, because it is less invasive, does not cause a scar and requires only a short hospital stay less than 24 hours. Other advantages of the interventional approach over carotid surgery include the ability to diagnose and treat embolic complications immediately. Furthermore, the fact that the patient can be awake during the procedure, allows close neurological monitoring. Complications like distal embolization can therefore be recognized and treated immediately.

Three randomized trials (Brooks Trial [14], CAVATAS [23] and SAPPHERE [24]) showed equivalency of carotid angioplasty/stenting and CEA at least in selected patients.

3.7 Potential Benefits of Carotid Stenting

If the results are similar, patients may prefer angioplasty and stent implantation because it is less invasive than surgery, does not cause a scar and requires a short hospital stay. It provides the ability to immediately diagnose and treat embolic complications, and the patient can be awake, allowing close neurological monitoring.

3.8 Embolic Protection Devices

A major limitation of carotid angioplasty is peri-interventional distal embolisation. Balloon dilatation, stenting and manipulation of the vessels through catheters and wires are likely to release debris that can cause severe cerebral damage. Therefore, in most centers embolic protection devices are used routinely. Currently, there are three different approaches to cerebral protection: Filters, distal occlusion balloons and proximal occlusion balloons which occlude the common and external carotid artery.

3.8.1 Types of Embolic Protection Devices

3.8.1.1 Distal Occlusion Balloons

Distal occlusion balloons were the first system of protection commercially available and therefore used on a large scale. They consist of a 0.014 inch guide with a balloon mounted on the distal portion that is inflated and deflated through a very small channel contained in the guide itself (Guardwire® Temporary Occlusion and Aspiration System (Medtronic Vascular), TriActiv® ProGuard™ Embolic Protection System (Kensey Nash). The lesion is crossed with the guide thereby positioning the balloon distally to the stenosis where it is inflated until the blood flow in the internal carotid artery is blocked. Following this, the angioplasty and stenting procedure is carried out.

On completion of the procedure, a catheter is advanced up to the distal balloon and the column of blood contained in the occluded internal carotid artery is aspirated. In this way debris dislodged during the stent procedure can be eliminated. Afterwards the balloon is deflated and the guide is removed. The advantages of distal occlusion balloons are their small diameter (2.2 French), their good maneuverability and flexibility. Possible disadvantages are that internal carotid artery occlusion is not tolerated by 6–10% of patients [25, 26] and that it is not possible to image the vessel distal to the occlusion balloon with contrast medium during inflation.

3.8.1.2 Filter Devices

Most filters consist of a metallic structure coated by a membrane of polyethylene or a Nitinol net containing holes of 80–200 μm in diameter. The filters are usually positioned at the distal portion of a 0.014 inch guide. During the procedure the filters are enclosed into a delivery catheter with which they are advanced distal to the stenosis. After the lesion is crossed, the filter is opened by removing the delivery sheath. At the end of the stenting procedure, the filter is closed into the distal tip of a retrieval catheter and removed from the carotid artery.

A large number of second or third generation filters are currently available. The technical characteristics of a good filter consist of a low profile (< 3 French), an adequate torqueability to cross tortuous vessels and, when opened, an adequate apposition to the wall to assure the best possible embolic protection.

The FiberNet device is the first embolic protection device which combines features of a filter and of a distal occlusion device in one system. It consists of a 3-dimensional Polyethylene Terephthalate (PET) fiber-based filter which has the ability to capture particles as small as 40μ , mounted onto a 0.014 inch, 190 cm wire and focal suction is provided through a retrieval catheter.

3.8.1.3 Distal Occlusion Balloons

Distal protection devices, both occlusive balloons and filters, have the disadvantage that it is mandatory to cross the lesion before they are inflated or opened. This unavoidable step carries the risk of embolisation during this ‘unprotected’ phase of the procedure. Proximal protection systems such as the Gore Neuro Protection System (Gore) and MO.MA system (Invatec), provide cerebral protection before passing any type of device through the stenosis. This is especially important in lesions which contain fresh thrombus. The operator can use the wire of his choice which helps to cross difficult lesions. These systems consist of a long introducer sheath with a balloon that is inflated in the common carotid artery. A second balloon, inflated in the external carotid artery, assures the total blockade of the antegrade blood flow in the internal carotid artery. The proximal protection systems facilitate the cerebral vascular connections of the circle of Willis. After the occlusion of the common and external carotid artery, the collateral flow through the circle of Willis creates so-called ‘back-pressure’ which prevents antegrade flow in the internal carotid artery. After stent positioning, and before deflation of the balloons in the common and external carotid artery, the blood in the internal carotid artery – possibly containing dislodged debris – is aspirated and removed. Intolerance of balloon occlusion seen in some patients is an ongoing disadvantage of proximal protection systems [27].

3.9 The PROCAR Trial: Protégé Stent in the Treatment of Carotid Artery Stenosis with Adjunctive Use of a Filter Embolic Protection Device

A prospective, multicenter trial was conducted to assess the safety and performance of the Protégé GPS stent (ev3, Inc) in the treatment of de novo or restenotic common and/or internal carotid artery stenoses with adjuvant use of a filter embolic protection device.

The Protégé GPS stent is a self-expanding Nitinol stent developed for the treatment of carotid artery stenosis which includes a new stent release system which allows exact

placement of the stent. The delivery system is comprised of an inner and outer sheath, which are locked together with a safety lock. Stent positioning at the targeted lesion is achieved prior to deployment using the two radiopaque markers on the inner sheath, which mark the location of the constrained stent. For stent deployment, the safety lock is turned counterclockwise to unlock the outer sheath. The outer sheath retraction is achieved by pulling the distal grip toward the proximal grip. Complete deployment of the stent is achieved when the radiopaque marker on the outer sheath is just proximal to the proximal marker on the inner sheath. This ensures that the stent is held in place until the stent is fully released to prevent the stent from jumping forward during deployment.

4 METHODS

4.1 Study Design and Objectives

The trial was designed to evaluate the safety and performance of the Protégé Stent in the treatment of common and/or internal carotid artery stenosis with adjunctive use of a filter embolic protection device. Operators were free to choose any distal embolic protection device of their choice. Patients in whom the Protégé Stent could not be placed were followed in the trial through hospital discharge (intention to treat analysis). The primary endpoint was the incidence of device or procedure-related major adverse neurological events (MANE) through one month, assessed by an independent neurologist. MANE was defined as any major or minor stroke, and all death. The distinction between major and minor stroke was made by use of the NIH Stroke Scale (Figure 1). Secondary endpoints addressed safety and performance of the Protégé Stent and included the following: (1) Technical success: Ability to perform Protégé Stent placement with adjunctive use of a filter embolic protection device with residual stenosis < 30%, (2) correct placement of the Protégé Stent, (3) primary patency of the treated vessel as determined by duplex scan at one and six months and (4) incidence of device or procedure-related MANE at discharge and six months. The overall study design is shown in Figure 1.

Figure 1: Stroke Classification

Major Stroke	Classification
NIH \geq 15	If NIH >4 at enrolment, any change \geq 5 points is a major stroke post procedure
Minor Stroke	Classification
NIH \leq 4	If NIH > 4 at enrolment, any change \leq 4 points is a minor stroke post procedure

4.2 Study Requirements

The selection criteria are listed in figure 2 and 3. Informed consent was obtained in accordance with Ethics Committee policies, procedures and regulations. The initial screening was undertaken by performing a physical examination, which included a medical history, a complete neurological examination including NIH Stroke Scale, routine clinical laboratory tests, perfusion/diffusion brain CT scan or MRI and a carotid duplex scan. The procedural angiographic measurement was the final determinant of eligibility ($\geq 80\%$ stenosis for asymptomatic patients, $\geq 70\%$ stenosis for symptomatic patients). The severity of stenosis was measured using the North American Symptomatic Carotid Endarterectomy Trial (NASCET) method. Successful placement of the filter embolic protection device was mandatory for inclusion in the study. The overall study design is shown in figure 4.

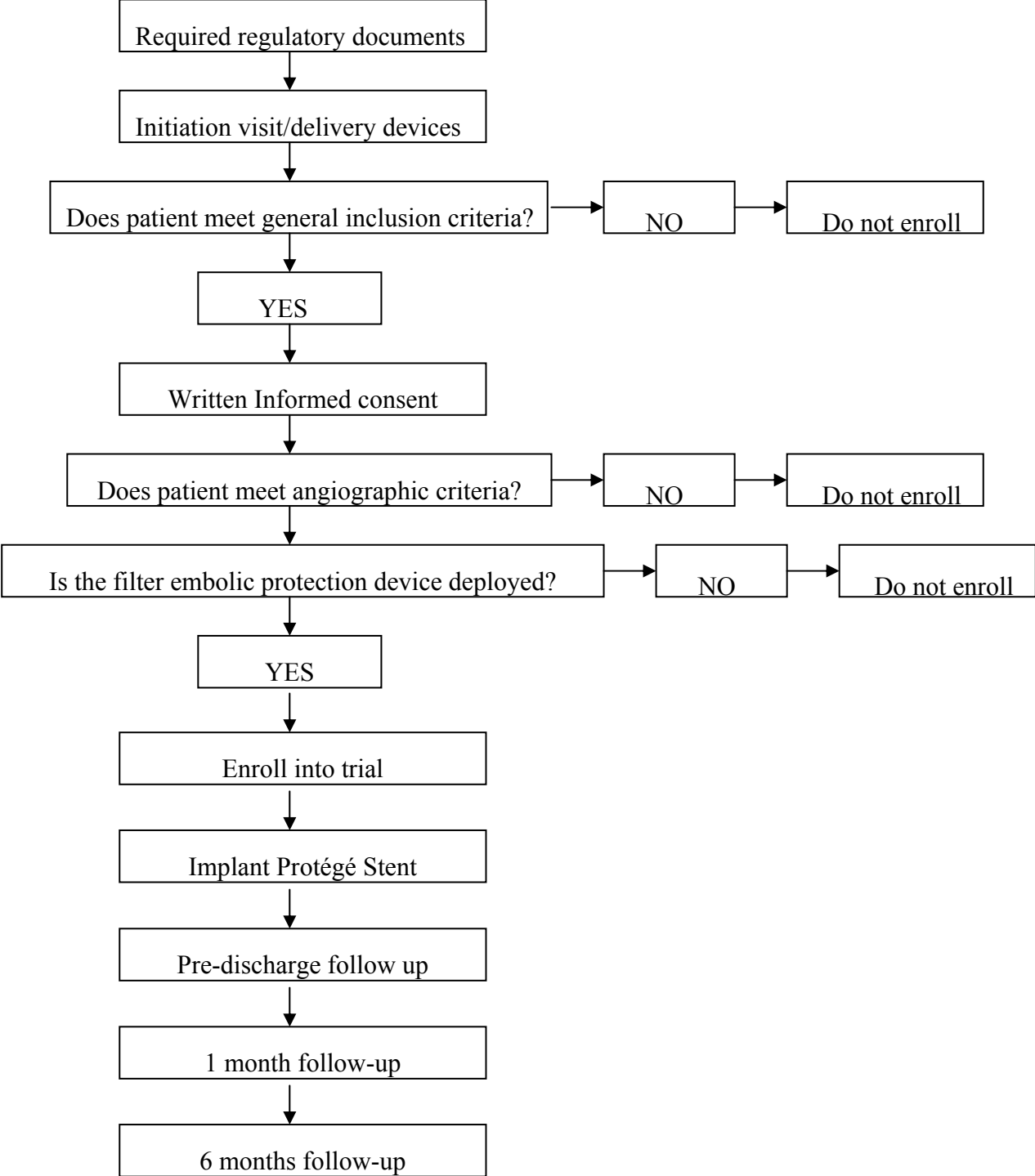
Figure 2: Inclusion Criteria

- De novo or restenotic lesion located in the common and/or internal carotid artery and suitable for PTA/stenting with adjunctive use of a filter embolic protection device
- Target lesion stenosis is defined according to angiographic NASCET criteria
- $\geq 80\%$ stenosis for asymptomatic patients
- $\geq 70\%$ stenosis for symptomatic patients
- Symptomatic patients are defined as those with carotid stenosis associated with ipsilateral cerebral or visual transient ischemic attack (TIA) evidenced by amaurosis fugax, ipsilateral hemispheric TIAs or ipsilateral ischemic stroke within 6 months prior to enrollment
- Filter embolic protection device is successfully placed.
- Patient is a candidate for femoral access percutaneous interventional treatment of a carotid lesion with stenting
- Reference vessel diameter for stent placement is ≥ 4.5 and ≤ 9.5 mm
- Vessel diameter distal to target lesion allows placement of a filter embolic protection device

Figure 3: Exclusion Criteria

- Planned to treat another vessel in the same procedure
- Life expectancy of less than six months
- Abnormal International Ratio (INR) level (<1.5 or >3.5) while on coumadine/warfarin treatment
- Intolerance to heparin, or aspirin, or clopidogrel and ticlopidine
- Allergy to nickel or titanium
- Myocardial infarction (MI) within 3 days prior to the procedure
- Acute stroke or stroke in evolution within 14 days prior to the procedure
- Major residual neurological deficit (stroke scales: NIH ≥ 15 at pre-procedure neurological exam)
- Ipsilateral intracranial stenosis more severe than target lesion stenosis
- Total occlusion of target vessel
- Target lesion is in an in-stent restenosis
- Presence of multiple carotid stenoses in the same vessel that can not be covered by two overlapping Protégé stents
- Presence of intracranial tumor(s), arterial vascular malformations (AVMs), or aneurysms

Figure 4: Overall Study Design



4.3 Outcome Analysis

To control inter-observer variability, the author determined the angiographic and duplex results of all study patients included in the data analyses and was continuously supervised by an independent angiographic and duplex core laboratory (Heart Core, Leiden, The Netherlands) . Although each investigator's visual assessment was used to determine patient eligibility at the time of enrolment, the author's values superseded the investigator's measurements.

An independent Clinical Event Committee (CEC) adjudicated all reported complications to classify them as MANEs according to the definitions as outlined in the protocol.

The statistical analysis of the patient population was based on the principle of intention-to-treat. The analysis population consisted of all patients who gave informed consent, fit the selection criteria and in whom a carotid procedure was attempted. All analyses were conducted using SAS Version 8.

The primary performance parameter was the incidence of device or procedure MANEs during the procedure through one month. The incidence of all MANEs and each type of MANE was calculated by dividing the number of patients with a MANE by the number of patients treated. The 95% confidence limits on the rate were also calculated. Product-limit estimates of the survival and occurrence rates (with 95% confidence limits) at one month (31 days post-procedure) and six months (180 days post-procedure) were also calculated.

Secondary performance endpoints included:

- Ability to perform Protégé Stent placement with adjunctive use of a filter embolic protection device with residual stenosis < 30%

- Primary patency as determined by Duplex Scan at one and six months
- Incidence of device or procedure related MANEs at discharge and six months

Successful placement of the stent was analyzed descriptively, by calculating the numbers and percentages of patients in whom no difficulties were experienced. Residual stenosis was summarized by calculating the minimum and maximum values and the numbers and percentages of patients with none, 1-10%, 11-20% and >20% residual stenosis. Primary patency was evaluated by calculating the number and percentage of patients with re-stenosis at one month.

4.4 Procedure Management

Patients were pre-treated with a minimum of 100 mg aspirin p.o. within 1 hour prior to the procedure and clopidogrel (e.g. Plavix®) 300 mg p.o. within 24 hours prior to procedure, but no later than 2 hours before the start of the procedure. In case of intolerance to clopidogrel, 500 mg ticlopidine could be used as an alternative.

Percutaneous femoral artery access was secured via standard sterile technique. Sufficient heparin was administered to maintain the activated clotting time ≥ 250 seconds throughout the interventional portion of the procedure. Angiography of the carotid artery was performed to identify the anatomical characteristics of the intracranial and carotid vessels and to provide information on the lesion. Based on the NASCET method, calculations were performed to determine the degree (percent), length of the stenosis and sizing requirements for the filter embolic protection device. Intracranial circulation films were obtained immediately prior to and after the implantation procedure to document baseline and final results. Any of the available filter embolic protection device could be used. If the filter embolic protection device was removed during the procedure and the investigator continued to perform additional PTA and/or stenting of the lesion, a new filter embolic protection device

had to be selected and placed in the artery before continuing the procedure. Carotid artery angioplasty and stenting was performed using standard angioplasty methods and equipment as described below [28].

- Femoral/Transbrachial/Radial Access:

Puncture of the artery with a Seldinger needle, placement of a 5-6 French 12 cm arterial sheath or cut-down (brachial artery).

- Cannulation of the Common Carotid Artery:

5F diagnostic catheter is advanced over a 0.035” guide wire into the ascending aorta.

- Carotid Sheath/Guiding Catheter Placement:

Cannulation of the external carotid artery, removal of the diagnostic catheter, placement of a long carotid sheath in the common carotid artery or placement of a guiding catheter (in this case no diagnostic catheter is previously needed).

- Pre-dilatation:

Usually a 3-4 mm balloon is chosen. Pre.dilatation is only performed if degree of stenosis or severe calcification prevents direct stenting.

- Placement of Embolic Protection Device:

Distal filters are placed in a straight vessel segment approximately 2 cm distal to the lesion. Distal occlusion balloon are placed and inflated in the pars petrosa of the internal carotid artery. Proximal occlusion systems are placed and inflated in the common external and common carotid artery.

- Stent Deployment:

The diameter of the self-expanding stent should be 1-2 mm larger than the widest diameter to be covered. The length of the stent should cover the entire lesion.

- Post-dilatation:

The balloon should be placed in the stent-segment placed in the internal carotid artery. The diameter of the balloon should be equal to the diameter of the internal carotid artery distal to the stent (usually 5-6 mm in diameter). To prevent dissections, post-dilation should be performed at nominal pressure.

Post-stent deployment dilation(s) was left to the discretion of the investigator and could be performed with an appropriately sized, low-compliance balloon catheter to ensure that the stent was in full contact with the arterial wall. Peri-stent dissections could be treated conservatively, or with additional study stent implantation, according to the decision of the operator. Also similarly, haziness, lucency or filling defects within or adjacent to the stent, could be treated according to the decision of the operator.

4.5 Post-procedure Management

After intervention, a complete neurological exam, including NIH Stroke Scale, was performed by an independent neurologist prior to hospital discharge.

A post-procedure perfusion/diffusion CT scan or MRI was done within 7 days. (the same diagnostic test that was done at baseline was requested at pre-discharge).

A repeat carotid artery duplex scan before discharge was performed to assess stent patency. Clopidogrel 75mg was to be given p.o. once daily for a minimum of 1 month after the study procedure. In case of allergy or intolerance to clopidogrel, ticlopidine

250mg p.o. twice daily could be given instead. Aspirin \geq 100 mg p.o. was to be given once daily for a minimum of 6 months.

Post stent implantation, all enrolled patients had to attend 1- month (30 days +/- 10 days) and 6- month (180 +/- 30 days) clinic visits for the following:

- Assessment of the patient's clinical status and documentation of any complications,
- review of anti-coagulation/antiplatelet medications,
- carotid artery duplex scan to assess stent patency,
- complete neurological exam, including NIH Stroke Scale, by an independent neurologist.

If the patient experienced new or recurrent neurological symptoms, a more detailed examination and/or testing could be done according to the investigator's discretion. If the patient had a change in the neurological exam score, or a neurological event was suspected, a repeat diffusion/perfusion CT scan or MRI was done.

4.6 Description of Stent

The Protégé GPS Stent (ev3, Inc) is a new self-expanding Nitinol stent system (Figure 5 and 6). The stent is laser-cut from a Nitinol tube in an open lattice design. The stent is made of a nickel titanium alloy (Nitinol) and comes pre-mounted on a 6 Fr (6-9 mm stent) or 7 Fr (10 mm stent), over-the-wire delivery system. The 6 Fr delivery system accepts a 0.018" wire, the 7 Fr delivery system a 0.035" wire. Upon deployment, the stent achieves its predetermined diameter and exerts a constant, radial force to establish and maintain patency.

The delivery system is comprised of an inner and outer sheath, which are locked together with a safety lock. The nylon inner shaft terminates distally in a flexible

catheter tip and originates proximally at the hub. Two radiopaque markers, one marker distal and one marker/retainer proximal to the constrained stent are on the inner sheath.

The outer sheath connects proximally to the Y-adapter. The self-expanding stent is constrained within the space between the inner and outer sheaths. The outer sheath has a radiopaque marker at its distal end.

The stent technology utilizes a new stent release system (Figure 7), relying on the proximal marker band to serve as a retaining ring. The marker band is cut like an interlocking piece to a jigsaw puzzle to interlock with the rounded radiopaque markers (Figure 8) at the end of the stent. This system ensures that the stent is held in place until the stent is fully released to prevent the stent from jumping forward during deployment. The stent size is selected so the diameter is approximately 1mm greater than the largest reference diameter. The Protégé GPS stent measurements are shown in figure 9.

The Protégé GPS stent offers the unique possibility to inject contrast through the stentdelivery system (Starport system) at the exact target lesion spot. This allows perfect visualization of the lesion to treat prior to stenting and eliminates eventual contrast injection problems encountered by injecting through the long introducer sheath.

Figure 5: Protégé GPS Stent - Straight Version




Figure 6: Protégé GPS Stent - Tapered Version



Figure 7: Stent Release System

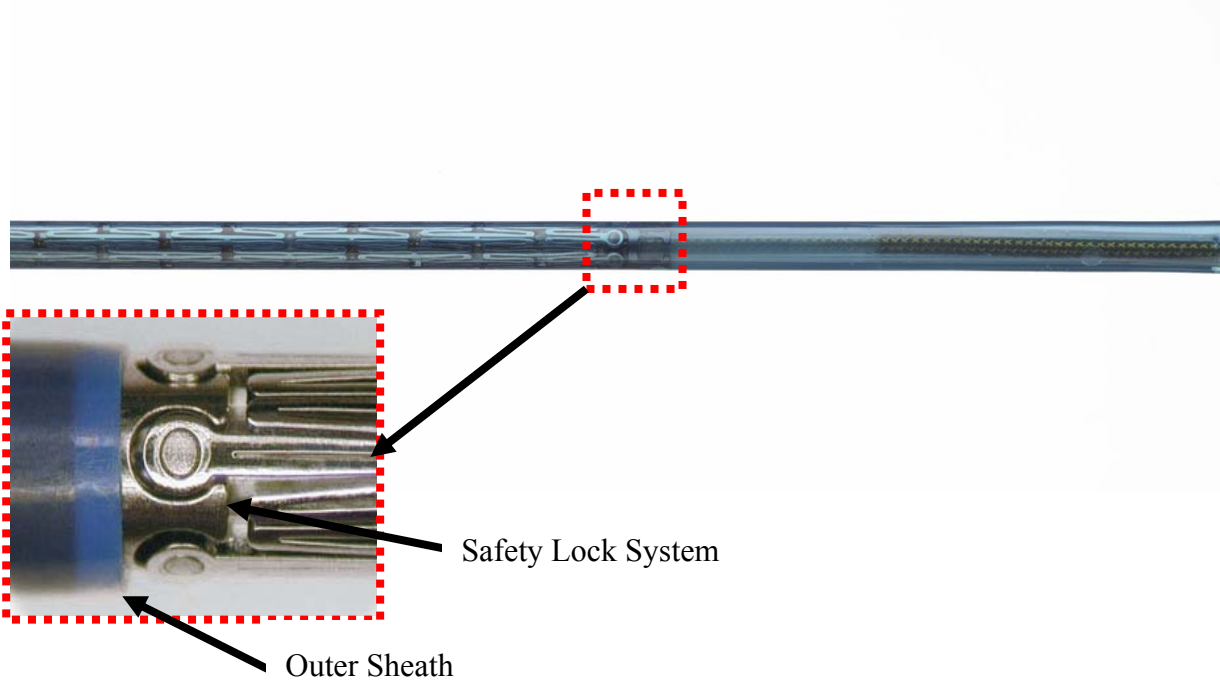


Figure 8: Rounded Radiopaque Markers

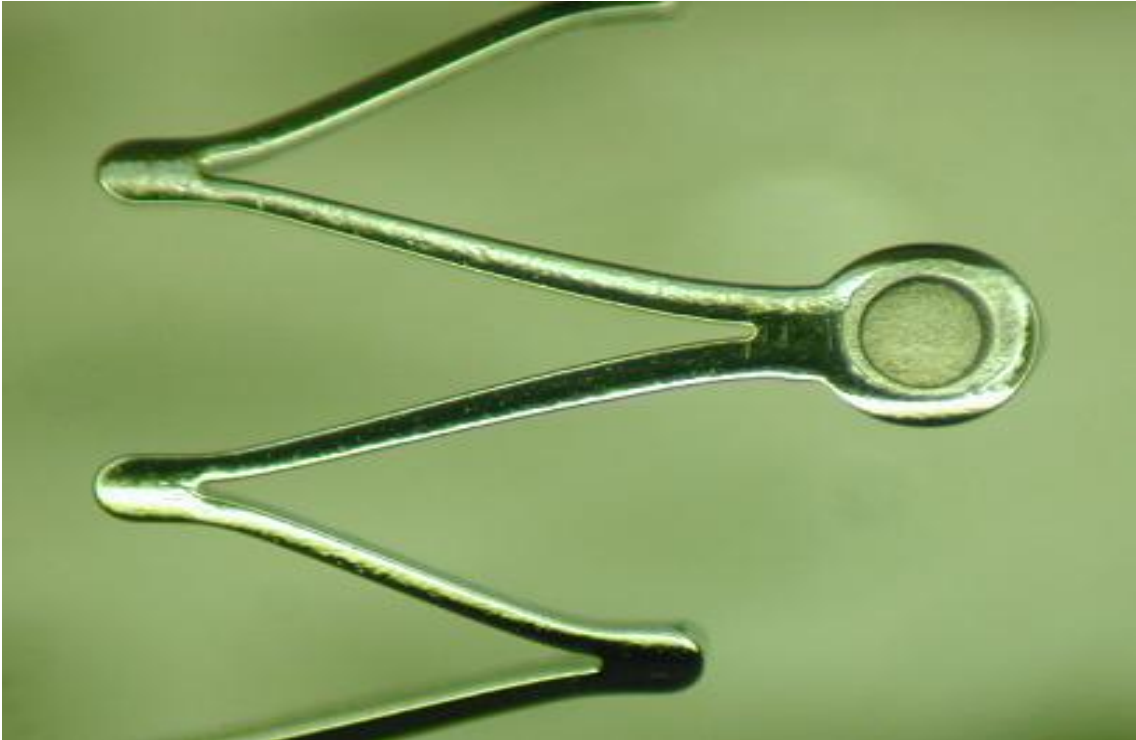


Figure 9: Protégé Stent Measurements

Unconstrained Stent Diameter (mm)	Stent Length (mm)	Configuration	Lumen Diameter (mm)
6	20, 30, 40, 60	straight	4.5-5.5
7	20, 30, 40, 60	straight	5.5-6.5
8	20, 30, 40, 60	straight	6.5-7.5
9	20, 30, 40, 60	straight	7.5-8.5
10	20, 30, 40, 60	straight	8.5-9.5
8-6	30, 40	tapered	(6.5-7.5)-(4.5-5.5)
10-7	30, 40	tapered	(8.5-9.5)-(5.5-6.5)

4.7 Description of Filters Used in the Trial

The two filters used in this study were the Spider filter from ev3 (Figure 10) and the Filterwire from Boston Scientific (Figure 11). In the majority of cases (75/77, 97%) the Spider System was used. This percutaneously delivered distal embolic protection device designed to capture and remove debris from internal carotid artery vessels during interventional procedures. It allows use of any guidewire to cross the lesion. It consists of a capture wire, delivery catheter, stylet, and recovery catheter. The capture wire is a Nitinol mesh filter mounted on a convertible 175/320 cm coated 0.014 inch stainless steel wire. The recovery catheter is used to recover the filter and capture debris. The device is available in five filter sizes: 3, 4, 5, 6 & 7mm.

The Filterwire was used in 2 cases (2/77, 2,6%).It consist of a 0.014” guide wire with a shapeable distal tip and a polyurethane filter basket based on an eccentric nitinol loop. Due to its expandable loop structure, one size can be placed in vessels between 3.5 and 5.5 mm in diameter.

Figure 10: Spider Filter (ev3)


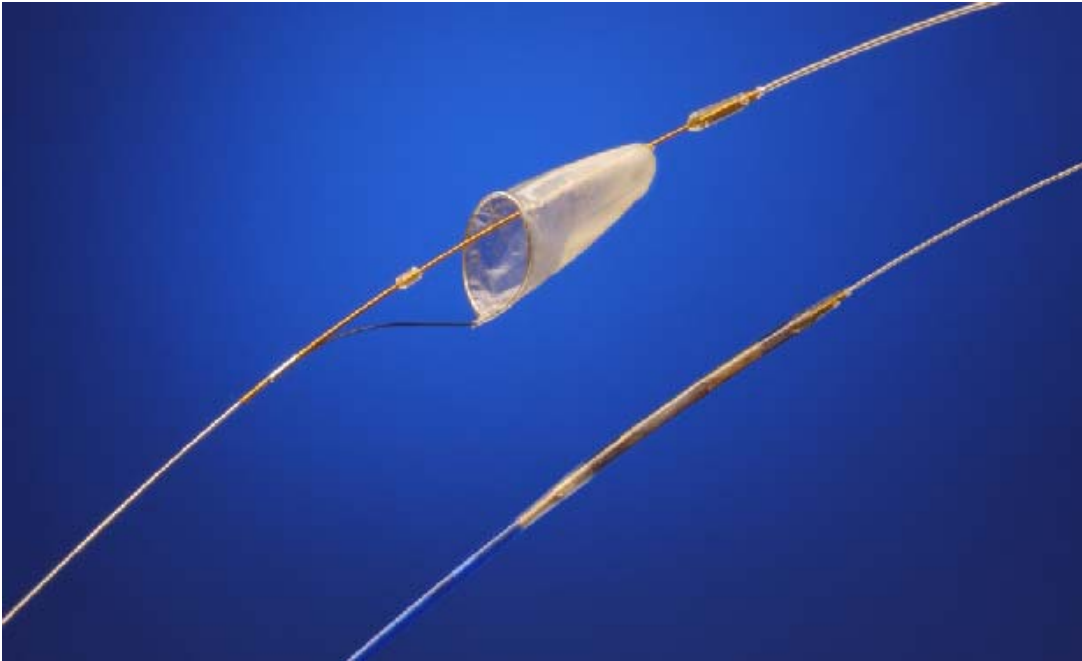


Figure 11: Filterwire (Boston Scientific)



5 RESULTS

5.1 Patient Characteristics

A total of 77 patients were included in this analysis (31 symptomatic, 46 asymptomatic). Figure 12 shows the patients' baseline characteristics. The patients' overall mean age was 72 years; they ranged in age from 55 to 87 years. The majority (71%) were male. A total of 31 (40%) patients were either current (10 patients, 13%) or previous (21 patients, 27%) smokers. Fifteen (20%) patients had been previously diagnosed with diabetes. A total of ten (13%) patients had previously had a CEA; four patients (5%) had ipsilateral CEA, while six patients (8%) had contralateral CEA. Overall, 43 (56%) patients had at least one co-morbidity or experienced surgery within the last five years prior to study enrollment. A summary of the patients' neurological history is shown in figure 13.

Figure 12: Patient Characteristics

Baseline Characteristics	(N = 77)
Age (yr)	
Mean \pm SD	72 \pm 8
Median	73
Gender	
Male	55 (71%)
Female	22 (29%)
Canadian Cardiac Society (CCS) angina class	
None (0)	65 (84%)
1	4 (5%)
2	2 (3%)
3	0 (0%)
4	1 (1%)
Unknown	5 (7%)
Smoking	31 (40%)
Current	10 (13%)
Previous	21 (27%)
Congestive heart failure	7 (9%)
Prior MI(s)	12 (16%)
Other cardiac conditions	28 (36%)
Hypertension requiring treatment	69 (90%)

Baseline Characteristics	(N = 77)
Diabetes	15 (20%)
GI bleeding / active ulcers	1 (1%)
Ipsilateral endarterectomy	4 (5%)
Contralateral endarterectomy	6 (8%)
Current carotid bruits	51 (66%)
Within last 5 years – total	43 (56%)
Renal disease or surgery	5 (7%)
Gastrointestinal disease or surgery	15 (20%)
Respiratory disease or surgery	10 (13%)
Musculoskeletal disease or surgery	9 (12%)
Other disease or surgery	28 (36%)

Figure 13: Neurological History

Neurological History	(N = 77)
Ophthalmic artery ischemia	5 (7%)
Anterior cerebral artery ischemia	2 (3%)
Middle cerebral artery ischemia	11 (14%)
Lacunar ischemia	5 (7%)
TIA	28 (36%)
Ischemic stroke	11 (14%)

5.2 Technical Success

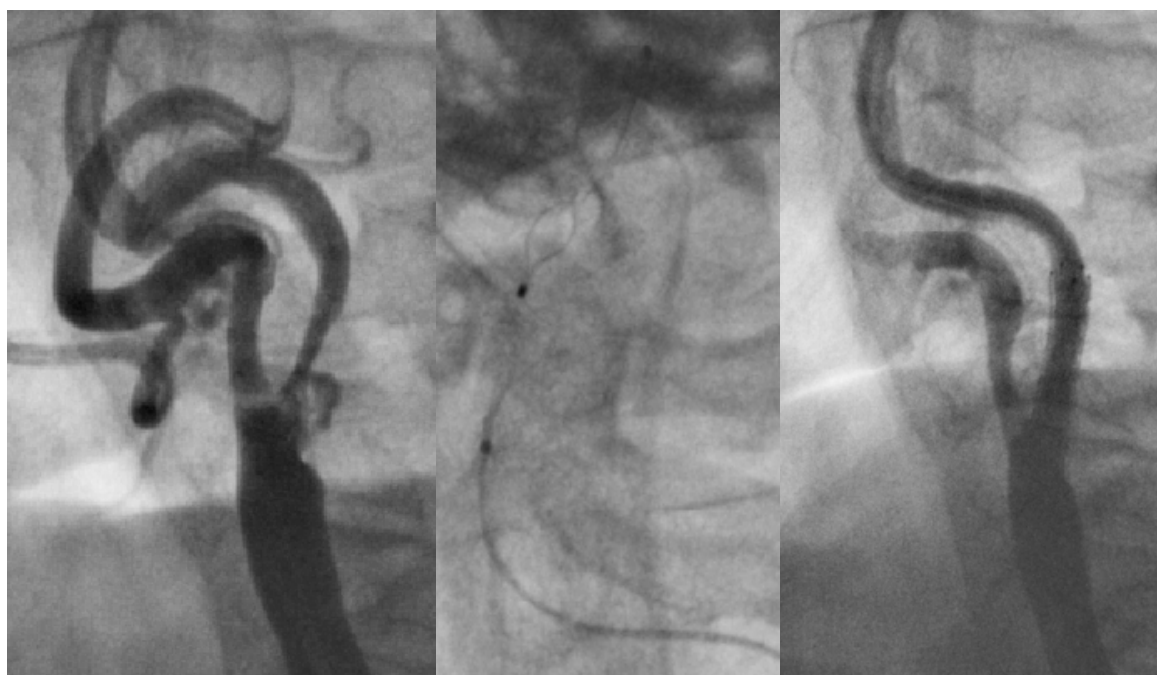In 75 patients (97%) the procedure was performed with the Spider Filter and in two cases a FilterWire (Boston Scientific) was used. Figure 14 displays an example of the use of a Spider Filter and a Protégé stent in a left internal carotid artery. There were no instances of multiple filter systems being placed. The filter system was successfully retrieved in 76 (99%) patients. In one patient, the Spider filter could not be retrieved successfully because it got hooked to the distal stent edge. This caused a blockage in the cranial part of the stent. The stent was dislodged into the common carotid artery and the patient was sent to surgery.

Pre-dilatation of the stenosis was performed in 23 (30%) patients. The stent used in the first stent placement was implanted in all 77 patients (100%). There were no occurrences of a second stent placement. The stent position was placed positioned correctly in all 77 patients (100%).

At baseline, 70 patients (91%) had a percent stenosis greater than 80%. The smallest percent stenosis was 70% and the greatest percent stenosis was 99%. The minimum and maximum percent stenosis after pre-dilatation were 10% and 85%, respectively.

The final outcome percent residual stenosis was 0% for 50 (65%) patients, between 1% and 10% for 18 (23%) patients, and between 11% and 20% for eight (10%) patients. Of the 77 patients included in this analysis, 76 (99%) patients met the criteria for technical success, with a residual stenosis of less than 30%.

Figure 14: Angiographic Images of Intervention



5.3 Patient Outcomes at One Month

During the first month after the procedure, the primary endpoint of the study was observed in four patients (all symptomatic), giving an overall incidence rate of 5.2% (95% C.I. 0.2% – 10.2%). There were three MANEs which were ipsilateral major strokes (incidence rate = 3.9%, 95% C.I. 0.0% – 8.2%) and one ipsilateral minor stroke (incidence rate = 1.3%, 95% C.I. = 0.0%-3.8%). During the procedure, one

major stroke occurred and was adjudicated by the CEC to be procedure- related; the second major stroke occurred two days after the procedure, and was adjudicated to be related to both the device and the procedure; the third major stroke occurred 31 days after the procedure and was adjudicated by the CEC to be unrelated to the device or procedure. The minor stroke occurred on the day of the procedure and was adjudicated to be procedure-related. There were no deaths between enrollment and the one-month follow-up visit.

At the 1 month follow up, seventy four patients had a duplex scan. This could be evaluated in 67 of these patients (one patient had been excluded from the analysis as the stent was removed during an endarterectomy immediately post procedure). No restenosis was seen in 60 patients (89.6%) at 1 month follow up. Only two patients (3.0%) had a mild stenosis (stenosis < 50%). Minimal stenosis (stenosis < 30%) was detected in five patients (7.5%).

5.4 Patient Outcomes at Six Months

An additional MANE occurred between the one month and six month follow-up visit in a patient with an asymptomatic lesion (the patient had a symptomatic contralateral lesion with an ischemic stroke four years prior to the procedure) who had a contralateral major stroke 75 days after the procedure. The stroke type was ischaemic and located in the occipital cerebral cortex. The probable source was the vertebral artery. The patient died 36 days later. Thus, five patients in total experienced a MANE by the six -month follow-up visit, giving an overall incidence rate of 6.5% (95% C.I. 1.0% - 12.0%). An additional death occurred on post-procedure day 151. The patient had a history of myocardial infarction, hyperuricaemia, homocysteinaemia and polyglobulinaemia. At the 1 month follow up visit, the aspirin treatment had been stopped as the patient had been admitted for a CAGB. The patient had a major ischaemic stroke (assumed cardiac origin) located in the frontal cerebral cortex while

in hospital for a CABG, unrelated to the procedure or the study device. The patient developed a sepsis related to recurrent urinary tract infections and died.

Out of 72 patients, 66 (92%) had a carotid duplex scan for the 6 -month follow up visit. One patient had been excluded from the analysis as the stent had been removed during the CEA immediately post-procedure. There was no restenosis seen in 51 patients (77.3%). Twelve patients (18.2%) had minimal stenosis (stenosis < 30%) while three patients (4.5%) had a mild stenosis (stenosis < 50%).

6 DISCUSSION

Carotid stenting has become an important alternative to CEA. Currently, it is routinely performed in many centers with increasing numbers of patients seeking a less invasive treatment alternative. The introduction of distal embolic protection devices and sophisticated stent designs, and increased operator experience have improved the outcome of carotid artery stenting [28, 29, 30, 31].

6.1 Surgical Trials

Two large trials, the North American Symptomatic Endarterectomy Trial (NASCET) and the European Carotid Surgery Trial (ECST) have effectively shown that carotid endarterectomy can prevent strokes and death in symptomatic patients compared to best medical therapy [18, 19, 20]. Shortly after these trials were published, carotid endarterectomy was considered the gold standard for treatment of carotid stenosis.

In the NASCET trial, patients with symptomatic internal carotid artery stenosis of more than 70% were randomized to receive either carotid endarterectomy or medical therapy. The cumulative risk of ipsilateral stroke was 9% for the surgical group and 26% for the medical group. This was an absolute reduction of 17%. The risk of ipsilateral stroke was also significantly reduced ($p= 0.045$) in patients with a carotid stenosis of 50-69% who received endarterectomy.

In the ECST trial, the risk of any death or stroke after 3 years was 12.3% for patients with a stenosis greater than 80% in the surgical group and 21.9% in the group of patients treated with medical therapy only. This led to a significant benefit of 11.6% after 3 years.

The Asymptomatic carotid Artherosclerosis Study (ACAS) and the Asymptomatic Carotid Surgery Trial (ACST) trials have shown that endarterectomy is also beneficial in asymptomatic carotid stenoses [32, 33]. .

In the ACAS trial, patients with an asymptomatic carotid stenosis of more than 60% were included. The trial did not reveal any benefit of surgery in preventing major stroke during follow-up (stroke rate 3.4% vs 6.02% in medical group, N.S.). However, by considering minor and major strokes together, a beneficial effect of carotid endarterectomy could be evidenced (5.9% stroke reduction at 5 years: 5.1% ipsilateral stroke at 5 years after surgery vs 11% stroke at 5 years under medical treatment) [32].

The 5-year-results of the ACST Trial have shown an absolute risk reduction of major stroke at 5 years of 2.5% for patients aged under 75 years with asymptomatic carotid stenoses of 70% or more in duplex ultrasound [33].

6.2 Clinical Series of Carotid Stenting

A summary of carotid stenting results, containing the data of 12.392 procedures involving 11.243 patients from 53 centers, was published in 2003 by Wholey et al [34]. The incidence of complications occurring during the 30 days post implant were: TIAs (3.1%), minor strokes (2.1%), major strokes (1.2%), death (0.6%).

In 2001 Roubin et al. reported a series of 528 consecutive patients undergoing carotid stenting [35]. The major stroke rate was 1% (n=6) and the minor stroke rate was 4.8% (n=29). The overall stroke and death rate within 30 days was 7.4%.

In 2003 Cremonesi et al published a series of 442 consecutive patients treated with carotid stenting under embolic protection [36]. 1.1% of the patients experienced either a stroke or death within 30 days.

The German Society of Angiology and Radiology developed a prospective register for Carotid stenting. The results of the first 48 months from a total of 38 participating centers were published in 2004 [37]. A total of 3267 patients who suffered from carotid stenosis were treated by stent implantation. The procedure was successful in 98% of all interventions. The perioperative death rate was 0.6%, the major stroke rate was 1.2% and the rate of minor stroke was 1,3%.

Bosiers et al. published the ELOCAS registry in 2005 which retrospectively and prospectively collected data from four so-called “high-volume” Carotid stenting centers [38]. A total of 2172 patients were consecutively treated, 99.7% of the procedures were technically successful. The stroke/death rate was 4.1% after one year, 10.1% after three years, and 15.5% after five year follow-up.

The CAPTURE (Carotid Acculink/Accunet Post-Approval Trial to Uncover Unanticipated or Rare Events) registry was published in 2007 [39]. In this registry, 3500 patients who were considered to be of high operative risk and had a Carotid stenosis >50% (symptomatic) or >80% asymptomatic were included. The stroke/death/myocardial infarction rate was 6.3% after 30 days. The major stroke/death rate after 30 days was 2.9%.

The ARChER study was published by Gray et al in 2006 [40]. The study was designed as a three part multicenter study. In ARChER 1 the use of Acculink (Guidant) Carotid stents were evaluated. The following two studies (ARChER 2 and 3) also evaluated the adjuvant use of the Accunet (Guidant) embolic protection device. In total, 581 patients with high operative risk were included in 48 centers between the year 2000 and 2003. The combined primary endpoint of stroke/death/myocardial infarction was 8.3% after 30 days. The rate of ipsilateral stroke between the first month up to one year was 1.8%. The rate of restenosis was 2.2% up to one year follow up.

The CaRESS trial was a non-randomized, multicenter trial. It included 143 patients who were treated by Carotid stenting and 254 patients who were treated by Carotid Endarterectomy. No significant difference concerning the rate of stroke or death was detected after 30 days (2.1% stent, 3.6% surgery) or after one year follow up (10.0% stent, 13.6% surgery) [41].

6.3 Randomized Trials

The Carotid and Vertebral Transluminal Angioplasty Study (CAVATAS) was the first large study, in which carotid angioplasty was compared to CEA [23]. The incidence of MANEs was 10% in both the carotid angioplasty and carotid endarterectomy groups.

The SAPPHERE study compared carotid stenting with carotid endarterectomy using a randomized study design but also a registry study [24]. The incidence of MANEs was 4.5% for the stented patients and 6.6% for the CEA patients in the randomized study; this study enrolled high risk patients for carotid endarterectomy. In the registry study, where all patients could be entered, the incidence of MANEs was 6.9% in the stented patients.

The EVA-3S compared carotid stenting to endarterectomy in patients with a symptomatic carotid stenosis of at least 60% [42]. The entrance criteria for participating interventionalists were set very low. A participating interventionalist was required to have performed only 12 prior carotid stenting procedures. The 30-day incidence of stroke or death was lower in the group of patients in whom the procedure was performed under embolic protection compared to those patients in whom carotid stenting was performed without embolic protection (18/227, 7.9% versus 5/20, 25% respectively, $p=0.03$). For this reason the stenting arm of the trial without the use of an embolic protection device was stopped prematurely by the safety committee. The 30-day risk of any stroke or death was significantly higher after stenting (9.6%) than after endarterectomy (3.9%) which resulted in a relative risk of 2.5.

In the Stent-protected Percutaneous Angioplasty of the Carotid versus Endarterectomy trial (SPACE), patients with symptomatic carotid stenosis of more than 70% in duplex ultrasound or over 50% according to NASCET measurement were included [43]. The use of embolic protection was optional. Many interventional centers had problems fulfilling the entrance criteria (more than 25 carotid stent procedures previously performed), which meant many centers had only very limited experience in this procedure. The rate of death or ipsilateral ischemic stroke was 6.84% in the group of patients treated with stent implantation compared to 6.34% in the group of patients treated with endarterectomy. Although embolic protection devices have become standard in most centers around the world, 73% of all interventions were performed without them. Complications such as myocardial infarction, contralateral stroke, or cranial nerve palsy — some of them more common to or only occurring during surgery — were not considered by the study. The trial was a noninferiority rather than a superiority trial, with a noninferiority margin defined as less than 2.5%, based on an event rate of 5% - the one-sided p-value for non-inferiority was 0.09. The trial was halted prematurely due to low recruitment and lack of further funding after including only 1200 patients, while the analysis of more than 2500 patients would have been necessary in order to reach a statistical power of merely 80%. According to the investigators of the trial, the results failed to prove non-inferiority of carotid stenting compared to endarterectomy.

Overviewing all major randomized trials so far, the differences between surgery and stenting have been very small.

The CREST Trial (Carotid Revascularization Endarterectomy vs. Stenting Trial) has been recruiting patients since the year 2000. Preliminary results of the lead-in phase of the interventional part of the trial have been published in 2004. So far, the data shows a significantly higher risk of periprocedural complications with older age. The stroke/death rate in the patient cohort younger than 60 years was 1.6%, in the group of

patients between 60-69 years 1,3%, between 70-79 years of age 5,3% and 12,1% in patients 80 years of age or older. The significant results were independent of the patients' neurological status, grade of stenosis or the use of embolic protection systems [44].

Recently, the ICSS (International Carotid Stenting Study) and ACT 1 Trial (Asymptomatic Carotid Stenosis, Stenting Versus Endarterectomy Trial) have begun recruitment of eligible patients. Two other large randomized trials, the TACIT (Transatlantic Asymptomatic Carotid Intervention Trial) and ACST-2 trial (Asymptomatic Carotid Surgery Trial 2) have not yet begun recruiting. Their results may lead to new perspectives on the treatment success of asymptomatic lesions, such as on the benefit to patients' neurocognitive function.

6.4 Clinical Trials With Use of the Protégé Stent

The first study using the Protégé stent with the Spider embolic protection filter in high-risk patients was the CREATE feasibility trial [45]. High-risk features included age > 75 years, left ventricular ejection fraction < 35%, and restenosis after prior carotid endarterectomy. Procedural success was 100%. Thirty patients were included in the trial. In-hospital complications included severe vasovagal reactions in six patients (20%) and a popliteal embolus in one patient (3.3%), treated by successful embolectomy. During the first 30 days of follow up, two patients (6.6%) experienced minor neurological deficits, including transient expressive aphasia that resolved without therapy in one patient and homonymous hemianopsia due to contralateral posterior circulation stroke in one patient. Therefore, MANE rate was 6.6% at one month.

Between April 2004 and October 2004 a prospective non-randomized multicenter registry of 419 patients with severe carotid stenosis and high-risk features for carotid

endarterectomy was performed [46]. Carotid artery stenting was solely performed with the Protégé Stent and the Spider Embolic Protection System (ev3). The primary outcome was the combined incidence of major adverse cardiac and cerebrovascular events at 30 days after intervention, including death, stroke, and myocardial infarction. A secondary outcome was the technical success, defined as successful deployment of all devices, filter retrieval, and final diameter stenosis <50%. Technical success was achieved in 408 of 419 patients (97.4%). The primary end point was observed in 26 patients (6.2%), including death in 8 (1.9%), nonfatal stroke in 14 (3.3%), and nonfatal myocardial infarction in 4 (1%). Independent predictors of death or stroke at 30 days included duration of filter deployment, symptomatic carotid stenosis, and baseline renal insufficiency.

In the PROCAR study, four MANEs occurred from the procedure to the 1 month follow up. One major stroke occurred between the 1 month visit and the 6 month visit and was not related to either the device or the procedure. This patient died following the stroke. The incidence of MANEs at 1 month of 5.2% and 6.5% at 6 months in this study is comparable to what has been reported in other carotid stenting studies.

The PROCAR trial, as well as the CREATE feasibility trial and CREATE registry have shown a high technical success rate, with a high rate of correct placement of the stent in particular.

The PROCAR trial was designed to evaluate the safety and performance of the Protégé Stent in the treatment of common and/or internal carotid artery stenosis with adjunctive use of a filter embolic protection device. Investigators were free to choose any distal embolic protection device. Although it was not an objective of the study, this result suggests a good match between the Protégé stent and the Spider filter device.

7 CONCLUSION

In conclusion, the use of the new Protégé Stent with a new stent release system in combination with an embolic protection device satisfies safety and performance criteria for the treatment of carotid artery stenosis and presents an acceptable risk to patients with an incidence of MANEs similar to other carotid stent and endarterectomy trials.

8 REFERENCES

1. AHA: Heart and Stroke Facts Statistical Supplement. New York: American Heart Association; 1994.p.12
2. Wolf PA, Kannel WB, Mc Gee PC (1986) Epidemiology of strokes in North America. In: Barnett HJM, Stein BM, Mohr JP, Yatsu FM (editors). Stroke: Pathology, Diagnosis and Management. Vol 1. Churchill Livingstone, S.1929.
3. Bogousslavsky J, Van MG, Regli F. The Lausanne Stroke Registry: analysis of 1,000 consecutive patients with first stroke. Stroke 1988;19:1083–92.
4. Foulkes MA, Wolf PA, Price TR, et al. The Stroke Data Bank: design, methods, and baseline characteristics. Stroke 1988;19:547–54
5. Kannel WN. Risk factors for atherosclerotic cardiovascular outcomes in different arterial territories. Cardiovasc Risk 1994; 1:333-9
6. Wilterdink JL, Easton JD. Vascular event rates in patients with atherosclerotic cerebrovascular disease. Arch Neurol 1992; 49:857-63
7. Criqui MH, Langer RD, Fronek A, et al. Mortality over a period of 10 years in patients with peripheral arterial disease. N Engl J Med 1992; 326:381-6

8. Biasi G, Froio A, Diethrich E, et al. Carotid Plaque Echolucency Increases the Risk of Stroke in Carotid Stenting: The Imaging in Carotid Angioplasty and Risk of Stroke (ICAROS) Study. *Circulation*. 2004; 110:756-762.
9. Heuser RR, editor. *Peripheral vascular stenting for cardiologists*. Martin Dunitz Ltd London, 67-117,1999
10. DeBakey MH. Carotid endarterectomy revisited. *J Endovasc Surg* 1996;3:4
11. Eastcott HHG, Pickering GW, Rob CG. Reconstruction of internal carotid artery in a patient with intermittent attacks of hemiplegia. *Lancet* 1954;2:1-121
12. Naylor AR, Bolia A, Abbott RJ, Pye IF, Smith J, Lennard N, Lloyd AJ, London NJ, Bell PR. Randomized study of carotid angioplasty and stenting versus carotid endarterectomy: a stopped trial. *J Vasc Surg*. 1998;28(2):326-34.
13. Brooks WH, McClure RR, Jones MR, Coleman TC, Breathitt L. Carotid angioplasty and stenting versus carotid endarterectomy: randomized trial in a community hospital. *J Am Coll Cardiol* 2001; 38(6):1589-1595.
14. Brooks WH, McClure RR, Jones MR, Coleman TL, Breathitt L. Carotid angioplasty and stenting versus carotid endarterectomy for treatment of asymptomatic carotid stenosis: a randomized trial in a community hospital. *Neurosurgery*. 2004;54(2):318-24.

15. The EC/IC Bypass Study Group. Failure of extracranial-intracranial arterial bypass to reduce the risk of ischemic stroke. Results of an international randomized trial. *N Engl J Med* 1985;313:1191–200.
16. Chambers BR, Norris JW. The case against surgery for asymptomatic carotid stenosis. *Stroke* 1984;15:964 –7.
17. Barnett HJ, Taylor DW, Eliasziw M, et al. Benefit of carotid endarterectomy in patients with symptomatic moderate or severe stenosis. North American Symptomatic Carotid Endarterectomy Trial Collaborators. *N Engl J Med* 1998 Nov 12;339(20):1415-25
18. North American Symptomatic Carotid Endarterectomy Trial Collaborators. Beneficial effect of carotid endarterectomy in symptomatic patients with high grade carotid stenosis. *N Engl J Med* 1991;32:445-53
19. Paciaroni M, Eliasziw M, Kappelle LJ, et al. Medical complications associated with carotid endarterectomy. NASCET Trial. *Stroke* 1999 Sep;30(9):1759-63
20. European Carotid Surgery Trialists' Collaborative Group. Randomised trial of endarterectomy for recently symptomatic carotid stenosis: final results of the MRC European Carotid Surgery Trial (ECST). *Lancet* 1998;351:1379-1387
21. Mathias K. Perkutane transluminale Katheterbehandlung supraaortaler Arterienobstruktionen. *Angio*. 1981;3:47-50.

22. Roubin SG, New G, Iyer SS, et al. Immediate and late clinical outcomes of carotid artery stenting in patients with symptomatic and asymptomatic carotid artery stenosis. A 5-year prospective analysis. *Circulation* 2001;103:532-7.
23. Endovascular versus surgical treatment in patients with carotid stenosis in the carotid and vertebral artery transluminal angioplasty study (CAVATAS): a randomised trial. *Lancet* 2001;357:1729-37.
24. Yadav JS, Wholey MH, Kuntz RE, et al. Protected carotid-artery stenting versus endarterectomy in high-risk patients (the SAPHIRE study). *N Engl J Med* 2004;351:1493-501
25. Al-Mubarak N, Roubin GS, Vitek JJ, et al. Effect of the distal-balloon protection system on microembolization during carotid stenting. *Circulation*. 2001;104:1999-2002.
26. Tübler T, Schlüter M, Dirsch O, et al. Balloon-protected carotid artery stenting: relationship of periprocedural neurological complications with the size of particulate debris. *Circulation*. 2001;104:2791-6.
27. Rabe K, Sugita J, Sievert H et al. Flow-Reversal Device for Cerebral Protection During Carotid Artery Stenting—Acute and Long-Term Results. *J Interv Cardiol*. 2006 Feb;19(1):55-62
28. Sievert H, Rabe K. Technique and Results of Carotid Stenting. In: Marco J, Biamino G editors *EURO PCR – European Paris Course of Revascularisation* May 2004 (15), pp. 336-53

29. Diethrich EB. Indications for carotid stenting; a preview of the potential derived from early clinical experience. *J Endovasc Surg* 1996;3:132-139
30. Mericle RA, Kim SH, Lanzino G, et al. Carotid artery angioplasty and use of stents in high-risk patients with contralateral occlusions. *J Neurosurg* 1999 Jun;90(6):1031-6
31. [Hopkins LN, Lanzino G, Mericle RA, et al. Carotid intervention: a neurosurgeon's perspective. *J Invasive Cardiol* 1998 June;10(5):311-4
32. Executive Committee for the asymptomatic carotid arteriosclerosis study. Endarterectomy for the asymptomatic carotid artery stenosis. *JAMA* 1995;273:1421-28
33. MRC Asymptomatic Carotid Surgery Trial (ACST) Collaborative Group. Prevention of disabling and fatal strokes by successful carotid endarterectomy in patients without recent neurological symptoms: randomised controlled trial. *Lancet* 2004; 363:1491-1502
34. Wholey MH, Al-Mubarek N. Updated Review of the Global Carotid Artery Stent Registry. *Catheter Cardiovasc Interv* 2003 Oct;60(2):259-66
35. Roubin GS, New G, Iyer SS, et al. Immediate and late clinical outcomes of carotid artery stenting in patients with symptomatic and asymptomatic carotid artery stenosis: a 5 year prospective analysis. *Circulation* 2001;103:532-37

36. Cremonesi A, Manetti R, Setacci F, et al. Protected carotid stenting: clinical advantages and complications of embolic protection devices in 442 consecutive patients. *Stroke*. 2003 Aug;34(8):1936-41
37. Theiss W, Hermanek P, Mathias K, et al. Pro-CAS: a prospective registry of carotid angioplasty and stenting. *Stroke*. 2004 Sep;35(9):2134-9.
38. Bosiers M, Peeters P, Deloose K, et al. Does carotid artery stenting work on the long run: 5-year results in high-volume centers (ELOCAS Registry). *J Cardiovasc Surg (Torino)*. 2005 Jun;46(3):241-7.
39. Gray WA, Yadav JS, Verta P, et al. The CAPTURE registry: predictors of outcomes in carotid artery stenting with embolic protection for high surgical risk patients in the early post-approval setting. *Catheter Cardiovasc Interv*. 2007 Dec 1;70(7):1025-33
40. Gray WA, Hopkins LN, Yadav S, et al. Protected carotid stenting in high-surgical-risk patients: the ARChER results. *J Vasc Surg*. 2006 Aug;44(2):258-68.
41. CaRESS Steering Committee Carotid Revascularization Using Endarterectomy or Stenting Systems (CaRESS) phase I clinical trial: 1-year results *J Vasc Surg* 2005;42:213-219
42. Mas JL, Chatellier G, Beyssen B et al. Endarterectomy versus stenting in patients with symptomatic severe carotid stenosis. *N Engl J Med*. 2006 Oct 19;355(16):1660-71

43. SPACE Collaborative Group. 30 day results from the SPACE trial of stent-protected angioplasty versus carotid endarterectomy in symptomatic patients: a randomised non-inferiority trial. *Lancet*. 2006 Oct 7;368(9543):1239-47
44. Hobson RW 2nd, Howard VJ, Roubin GS, et al. Carotid artery stenting is associated with increased complications in octogenarians: 30-day stroke and death rates in the CREST lead-in phase. *J Vasc Surg*. 2004 Dec;40(6):1106-11.
45. Safian RD, Bacharach JM, Ansel GM, et al. Carotid stenting with a new system for distal embolic protection and stenting in high-risk patients. *Catheter Cardiovasc Interv* 2004 Sept;63(1):1-6
46. Safian RD, Bresnahan JF, Jaff MR, et al. Protected carotid stenting in high-risk patients with severe carotid artery stenosis. *J Am Coll Cardiol*. 2006 Jun 20;47(12):2384-9

9 GLOSSAR

ACST	Asymptomatic Carotid Surgery Trial
CABG	Coronary Artery Bypass Graft
CAVATAS	Carotid and Vertebral Artery Transluminal Angioplasty Study
CE	<i>Conformité Européenne</i> , French for European Conformity
CEC	Clinical Event Committee
CT	Computerized Tomography
ESCT	European Carotid Surgery Trialists' Collaborative Group
Fr	French Catheter Scale: 3 French = 0.039 inch = 1 mm
MANE	Major Adverse Neurological Event
MI	Myocardial Infarction
NASCET	North American Symptomatic Carotid Endarterectomy Trial Collaborators
NIHSS	National Institutes of Health Stroke Scale
PTA	Percutaneous Transluminal Angioplasty
SAPPHIRE	Stenting and Angioplasty with Protection in Patients at High Risk for Endarterectomy Trial
TIA	Transient Ischemic Attack

10 ATTACHMENTS

10.1 Acknowledgements

I would like to express my gratitude to my doctoral adviser Professor Horst Sievert for giving me the unique chance to be part of his innovative research team at the CardioVascular Center Frankfurt, for showing me the multiplicity of a very challenging doctoral thesis and for guiding me through the very first steps of my scientific career. His encouragement to achieve distinguished analytical and medical skills over the years is an inestimable gift.

Furthermore, I would like to express my gratitude to the staff of the CardioVascular Center Frankfurt for their ongoing support and organizational skills, through which many day-to-day obstacles were easily resolved.

10.2 Scientific Achievements

10.2.1 Publications

BOSIERS M., PEETERS P., DELOOSE K., VERBIST J., SIEVERT H., SUGITA J., CASTRIOTA F., CREMONESI A. (2005) Does carotid artery stenting work on the long run: 5-year results in high-volume centers (ELOCAS Registry) J Cardiovasc Surg (Torino). 2005 Jun;46(3):241-7.

SUGITA J, MAJUNKE N, SIEVERT H (2006) Carotid Angioplasty, Closure of Patent Foramen Ovale and Transcatheter Closure of the Left Atrial Appendage for Prevention of Stroke. [Carotisangioplastie, Schirmchenverschluss des PFO und Katheterverschluss des Vorhofohres beim Schlaganfall]. Neurol Rehabil 2006; 12(2):93

SUGITA J, CREMONESI A, VAN ELST F, STOCKX L, MATHIAS k, SCHOFER J, SUTTORP mJ, REUL J, LOWENS S, SIEVERT H (2006) European Carotid PROCAR Trial: Prospective Multicenter Trial to Evaluate the Safety and Performance of the ev3 Protégé™ Stent in the Treatment of Carotid Artery Stenosis-1- and 6-Month Follow-Up. J Interv Cardiol. 2006 Jun;19(3):215-21.

FRANKE J, SIEVERT H (2007) Editorial: Embolic Protection. US Cardiovascular Disease 2007;Issue 1:77-8.

FRANKE J, SIEVERT H (2007), Editorial: Embolic Protection. Interventional Cardiology, European Cardiovascular Disease June 2007 Issue 1; 89-90.

FRANKE J, STAUBACH S, SIEVERT H (2007), Case History: Cryptogenic Stroke and PFO. Congenital Cardiology Today November 2007, Volume 5/ Issue 11; 10-13.

RABE K, **SUGITA J**, GOEDEL H, SIEVERT H (2006) Flow-Reversal Device for Cerebral Protection During Carotid Artery Stenting—Acute and Long-Term Results. *Journal of Interventional Cardiology* 19(1), 55-62.

10.2.2 Book Chapters

FRANKE J; REIMERS B; SIEVERT H (2007), Problem-Oriented Approaches in Interventional Cardiology, Edited by Antonio Colombo and Goran Stankovic, Chapter 16, Tips and Tricks for Endovascular Carotid Interventions, p191-201.

RABE K, **FRANKE J**, SIEVERT H (2008) Carotid Artery interventions. In: Nguyen TN, Colombo A, Hu D, Grines CL, Saito S, eds: *Practical Handbook of Advanced Interventional Cardiology*. Blackwell Publishing, New York, USA, p. 347-374

ROBERTSON G, SIEVERT H, FAROOQUI F, WUNDERLICH N, **FRANKE J** (2008) Endovascular Treatment of the renal artery – Tools & techniques for the treatment of renal artery stenosis. In: Amor M, Bergeron P, Cheshire N, Inglese L, Ischinger T, Mangialardi N, Mathias K, Raithel D, eds: *Lower limbs arteries & aortic branches interventions Combo*. p. 131-139

FRANKE J, ROBERTSON G, SIEVERT H, Common Carotid Artery: PTA Stenting. In: *Textbook of Peripheral Vascular Interventions [2nd ed]* Edited by Richard Heuser and Michel Henry, Chapter on In press.

FRANKE J, SIEVERT H, Technical Pearls in Carotid Artery Stenting, Edited by Nadim Al Mubarak. Lippincott Williams & Wilkins In press.

FRANKE J, SIEVERT H, Extrakranielle Stenosen und Verschlussprozesse. In: Therapiehandbuch Gefäßmedizin, Edited by Cissarek, Kröger, Santosa, Zeller. ABW · Wissenschaftsverlag. In press.

FRANKE J, SIEVERT H, Interventional Treatment of Carotid Artery Disease. In: Cardiovascular Interventions in Clinical Practice, Edited by Haase J, Schaeffers H-J, Sievert H, Waksman R. Wiley-Blackwell Publishing, Oxford, England. In press.

FRANKE J, SIEVERT H, The complex patient with multi-vessel disease – Part 2: Complex Cases in Peripheral Vascular Interventions. In: Complex Cases in Peripheral Vascular Interventions, Edited by Schillinger M and Minar E. In press.

10.2.3 Awards/ Nominations

Uschi Tschabitscher Prize Tournament for Young Neurologists in Clinical Neurology at the 9th Congress of the European Federation of Neurological Societies 17.-21.Sept. 2005, Athens, Greece

Best of TCT Peripheral and Carotid Abstracts at the 17th Annual Transcatheter Cardiovascular Therapeutics Symposium 17.-21.Oct. 2005, Washington,DC, USA

10.2.4 Invited Lectures

SUGITA J, SIEVERT H (2004) Follow-up of the Patients from the 3rd ICCA Workshop in October 2003. 4th International Course on Carotid Angioplasty and other Cerebrovascular Interventions, 21.-23.10.2004, Frankfurt, Germany

SUGITA J, SIEVERT H (2005) Carotid Stenting – State of the Art. 5th Oriental Endovascular Therapy, Nanjing, China 09.-12.June 2005

SUGITA J, SIEVERT H (2005) A New Concept of Embolic Protection. 5th International Course on Carotid Angioplasty and other Cerebrovascular Interventions, 27.-29.10.2005, Frankfurt, Germany

SUGITA J, SIEVERT H (2005) Follow-up of the Patients from the 4th ICCA Workshop in October 2004. 5th International Course on Carotid Angioplasty and other Cerebrovascular Interventions, 27.-29.10.2005, Frankfurt, Germany

SUGITA J, SIEVERT H (2006) Embolic Protection Devices: What is Available? Leipzig Interventional Course 2006, Leipzig, 26.-28.January 2006

FRANKE J, SIEVERT H (2006) Follow-up of the Patients from the 5th ICCA Workshop in October 2005. 6 th International Course on Carotid Angioplasty and other Cerebrovascular Interventions (ICCA) 2006, 23.-25. Nov. 2006, Frankfurt, Germany

FRANKE J, BAUER C, GHASEMZADEH-ASL S, SIEVERT H (2006) Distal Occlusion With Flushing and Aspiration: The Kensey Nash Device. 6th International Course on Carotid Angioplasty (ICCA) 2006, 23.-25. Nov. 2006, Frankfurt, Germany

FRANKE J, SIEVERT H (2007) Interventional Therapy of Carotid Stenosis [Interventionelle Therapie der Carotis Stenose]. Aktueller Stand der Gefäßintervention 2007, Coburg, Germany 02.-03. February 2007

FRANKE J, SIEVERT H (2007) Carotid Stenting Complications – How to Predict, Avoid and Treat. 3rd International Symposium for Prevention of Cardiovascular Diseases on Imaging, Management & Clinical Research, Krakow, Poland, May 14-16, 2007

FRANKE J, SIEVERT H (2007) Case with the FiberNet Filter Device. Multidisciplinary European Endovascular Therapy 2007, Cannes, France 13.-17. June 2007

FRANKE J, SIEVERT H, BAUER C, WOERNER V, WUNDERLICH N, MATHIAS K, SCHOFER J (2007) Embolic Protection During Carotid Stenting With the New Fibernet Device. 13th World Congress on Heart, July 28-31, 2007, Vancouver, BC, Canada

FRANKE J, SIEVERT H, (2007) Carotid Stenting: What is new in Embolic Protection? 7th International Congress on Coronary Heart Disease, October 7-10, 2007, Venice, Italy

FRANKE J, SIEVERT H (2007) Follow-up of the Patients from the 6th ICCA Workshop in November 2005. 7 th International Course on Carotid Angioplasty and other Cerebrovascular Interventions (ICCA) 2007, 28.Nov. – 1.Dec. 2007, Frankfurt, Germany

FRANKE J, SIEVERT H (2007) My Nightmare in the Cathlab: Management of Restenosis After Stenting a Totally Occluded Brachiocephalic Trunk. 7 th International Course on Carotid Angioplasty and other Cerebrovascular Interventions (ICCA) 2007, 28.Nov. – 1.Dec. 2007, Frankfurt, Germany

10.2.5 Scientific Presentations

SUGITA J, RABE K, GOEDEL H, LANG K, ROEMER A, HOFMANN I, MIDDELDORF T, SCHNEIDER P, SIEVERT H (2004) Restenoses after carotid stenting: incidence, diagnosis and treatment. 14th Meeting of the European Neurological Society 26-30 June 2004, Barcelona, Spain

SUGITA J, RABE K, GOEDEL H, LANG K, ROEMER A, HOFMANN I, MIDDELDORF T, SCHNEIDER P, SIEVERT H (2004) Embolic protection in carotid stenting with eccentric filters. 14th Meeting of the European Neurological Society 26-30 June 2004, Barcelona, Spain

SUGITA J, RABE K, GOEDEL H, LANG K, ROEMER A, HOFMANN I, MIDDELDORF T, OETJEN U, THOMALSKE C, SCHNEIDER P, SIEVERT H (2004) Carotid Stenting: Comparison of Acute and Long-term Results up to 10 Years in Patients with Asymptomatic and Symptomatic Stenoses. 16th Annual Transcatheter Cardiovascular Therapeutics Symposium 27.Sep.-1.Oct. 2004, Washington,DC, USA

SUGITA J, RABE K, GOEDEL H, LANG K, ROEMER A, HOFMANN I, MIDDELDORF T, OETJEN U, THOMALSKE C, SCHNEIDER P, SIEVERT H (2004) Stroke Prevention by Carotid Stent Implantation: Acute and Long-term Results up to 10 Years. 16th Annual Transcatheter Cardiovascular Therapeutics Symposium 27.Sep.-1.Oct. 2004, Washington, DC, USA

SUGITA J, RABE K, GOEDEL H, LANG K, ROEMER A, HOFMANN I, MIDDELDORF T, OETJEN U, THOMALSKE C, SCHNEIDER P, SIEVERT H (2004) Carotis Stentimplantation: Vergleich der akuten und langfristigen Ergebnisse bis zu 10 Jahren bei Patienten mit asymptomatischen und symptomatischen Stenosen. 28. Herbsttagung und 15. Jahrestagung der Arbeitsgruppen Herzschrittmacher und Arrhythmie der Deutschen Gesellschaft für Kardiologie- Herz- und Kreislaufforschung, 14.-16.10.2004, Hamburg, Germany

SUGITA J, SCHLUESSMANN E, RABE K, GOEDEL H, LANG K, ROEMER A, HOFMANN I, MIDDELDORF T, OETJEN U, THOMALSKE C, SCHNEIDER P, SIEVERT H (2005) Inzidenz von Restenose nach Carotis Stentimplantation: Langzeitergebnisse bis zu 11 Jahren. 71. Jahrestagung der Deutschen Gesellschaft für Kardiologie- Herz- und Kreislaufforschung, 31.03-02.04.2005, Mannheim, Germany

SUGITA J, SCHLUESSMANN E, RABE K, GOEDEL H, LANG K, ROEMER A, HOFMANN I, MIDDELDORF T, OETJEN U, THOMALSKE C, SCHNEIDER P, SIEVERT H (2005) Prevention of Disabling and Fatal Strokes – Acute Results and Long-term Follow-up of Carotid Stenting in Patients with Asymptomatic Carotid Stenosis: A Comparison of Two Different Age Groups. 57th American Academy of Neurology Annual Meeting, April 2005, Miami Beach, USA

SUGITA J, SCHLUESSMANN E, RABE LISSMANN-JENSEN H, ROEMER A, LANG K, HOFMANN I, MIDDELDORF T, SCHNEIDER P, OETJEN U, THOMALSKE C, SIEVERT H (2005) Prevention of Disabling and Fatal Strokes - Acute Outcome and Long-term Follow-up of Carotid Stenting in Patients with Asymptomatic Carotid Stenosis: A Comparison of Two Different Age Groups. 15th Meeting of the European Neurological Society 18.-22. June 2005, Vienna, Austria

SUGITA J, RABE K, SCHLUESSMANN E, GOEDEL H, LANG K, ROEMER A, HOFMANN I, MIDDELDORF T, OETJEN U, THOMALSKE C, SCHNEIDER P, SIEVERT H (2005) Prevention of Disabling and Fatal Strokes - Acute Results and Long-term Follow-up of Carotid Stenting in Patients with Asymptomatic Carotid Stenosis: A Comparison of Two Different Age Groups. European Society of Cardiology Congress 2005, Stockholm, Sweden 03.-07. Sept. 2005

SUGITA J, RABE K, SCHLUESSMANN E, GOEDEL H, LISSMANN-JENSEN H, ROEMER A, LANG K, HOFMANN I, MIDDELDORF T, OETJEN U, THOMALSKE C, SCHNEIDER P, SIEVERT H (2005) Re-stenosis after Carotid Stentimplantation: Long-term Results up to 11 Years. 9th Congress of the European Federation of Neurological Societies 17.-21.Sept. 2005, Athens, Greece

SUGITA J, RABE K, SCHLUESSMANN ROEMER A, LANG K, LISSMANN-JENSEN H, HOFMANN I, MIDDELDORF T, OETJEN U, THOMALSKE C, SCHNEIDER P, SIEVERT H (2005) Re-stenosis after Carotid Stentimplantation: Long-term Results up to 11 Years. [Inzidenz von Restenose nach Carotis Stentimplantation: Langzeitergebnisse bis zu 11 Jahren]. 78. Kongress der Deutschen Gesellschaft für Neurologie, Wiesbaden, 21.09-24.09.2005

SUGITA J, BOSIERS M, PEETERS P, DELOOSE K, VERBIST J, CASTRIOTA F; CREMONESI A, SIEVERT H (2005) Carotid Artery Stenting (CAS) in 2172 Patients: 5-year Results in High-Volume Centers (ELOCAS Registry). 17th Annual Transcatheter Cardiovascular Therapeutics Symposium 17.-21.Oct. 2005, Washington,DC, USA

SUGITA J, BOSIERS M, PEETERS P, DELOOSE K, VERBIST J, CASTRIOTA F; CREMONESI A, SIEVERT H (2005) Carotid Artery Stenting (CAS): 5-year Results

in High-Volume Centers (ELOCAS Registry). 18th World Congress of Neurology 5.-11.Nov. 2005, Sydney, Australia

SUGITA J, BOSIERS M, PEETERS P, DELOOSE K, VERBIST J, CASTRIOTA F; CREMONESI A, SIEVERT H (2005) ELOCAS Registry - 5-year Results of Carotid Stenting in High Volume Centers: A Comparison of Two Different Age Groups in Patients with Asymptomatic Carotid Stenosis. Scientific Sessions of the American Heart Association, 13-16. Nov. 2005, Dallas, USA

SUGITA J, BOSIERS M, PEETERS P, DELOOSE K, VERBIST J, CASTRIOTA F; CREMONESI A, SIEVERT H (2006) 5-year Results of Carotid Stenting in High-Volume Centers: A Comparison of 2 Different Age Groups in Patients with Asymptomatic Carotid Stenosis (ELOCAS Registry). International Stroke Conference 2006, 16.-18. Feb. 2006, Kissimmee, Florida, USA

SUGITA J, GHASEMZADEH-ASL S, SCHLUESSMANN E, RABE K, GOEDEL H, ROEMER A, LANG K, HOFMANN I, MIDDELDORF T, OETJEN U, THOMALSKE C, SCHNEIDER P, SIEVERT H (2006) Long-Term Results of Carotid Stent Implantation Up to 11-Years in Patients With Carotid Stenosis. American College of Cardiology 55th Annual Scientific 11.-14.March 2006, Atlanta, USA

SUGITA J, BOSIERS M, PEETERS P, DELOOSE K, VERBIST J, CASTRIOTA F; CREMONESI A, SIEVERT H (2006) ELOCAS Registry - 5-year Results of Carotid Stenting in High-Volume Centers in Patients With Asymptomatic Carotid Stenosis. American College of Cardiology 55th Annual Scientific 11.-14.March 2006, Atlanta, USA

SUGITA J, BOSIERS M, PEETERS P, DELOOSE K, VERBIST J, CASTRIOTA F, CREMONESI A, SIEVERT H (2006) ELOCAS Registry: Long-term Results of Carotid Stenting in 2172 Patients [ELOCAS Register: Langzeitergebnisse der Carotis Stentimplantation bei 2172 Patienten]. 72.Jahrestagung der Deutschen Gesellschaft für Kardiologie- Herz- und Kreislaufforschung, Mannheim, 20.04-22.04.2006

FRANKE J, GOEDEL H, WOERNER V, GHASEMZADEH-ASL S, BAUER C, WUNDERLICH N, SIEVERT H (2006) Comparison of Outcomes Between Different Concepts of Embolic Protection - Filters versus Distal Occlusion versus Proximal Occlusion Devices. 6th International Course on Carotid Angioplasty (ICCA) 2006, 23.-25. Nov. 2006, Frankfurt, Germany

FRANKE J, WOERNER V, BAUER C, GHASEMZADEH-ASL S, KOCH M, OETJEN U, THOMALSKE C, WUNDERLICH N, SIEVERT H (2007) Acute Outcome and Long-term Results of Carotid Stenting up to 11 Years: A Comparison of Diabetic and Non-diabetic Patients. 13th World Congress on Heart, July 28-31, 2007, Vancouver, BC, Canada

FRANKE J, BAUER C, WOERNER V, GHASEMZADEH-ASL S, KOCH M, OETJEN U, THOMALSKE C, WUNDERLICH N, SIEVERT H (2007) Acute Outcome and Long-term Follow up of Carotid Stenting in Male and Female Patients With Carotid Stenosis: Does Gender Have an Effect on the Result of Carotid Stenting? 13th World Congress on Heart, July 28-31, 2007, Vancouver, BC, Canada

FRANKE J, SIEVERT H (2007) Management of Restenosis After Stenting a Totally Occluded Brachiocephalic Trunk. 19th Annual Transcatheter Cardiovascular Therapeutics Symposium 20.-25.Oct. 2007, Washington, DC, USA

FRANKE J, SIEVERT H (2008) Comparison of the Captured Debris During Carotid Stenting Using the New FiberNet Device and Other Proximal and Distal Embolic Protection Devices. Leipzig Interventional Course 2008, Leipzig, 23.-26.January 2008

11 CURRICULUM VITAE

* 09. September 1980 in Los Gatos, USA

Nationalität

USA

Familienstand

Verheiratet, keine Kinder

Mädchenname

Sugita

Religion

Römisch Katholisch

Schule

1986-1991 Katholische Privatschule Sankt Joseph in Cupertino, USA

1991-1999 Georg-Büchner-Gymnasiums in Bad Vilbel

Studium

10/1999-10/2006 Studium der Humanmedizin an der Johann Wolfgang von Goethe Universität in Frankfurt

Praktisches Jahr im Markus Krankenhaus in Frankfurt und Neurologie der Universitätsklinik in Frankfurt

Abschlüsse

04/1999 Abitur

03/2002 Physikum

03/2003 1. Staatsexamen

09/2005 2. Staatsexamen

10/2006 3. Staatsexamen

Famulaturen im Studium

07/2002 Allgemeinärztliche Praxis Dr. Sulisty-Winarto in Dormagen

09/2002 Septische und Unfallchirurgie, Berufsgenossenschaftliche Unfallklinik, Frankfurt

03/2004 Plastische und Handchirurgie, Städt. Krankenhaus Hildesheim

08/2004 Allgemeinärztliche Praxis Dr. Sulisty-Winarto in Dormagen

Berufliche Erfahrung im Studium

1999-2003 Tutorin für Abiturvorbereitung bei „Die Lernhilfe“ in Schöneck

2002-2003 Studentische Aushilfe der HNO und Dermatologie Praxis am Goetheplatz, Dres. Sakar und Otterstede

2000-2006
und Studentische Aushilfe der Wirtschaftsprüfungs-, Steuer-
Beratungsgesellschaft Deloitte

2005-dato Wissenschaftliche Mitarbeit und Kongressorganisation
im CardioVasculären Centrum, Sankt Katharinen Frankfurt

Berufliche Erfahrung

1. Jan 2007-June 2008 Assistenzärztin der Inneren Medizin I (Kardiologie,
Angiologie) des Sankt Katharinen Krankenhauses,
Frankfurt

Juli 2008-dato Assistenzärztin/Wissenschaftliche Mitarbeiterin der
Inneren Medizin III (Kardiologie, Pulmonologie) der
Universitätsklinik Heidelberg

1. Mai 2007 bis dato Mitherausgeber von Cathlab Hotline,
„Herz“ Journal, Urban-Vogel Verlag

12 EHRENWÖRTLICHE ERKLÄRUNG

Ich erkläre, dass ich die dem Fachbereich Medizin der Johann Wolfgang Goethe-Universität Frankfurt am Main zur Promotionsprüfung eingereichte Dissertation mit dem Titel

“The Safety and Performance of the new Nitinol Stent in the Treatment of Carotid Artery Stenosis - One and Six Month Follow-up”

im CardioVasculären Centrum Frankfurt Sankt Katharinen unter Betreuung und Anleitung von Prof. Dr. med. H. Sievert ohne sonstige Hilfe selbst durchgeführt und bei der Abfassung der Arbeit keine anderen als die in der Dissertation angeführten Hilfsmittel benutzt habe.

Ich habe bisher an keiner in- oder ausländischen Universität ein Gesuch um Zulassung zur Promotion eingereicht.

Die vorliegende Arbeit wurde bisher nicht als Dissertation eingereicht. Teile der Arbeit wurden bereits im Journal of Interventional Cardiology im Juni 2006 veröffentlicht.

Literaturangabe:

SUGITA J, CREMONESI A, VAN ELST F, STOCKX L, MATHIAS K, SCHOFER J, SUTTORP J, REUL J, LOWENS S, SIEVERT H (2006) European Carotid PROCAR Trial: Prospective Multicenter Trial to Evaluate the Safety and Performance of the ev3 Protégé™ Stent in the Treatment of Carotid Artery Stenosis-1- and 6-Month Follow-Up. J Interv Cardiol. 2006 Jun;19(3):215-21.

Frankfurt am Main, den 26. August.2007

(Jennifer Franke)