

# Hepatitis C-associated B-cell non-Hodgkin lymphomas. Epidemiology, molecular signature and clinical management

Jan Peveling-Oberhag<sup>1,\*</sup>, Luca Arcaini<sup>2</sup>, Martin-Leo Hansmann<sup>3</sup>, Stefan Zeuzem<sup>1</sup>

<sup>1</sup>Department of Internal Medicine 1, J.W. Goethe-University Hospital, Frankfurt, Germany; <sup>2</sup>Department of Hematology Oncology, Fondazione IRCCS Policlinico San Matteo & Department of Molecular Medicine, University of Pavia, Pavia, Italy; <sup>3</sup>Senckenberg Institute of Pathology, University of Frankfurt, Frankfurt, Germany

## Summary

There is ample epidemiologic evidence for an association of chronic hepatitis C virus (HCV) infection with B-cell non-Hodgkin lymphoma (B-NHL). B-NHL subtypes most frequently associated with HCV are marginal zone lymphoma and diffuse large B-cell lymphoma. The most convincing evidence for a causal relationship between HCV infection and lymphoma development is the observation of B-NHL regression after HCV eradication by antiviral therapy (AVT). In fact, for indolent HCV-associated B-NHL, first-line AVT instead of standard immune-chemotherapy might be considered. Molecular mechanisms of HCV-NHL development are still poorly understood. Three general theories have emerged to understand the HCV-induced lymphomagenesis: (1) continuous external stimulation of lymphocyte receptors by viral antigens and consecutive proliferation; (2) HCV replication in B cells with oncogenic effect mediated by intracellular viral proteins; (3) permanent B-cell damage, e.g., mutation of tumor suppressor genes, caused by a transiently intracellular virus ("hit and run" theory). This review systematically summarizes the data on epidemiology, interventional studies, and molecular mechanisms of HCV-associated B-NHL.

© 2013 European Association for the Study of the Liver. Published by Elsevier B.V. All rights reserved.

## Introduction

Over 180 million people worldwide are chronically infected with the hepatitis C virus (HCV), a hepatotropic and potentially lymphotropic virus [1,2]. HCV infection frequently leads to chronic hepatitis and is a major cause for liver cirrhosis and its sequelae such as hepatocellular carcinoma (HCC) [3]. Hematological manifestations such as type II mixed cryoglobulinemia (MC) or B-cell non-Hodgkin lymphoma (B-NHL) are less common. A large body

of clinical data supports the association of HCV infection and B-NHL. Epidemiologic studies, therapeutic approaches, and experimental data gathered in the last two decades established not only the mere association of viral infection and tumor development, but suggest also a causal relationship; e.g., sequencing of the IgM heavy chain of patients with MC with and without B-NHL showed clonal B-cell expansion in 100% of HCV infected individuals in the peripheral blood [4] and, to some extent, in the liver [5]. The most compelling argument for a causal relationship between HCV and B-NHL is made by interventional studies demonstrating that a sustained virologic response (SVR) to antiviral treatment containing interferon alfa induced regression of HCV-associated lymphomas and a viral relapse after initial virologic response led to lymphoma recurrence [6,7]. The mechanisms by which HCV may contribute to lymphoma development are still poorly understood, but considerable data on the molecular signature of HCV associated B-NHLs (HCV-NHL) has been gathered.

## Epidemiology

Pozzato *et al.* [8] and Ferri *et al.* [9] were the first to describe the association of HCV and NHL. The initial interest to study this coincidence was driven by the known high prevalence of HCV in patients with MC.

Cryoglobulins are immunoglobulins (Igs) in the serum which precipitate at temperatures below 37 °C. Type II MC is characterized by a combination of monoclonal and polyclonal Igs with a monoclonal IgM component often directed against IgG (rheumatoid factor activity). HCV antigens (e.g., HCV core protein) and HCV RNA have been found enriched in the formed immune complexes [10]. Moreover, a very high prevalence of HCV (close to 100%) was found in type II MC patients [11]. While only a minority of the HCV positive population experiences symptomatic MC (e.g., MC-vasculitis), the prevalence of low level circulating cryoglobulins reaches up to 50% of the infected patients [12]. Epidemiologic studies on HCV-MC show large differences in the geographic distribution, with higher prevalence in Southern Europe compared with Northern Europe or USA. Notably, the presence of MC in HCV positive patients may increase the risk to develop NHL. An Italian multicenter study showed an over

Keywords: Hepatitis C; Lymphoma; Antiviral therapy; B-cell; Non-Hodgkin lymphoma.

Received 5 February 2013; received in revised form 16 March 2013; accepted 19 March 2013

\* Corresponding author. Address: Klinikum der J.W. Goethe-Universität, Theodor-Stern-Kai 7, D-60590 Frankfurt, Germany. Tel.: +49 69 6301 5008; fax: +49 69 6301 6448.

E-mail address: [jan.peveling-oberhag@kgu.de](mailto:jan.peveling-oberhag@kgu.de) (J. Peveling-Oberhag).



ELSEVIER

## Review

35-fold increased risk to develop NHL for HCV positive patients with symptomatic MC compared with the general population [13] and consecutively, approximately 8–10% of patients with HCV-MC progress to overt NHL. Even after HCV eradication, HCV-MC patients may remain at high risk to develop a B-NHL [14].

Compared to the high association rate of HCV infection with HCC, epidemiologic studies on the relationship between HCV and NHL show a rather moderate risk for lymphoma development (odds ratios between 2 and 3 on average). Especially in the early case-control studies conducted in the '90s, the strength of association greatly varies, with increased odds ratios (OR) in countries with high HCV prevalence, e.g., Italy, Egypt, Japan or southern US regions (prevalence >2%) and lower to no evident correlation in low prevalence countries such as Scandinavia, UK or northern US regions and Canada (prevalence 0.01–0.1%) [15]. In France, where HCV prevalence is intermediate (0.7–1%), no evidence for an excess in B-NHL prevalence could be shown [16]. In Europe, in particular, these data seem to reflect a known north-south slope of HCV prevalence. Different theories have been suggested to explain the geographic differences in the association of HCV with B-NHL: (1) a difference in the HCV carrier population with northern European countries depending highly on transmission via intravenous drug use (IVDA), while the south of Europe features a combination of older HCV positive patients with iatrogenic transmission and younger patients with history of IVDA. (2) A population with long-lasting infection in the south versus a population with more recent infection (e.g., via IVDA) in the low prevalence countries, thus not allowing full consequences of malignant transformation to become evident. (3) Known geographic differences in the HCV genotype distribution could play a role, as association of NHL development with certain HCV genotypes has been reported [17], although such correlation with genotypes was not shown for HCV-MC. (4) Studies in low-prevalence countries may not have included enough patients to adequately detect the association. Notably, several studies in low-prevalence countries nevertheless showed a significant association of HCV and B-NHL [18,19]. Efforts have been made to a systematic approach including several meta-analyses (Table 1). Although those studies all demonstrate significant association of HCV with B-NHL, there are varying results concerning the degree of increased NHL risk. The first systematic review and meta-analysis (including 5542 patients and 48 studies) was conducted in 2003 by Gisbert *et al.* [15], identifying a mean HCV infection prevalence within the NHL group of 13%. In 10 examined case-control studies, HCV prevalence in NHL vs. healthy controls was 17% vs. 1.5%, respectively (odds ratio 10.8). Another subsequent meta-analysis including data from 4049 NHL patients and 1,813,480 controls confirmed such a high strength of association (OR 5.7) [20]. An updated meta-analysis, which not only included case-control designs but also prospective cohort studies, found only moderately increased relative risk (RR) for lymphoma development in HCV positive patients [21]. Pooled RR for HCV-NHL was 2.5 (95% confidence interval [CI], 2.1–3.1) in case-control settings and 2.0 (95% CI, 1.8–2.2) in cohort studies. Recently, one of the largest cross-sectional studies from the US presented the analysis of ICD-9 discharge diagnoses for coincidence of HCV and NHL, incorporating a total of 1,055,912 patients' discharges. Again a significant association was demonstrated [22]. Throughout most meta-analyses, again, a high geographic heterogeneity becomes evident, with high OR in endemic countries

compared to low-prevalence regions. Indeed, the fraction of NHL attributable to HCV may be as high as 10% where HCV prevalence is high [21].

The question as to which subtypes of B-NHL are most closely associated to HCV still remains a matter of debate. The B-NHL subtypes most frequently described as being associated with HCV are marginal zone lymphomas (MZL), in particular splenic marginal zone lymphomas (SMZL), lymphoplasmacytic lymphoma (LPL), and diffuse large B-cell lymphoma (DLBCL) [23]. One meta-analysis did not find any subtype specific association [21], which may be attributable to a lack in the number of well-matched cases and controls. In a large European multicenter case-control study (Epilymph), DLBCL, MZL, and LPL were identified as most closely related to HCV infection, however, those subgroups consisted of relatively few cases [24]. Consecutively, a worldwide approach by the International Lymphoma Epidemiology Consortium (Interlymph) pooled data of seven previous surveys with matched cases and controls, demonstrating an overall OR of 1.78 (95% CI 1.4–2.3). In the subtype specific analysis, HCV infection was associated with MZL (OR 2.47), DLBCL (OR 2.24), and LPL (OR 2.57) [25]. Notably, one large multicenter case-control study from Italy found a higher OR for aggressive vs. indolent lymphoma types and speculated that previous data might have been biased by shorter overall survival rates of aggressive lymphomas [26].

### Interventional studies (antiviral therapy of HCV-B-NHL)

#### *Treatment of indolent HCV-NHL*

The association of HCV and B-NHL has been well established by aforementioned epidemiologic trials. But still, the most convincing evidence for a causal relationship between HCV infection and lymphoma development is the observation of B-NHL regression after HCV eradication by AVT. While of anecdotal character in the late '90s [27], the concept of antiviral treatment of HCV-NHL was firmly established by Hermine *et al.* in 2002, who successfully treated splenic lymphoma with villous lymphocytes with interferon (IFN)-alfa monotherapy [7]. Of nine treated patients, the investigators observed durable lymphoma remission in all patients (seven) with viral clearance under IFN-therapy. The two remaining HCV-NHL patients were consecutively treated with IFN and additional ribavirin (RBV), which led to viral as well as oncologic response. Importantly, six equally treated NHL patients without HCV infection showed no lymphoma response. Similar results were consecutively reproduced by the same group and others, as summarized in Table 2. Throughout these various works, lymphoma regression was closely correlated with a decline in viral load under AVT. In 2004, two studies reported lymphoma regression under AVT with combination therapy with IFN-alfa 2b and RBV, including mucosa-associated lymphoid tissue (MALT) lymphomas and SMZL, disseminated MZL as well as MALT lymphomas, respectively [28,29]. In both studies, complete hematologic response was closely correlated with virological response. With availability of pegylated (Peg)IFN also the standard treatment for HCV-NHL was adapted. Mazzaro *et al.* [30] compared pegylated and standard IFN in combination with RBV as first-line treatment in 18 HCV-NHL patients (16 of 18 LPL). Achievement of sustained virological response (SVR) was higher in the PegIFN group, which consecutively led to higher lymphoma remission

**Table 1. Summary of meta-analyses on HCV associated lymphoma.**

Meta-analyses	Year	Cases included	Included studies	OR/RR	Subtype association
Gisbert <i>et al.</i> , [15]*	2003	5542	48	OR 10.8 (7.4-16)	LPL
Matsuo <i>et al.</i> , [20]	2004	4049	23	OR 5.7 (4.09-7.96)	n.a.
Dal Maso <i>et al.</i> , [21]*	2006	4678	18/15	RR 2.5 (2.1-3.0)	none found
De Sanjose <i>et al.</i> , [25] <sup>§</sup>	2008	4784	7	OR 1.78 (1.4-2.3)	LPL, MZL, DLBCL

MZL, marginal zone lymphoma; LPL, lymphoplasmacytic lymphoma; DLBCL, diffuse large B-cell lymphoma; n.a., not available.

\*1st systematic review/meta-analysis.

\*Combination of case-control designs and prospective cohort studies.

<sup>§</sup>Pooled analysis (no meta-analysis).

rates, as SVR was associated with complete hematological response in all cases. While most of the studies focused on certain lymphoma entities, such as SMZL, also other indolent lymphoma subtypes have been successfully treated with AVT. Vallisa *et al.* [31] treated a variety of different indolent HCV-NHL (4 SMZL, 2 nodal MZL, 2 extranodal MALT-lymphomas, 4 LPL, 1 follicular lymphoma) with PegIFN and RBV. Of twelve assessable patients, seven achieved complete response and 4 partial response or stable disease, with only one patient experiencing disease progression. Again, lymphoma response (complete or partial, 75%) was significantly associated with decline in HCV viral load.

Of note, there is a study, which impressively demonstrates clinically that HCV likely triggers B-NHL. Paulli *et al.* [32] report on two patients with HCV-associated “lipoma-like” extranodal MZL treated with AVT. One patient showed virologic as well as hematologic response. The other patient, who received AVT as second-line therapy after relapse to prior conventional radio-chemotherapy, became HCV-RNA negative under AVT with concomitant complete lymphoma remission. Eight months after stopping AVT, the patient showed virologic relapse and another three months later also experienced lymphoma recurrence.

#### Treatment of aggressive HCV-NHL

In the management of HCV-associated aggressive B-NHL, mainly DLBCL, anthracycline-based chemotherapy coupled with rituximab (immuno-chemotherapy) remains the standard of care, while AVT, to date, does not play a significant role. Firstly, in the treatment of aggressive lymphoma subtypes, current antiviral regimens take too long to unfold intended antitumoral effects and secondly, highly malignant HCV-NHL are likely not exclusively antigen driven, but may have acquired additional oncogenic mutations. Nevertheless, there are few anecdotal reports that even showed successful AVT of DLBCL [33,34] or mantle cell lymphoma [35]. But even when treating aggressive HCV-NHL with standard immuno-chemotherapy, the underlying HCV infection still remains an issue to be considered. After remission of the lymphoma, it seems intuitive to eradicate HCV to prevent recurrence. Concurrent chemo and antiviral therapy is primarily hampered by hematological toxicity, but sequential immuno-chemotherapy followed by AVT has been used in two studies with promising results, leading to improved clinical outcome and prolonged disease free survival [36,37]. More and preferably prospective data, including the use of the emerging direct acting antiviral therapies for HCV, are needed at this point.

Another important clinical issue is the influence of chronic HCV infection on immuno-chemotherapy of HCV-NHL. Side-effect profile and efficacy of standard treatment seem to be negatively

affected by underlying viral disease [38,39]. Rituximab, as an important modern pillar of NHL therapy, may complicate treatment due to added hepatotoxicity and the issue of HCV reactivation or acceleration of viral liver inflammation. Rituximab therapy in HCV-associated MC has been demonstrated to be highly effective. Moreover, rituximab as monotherapy or in combination with PegIFN and RBV shows good safety and tolerability in treatment of MC, including a lack of viral flares or worsening of viremia [40–42]. In the treatment of overt HCV-associated lymphoma, application of anthracycline-based chemotherapy coupled with rituximab or concomitant immuno-chemotherapy and AVT shows a less beneficial safety profile, including hematological toxicity and hepatic flares. Different mechanisms have been proposed to explain higher rates of liver dysfunction and worse outcomes of standard chemotherapy in HCV-NHL [39,43]: (1) aggravation of preexisting liver damage due to HCV; (2) accelerated HCV replication and concomitant liver damage; (3) hepatitis due to post-treatment immune reactivation; and (4) increased drug toxicity from altered drug metabolism. While prophylactic HBV therapy during chemotherapy is standard of care, concomitant HCV treatment is not feasible, as mentioned above. Whether rituximab causes added negative impact on hepatotoxicity is still a matter of debate as only few systematic comparative data exist [44]. Treatment of HCV-NHL should be performed in an interdisciplinary approach with hepatologists and hematologists working hand in hand with close monitoring of liver function, as dose adjustment or stopping of treatment has shown to translate into worsening of overall survival [38]. For the future, there are high expectations towards the new standard of care in HCV therapy consisting of a triple therapy with a protease inhibitor (boceprevir or telaprevir) in addition to PegIFN and RBV [45,46]. As stated above, lymphoma response for treatment of HCV-NHL is closely related to achievement of SVR. Low rates of SVR under IFN and RBV therapy for HCV, especially in genotype 1 patients, have been one of the major hampering factors to choose AVT over standard immuno-chemotherapy in HCV-NHL. With improved SVR rates under the new standard of HCV therapy, also higher oncological response rates in HCV-NHL may be expected. Other advantages of the newly approved triple therapy as well as upcoming HCV-AVT are shortened durations of therapy [47]. This fact could be particularly interesting in the therapy of lymphoma patients who need prompt therapy (e.g., symptomatic disease or even aggressive HCV-NHL). Finally, the lack of severe IFN-associated hematotoxic effects in upcoming IFN-free HCV treatment regimens might be a great improvement in HCV-NHL therapy [48]. Abandonment of IFN would remove additional hematological toxicity on top of the one caused by the underlying lymphoma. In the combination of immuno-chemotherapy and AVT, a reduction of hematotoxicity could significantly improve treatment tolerability. Furthermore, there may still remain some doubt on

**Table 2. Studies of antiviral treatment in patients with HCV-associated lymphoma.**

	N° pts*	Antiviral treatment	Diagnosis	MC	Virologic response	NHL response
Patriarca <i>et al.</i> , [93]	1	IFN $\alpha$	LPL	-	1	1 CR
Casato <i>et al.</i> , [94]	1	IFN $\alpha$	MZL	1	HCV-RNA decrease	1 CR
Caramaschi <i>et al.</i> , [95]	1	IFN $\alpha$	MZL/MALT	-	n.a.	1 CR
Bauduer [96]	1	IFN $\alpha$	MZL/MALT	-	1	1 PR
Pitini <i>et al.</i> , [97]	2	IFN $\alpha$	SMZL	-	2	2 CR
Moccia <i>et al.</i> , [98]	3	IFN $\alpha$	SMZL	-	n.a.	2 CR
Hermine <i>et al.</i> , [7]	9	IFN $\alpha$	SLVL	6	7	7 CR
Kelaidi <i>et al.</i> , [28]	8	IFN $\alpha$ + RBV	SMZL (n = 4), MZL/MALT (n = 4)	8	5 SVR, 2 NSVR	5 CR
Tursi <i>et al.</i> , [29]	16	IFN $\alpha$ + RBV	MZL/MALT	-	11	16 CR
Saadoun <i>et al.</i> , [99]	18	IFN $\alpha$ (n = 8) IFN $\alpha$ + RBV (n = 10)	SLVL	18	14 CR, 4 NSVR	14 CR, 4 PR
Mazzaro <i>et al.</i> , [30]	18	IFN $\alpha$ + RBV (n = 8) PegIFN $\alpha$ + RBV (n = 10)	SLVL (n = 1), FL (n = 1), LPL (n = 16)	13	3 SVR, 4 NR, 1 NSVR 6 SVR, 2 NR, 2 NSVR	3 CR, 2 PR 6 CR, 2 PR
Oda <i>et al.</i> , [100]	1	PegIFN $\alpha$ + RBV	B-NHL (liver)	-	SVR	CR
Mauro <i>et al.</i> , [101]	1	PegIFN $\alpha$ + RBV	LPL	1	SVR	CR
Takahashi <i>et al.</i> , [102]	1	PegIFN $\alpha$ + RBV	NLPHL	-	SVR	CR
Svoboda <i>et al.</i> , [103]	1	PegIFN $\alpha$ + RBV	MZL/MALT	-	1	CR
Paulli <i>et al.</i> , [32]	2	PegIFN $\alpha$ + RBV	MZL/MALT	2	2 CR	1 CR, 1 PR
Pellicelli <i>et al.</i> , [34]	9	PegIFN $\alpha$ + RBV	SMZL (n = 3), MZL (n = 4), FL (n = 2)	4	7 SVR, 2 NSVR	5 CR, 2 PR
Vallisa <i>et al.</i> , [31]	13	PegIFN $\alpha$ + RBV	SMZL (n = 4), MZL/MALT (n = 4), FL (n = 1), LPL (n = 4)	5	7 SVR, 1 NSVR	7 CR, 2 PR

MC, type II mixed cryoglobulinemia; MZL, marginal zone lymphoma; SMZL, splenic marginal zone lymphoma; SLVL, splenic lymphoma with villous lymphocytes; FL, follicular lymphoma; LPL, lymphoplasmacytic lymphoma; NHL, non-Hodgkin lymphoma; NLPHL, nodular lymphocyte predominant Hodgkin lymphoma; IFN, interferon; RBV, ribavirin; CR, complete response; PR, partial response; SVR, sustained virologic response; NSVR, non-sustained virologic response; n.a., not available.

\*Patients with indolent lymphoma who actually received AVT.

the effects of AVT in HCV-NHL, considering the fact that IFN has also antilymphoproliferative properties. IFN-free regimen eventually able to achieve NHL regression could prove that virus suppression has indeed antilymphoma activity. Corresponding new studies are needed and again, the necessity of an interdisciplinary approach has to be emphasized, as these new antiviral drugs come with new side effects, potential drug-drug-interactions and require close monitoring.

#### Pathomechanisms and molecular signature of HCV-B-NHL

While hepatocytes are the main reservoir and replication space for the virus, HCV is also potentially lymphotropic [49]. Indeed, the lymphoid compartment is thought to be a “viral hideout” possibly allowing for persistence of the virus after seemingly successful treatment and selection of viral subtypes with altered fitness, e.g., towards AVT [50,51]. As mentioned above, there is robust clinical data to suggest a causal relationship between HCV and B-NHL development. However, knowledge of the molecular mechanism of HCV-associated lymphomagenesis is still limited. Three general theories have emerged to understand the HCV-induced transformation process: (1) Continuous external stimulation of lymphocyte receptors by viral antigens and consecutive proliferation; (2) HCV replication in B cells with oncogenic effects mediated by intracellular viral proteins; (3) permanent B-cell damage, e.g., mutation of tumor suppressor genes, caused by a transiently intracellular virus – the so called “hit and run” theory (Fig. 1).

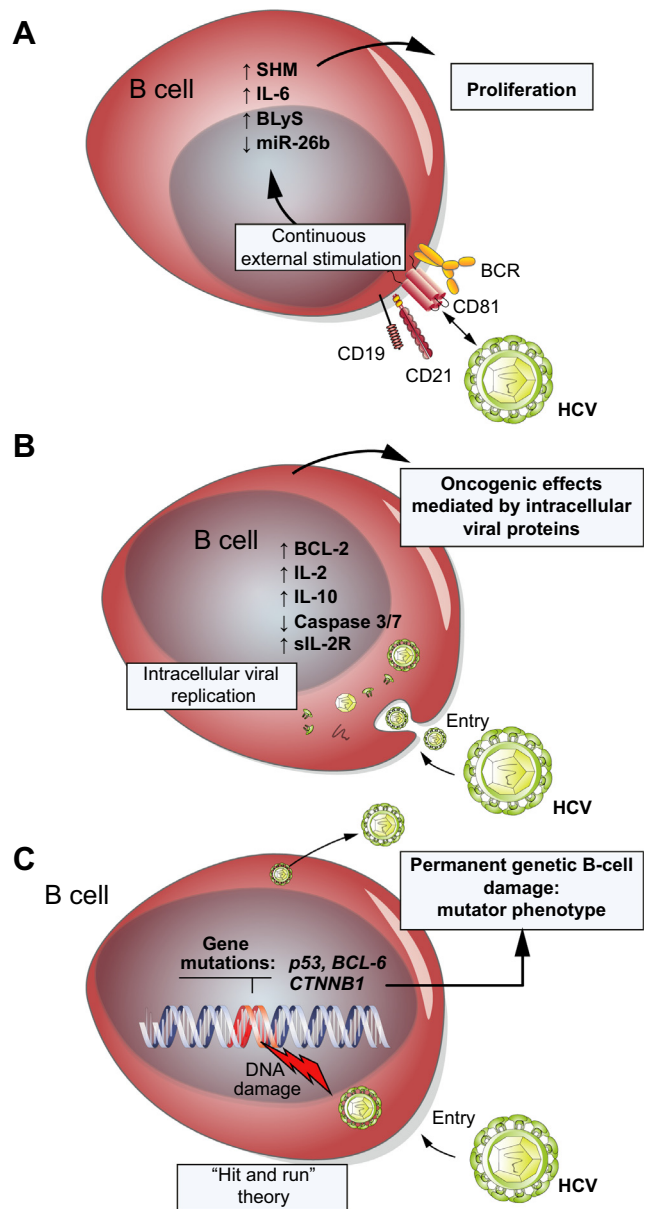
The concept of external antigenic stimulation of lymphocytes/lymphoma cells has a close similarity to *Helicobacter pylori*

induced MALT lymphoma development. The compatibility with clinical findings of lymphoma remission when the antigen is removed by AVT makes this theory appealing. Moreover, clinically the most frequently associated subtypes of HCV-NHL are of germinal center or post germinal center origin, with antigens posing as the primary proliferation trigger [52]. However, there is also experimental data supporting this theory. The HCV envelope protein E2 binds to CD81 expressed on B cells [53], a receptor that is upregulated in HCV infection and MC and that is positively correlated with viral load [54]. CD81 is known to form a co-stimulatory complex with CD19 and CD21 on B cells. Stimulation of CD19/CD21/CD81 and the B-cell receptor (BCR) leads to a decrease in B-cell activation threshold and may induce proliferation [55,56]. In fact, binding of HCV E2 together with an antibody against CD81 on naïve human B cells leads to activation of the JNK pathway and consecutive proliferation [57]. Furthermore, HCV-NHL were found to have restricted combinations of HLA class II genes. The DR5-DQ3 HLA combination was associated with HCV-NHL patients with MC and DR1-DQ-1 in MC negative HCV-NHL [58], while DR11 was associated with HCV-MC [59]. The possibility that HCV or parts of the virus might pose as the very antigen leading to B-cell proliferation and development of MC and B-NHL is supported by different studies. Marasca *et al.* sequenced clonal immunoglobulin variable regions from HCV-NHL patients. Three out of five HCV-associated nodal MZLs, showed the usage of the  $V_{H1-69}$  gene with similar CDR3, demonstrating highly biased and non-random use of the VH segments [60]. Other groups found restricted expression of  $V_H$  and  $V_L$  ( $V_{H1-69}$ ,  $V_{\kappa A27}$ ) genes as well as somatic hypermutation in patients with MC or HCV-NHL [61,62]. Therefore, it can be speculated on an exposure to a

common antigenic epitope, leading to selection and expansion of a B-cell clone, which might consecutively be the origin of overt HCV-NHL. Quinn *et al.* provided evidence that the mentioned common antigen may indeed be HCV [63]. The group cloned the BCR from two HCV positive DLBCL cases and tested the receptor ability to bind to HCV E2. The rescued immunoglobulin was shown to bind to the HCV-E2 glycoprotein in a manner identical to a *bona fide* human anti-E2 antibody. Moreover, immortalized B cells from HCV positive patients selected for binding to E2 have been shown to preferably express *V<sub>H</sub>1-69* genes [64]. Similarly, in a reported case of HCV-associated plasma cell leukemia, immunoblotting showed that the monoclonal IgG-kappa detected in the serum was directed against HCV core protein [65]. These data support the hypothesis of an indirect, antigen-driven lymphoma development caused by HCV proteins in analogy to *H. pylori* triggered MALT lymphoma. The clinical knowledge that HCV infected patients with MC are at higher risk to develop HCV-NHL [13] and the identification of oligoclonal cell populations in MC patients with consecutive development of NHL [66] lead to the theory that MC could be an intermediary step to the development of malignant transformation to HCV-NHL. Towards overt lymphoma there might be an additional event ("second hit") needed, possibly a genomic alteration, such as a mutation or the antiapoptotic Bcl-2 rearrangement, a translocation t(14;18), which has been found associated with MC and MALT lymphoma in patients with chronic HCV infection [67–70].

It is still unclear which signals or signaling pathways mediate HCV-NHL oncogenic transformation. The proinflammatory interleukin 6 (IL-6) with known strong stimulatory effect on B cells has been suggested to contribute to the development of cryoglobulinemia and B-NHL [71]. Furthermore, upregulation of the B-lymphocyte stimulator factor (BlyS) may play a role in MC and HCV-NHL [72–75]. Transgenic mice overexpressing BlyS develop B-cell hyperproliferation together with production of high levels of immunoglobulins, rheumatoid factor, and cryoglobulins [76]. BlyS is a potent co-activator of immunoglobulin production and activates NF-κB, JNK, and ERK pathways consecutively leading to B-cell survival and proliferation. Activation of the BlyS-receptor provides an accumulation of p52 protein deriving from p100, which activates NF-κB via the non-canonical pathway [77]. MicroRNAs (miRNAs) are short non-coding RNAs that bind to complementary sites of target mRNAs and can modulate gene expression by either translational repression or mRNA degradation. A reduced expression of miR-26b has been found in HCV positive versus HCV negative patients with SMZL [78]. The diminished expression of miR-26b, as seen in the HCV positive lymphomas, has demonstrated oncogenic potential *in vitro* and has been linked to a malignant tumor phenotype in hepatocellular carcinoma and lung carcinoma. One predicted target of miRNA26b is the NIMA-related kinase NEK6, which has a critical role in mitotic cell cycle progression and is upregulated in various human cancers [79].

The concept of direct oncogenic effects by HCV replication in B cells has been a matter of debate. HCV infection of lymphocytes, e.g., peripheral blood mononuclear cells (PBMC), is supported by various studies [51]; but active replication of HCV in human lymphocytes *in vivo*, with evidence of HCV-RNA negative strands, the viral replicative intermediates, has been demonstrated in some studies but not all [80,81]. In particular, active viral replication could not be demonstrated in HCV-NHL tissue [82]. One explanation for these contradictory findings could be that HCV



**Fig. 1. Different theories have been proposed to explain the mechanism of HCV induced lymphomagenesis.** (A) Continuous external stimulation of lymphocyte receptors (CD19, CD21, CD81, B-cell receptor [BCR]) by viral antigens and consecutive proliferation. Evidence of upregulation of oncogenic signals (IL-6, BlyS), downregulation of tumor suppressive signals (miR-26b), or increase of somatic hypermutation (SHM). (B) HCV replication inside B cells with oncogenic effects mediated by intracellular viral proteins. Induction of oncogenic signals (BCL-2, IL-2, IL-10, sIL-2R) and reduced sensitivity to Fas-induced apoptosis (decreased levels of caspases 3/7 and caspase 9). (C) Permanent genetic B-cell damage, e.g., mutation of tumor suppressor genes, (*p53*, *BCL-6*, beta-catenin) caused by a transiently intracellular virus – the so called "hit and run" theory.

replication is confined to certain rare subsets of B cells, e.g., CD5+ cells [83], or another event could be needed to make B cells permissive for HCV infection, such as EBV infection [84]. Moreover, one study found that peripheral blood B cells from patients with chronic HCV infection were indeed infected and simultaneously showed enhanced gene expression associated with B-NHL [85].

**Key Points**

- The risk to develop B-NHL is moderately increased in chronic HCV (RR 2-3) and the molecular mechanisms of HCV-NHL development are still poorly understood
- First-line AVT for indolent HCV-NHL may be a viable option while aggressive HCV-NHL should primarily be subject to standard immune-chemotherapy
- Systemic chemotherapy of HCV-NHL should be accompanied by close monitoring of hepatic function and an interdisciplinary collaboration between hematologists and hepatologists is essential for optimal treatment of HCV-NHL
- Post-remission HCV eradication after successful immuno-chemotherapy of DLBCL might be considered to prevent recurrence
- Inclusion of HCV-NHL patients in prospective studies is encouraged, as the number of systematic studies is still limited. New studies are needed to gauge the efficacy of triple antiviral therapy and upcoming IFN-free regimens in HCV-NHL

*In vitro*, HCV replication in B cells has been impressively demonstrated by Sung *et al.* who established an HCV infected B-NHL cell line (SB cells), whose virions can infect primary human hepatocytes, PBMCs, and a B-cell line (Raji cells) *in vitro* [49]. Despite the fact that lymphotropic HCV replication may still be uncertain, there is ample evidence that intracellular virus proteins could contribute to oncogenic transformation. For instance, interferon regulatory factor-1-null (*irf-1*<sup>-/-</sup>) mice with inducible and persistent expression of HCV structural proteins (*irf-1*<sup>-/-</sup>/CN2 mice) show a high incidence of lymphomas and lymphoproliferative disorders [86]. In this model, overexpression of apoptosis-related proteins and aberrant cytokine production were the primary events found to induce lymphoproliferation. Another transgenic mouse expressing HCV core protein showed frequent development of follicular center cell type lymphoma (80% at >20 month of age), with HCV core mRNA detected in lymphoma tissue [87]. Another very interesting mouse model was established by Kasama *et al.* [88]. The Japanese group created HCV transgenic mice that expressed the full HCV genome in B cells (RzCD19Cre mice). Notably, RzCD19Cre mice developed DLBCL with a significantly higher frequency compared to their genetically identical counterpart without HCV expression (CD19Cre- or RzCD19 mice). A possible transforming mechanism could involve serum-soluble interleukin-2 receptor  $\alpha$ -subunit (sIL-2R $\alpha$ ), which was found in substantially elevated levels in RzCD19Cre mice [89].

As third concept of HCV-NHL development, a “hit and run” mechanism has been proposed to explain possible transforming B-cell damage without evidence of virus replication inside tumor cells. Machida *et al.* found HCV to induce a high mutation frequency of cellular genes (immunoglobulin heavy chain, Bcl-6, p53 and beta-catenin) *in vitro* by inducing double strand breaks and by activating error-prone polymerases and AID [90]. The authors suggested that HCV induces a mutator phenotype by causing alterations in proto-oncogenes and tumor suppressor genes, which consecutively lead to oncogenetic transformation of B cells, although the virus may have already left the cell. There remains

some doubt about the clinical applicability of these findings as others were not able to confirm these findings *in vivo* [91,92].

**Conclusions and perspectives**

Cumulative epidemiologic evidence supports the thesis that patients with chronic HCV infection are at increased risk to develop lymphoma. The strength of the association of HCV and B-NHL varies greatly with the geographic location. The molecular mechanisms of HCV-associated lymphomagenesis are still poorly understood. There are different hypothetical concepts of the transformational process deriving from studies *in vitro* and *in vivo*. These theories do not necessarily stand in competition with each other, but could be parallel pathways leading to HCV-NHL, as a combination of transforming events might well be needed to result in overt lymphoma. Bridging studies that connect concepts from functional experiments to the *in vivo* condition are needed. Interventional studies on treatment of HCV-NHL with AVT show promising rates of remission in indolent lymphoma subtypes. Findings of a close relation of virologic and lymphoma response raise hope that with high SVR rates of emerging new antiviral drugs, HCV-NHL therapy might improve further.

**Conflict of interest**

JPO, LA and MLH have no conflict of interest to declare.

SZ – Consultancies for Abbott, Achillion, AstraZeneca, BMS, Gilead, Idenix, Janssen, Merck, Novartis, Presidio, Roche, Santaris, Vertex.

**References**

- [1] Ghany MG, Strader DB, Thomas DL, Seeff LB. Diagnosis, management, and treatment of hepatitis C: an update. *Hepatology* 2009;49:1335–1374.
- [2] Durand T, Di Liberto G, Colman H, Cammas A, Boni S, Marcellin P, et al. Occult infection of peripheral B cells by hepatitis C variants which have low translational efficiency in cultured hepatocytes. *Gut* 2010;59:934–942.
- [3] Simonetti RG, Camma C, Fiorello F, Cottone M, Rapicetta M, Marino L, et al. Hepatitis C virus infection as a risk factor for hepatocellular carcinoma in patients with cirrhosis. A case-control study. *Ann Intern Med* 1992;116:97–102.
- [4] Franzin F, Efreinov DG, Pozzato G, Tulissi P, Batista F, Burrone OR. Clonal B-cell expansions in peripheral blood of HCV infected patients. *Br J Haematol* 1995;90:548–552.
- [5] Vallat L, Benhamou Y, Gutierrez M, Ghillani P, Hercher C, Thibault V, et al. Clonal B cell populations in the blood and liver of patients with chronic hepatitis C virus infection. *Arthritis Rheum* 2004;50:3668–3678.
- [6] Arcaini L, Bruno R. Hepatitis C virus infection and antiviral treatment in marginal zone lymphomas. *Curr Clin Pharmacol* 2010;5:74–81.
- [7] Hermine O, Lefrere F, Bronowicki JP, Mariette X, Jondeau K, Eclache-Saudreau V, et al. Regression of splenic lymphoma with villous lymphocytes after treatment of hepatitis C virus infection. *N Engl J Med* 2002;347:89–94.
- [8] Pozzato G, Mazzaro C, Crovatto M, Modolo ML, Ceselli S, Mazzi G, et al. Low-grade malignant lymphoma, hepatitis C virus infection, and mixed cryoglobulinemia. *Blood* 1994;84:3047–3053.
- [9] Ferri C, Caracciolo F, Zignego AL, La Civita L, Monti M, Longombardo G, et al. Hepatitis C virus infection in patients with non-Hodgkin's lymphoma. *Br J Haematol* 1994;88:392–394.
- [10] Agnello V, Zhang QX, Abel G, Knight GB. The association of hepatitis C virus infection with monoclonal rheumatoid factors bearing the WA cross-idiotype: implications for the etiopathogenesis and therapy of mixed cryoglobulinemia. *Clin Exp Rheumatol* 1995;13:S101–S104.

- [11] Agnello V, Chung RT, Kaplan LM. A role for hepatitis C virus infection in type II cryoglobulinemia. *N Engl J Med* 1992;327:1490-1495.
- [12] Ferri C, Zignego AL, Pileri SA. Cryoglobulins. *J Clin Pathol* 2002;55:4-13.
- [13] Monti G, Pioletti P, Saccardo F, Campanini M, Candela M, Cavallero G, et al. Incidence and characteristics of non-Hodgkin lymphomas in a multicenter case file of patients with hepatitis C virus-related symptomatic mixed cryoglobulinemias. *Arch Intern Med* 2005;165:101-105.
- [14] Landau DA, Saadoun D, Halfon P, Martinot-Peignoux M, Marcellin P, Fois E, et al. Relapse of hepatitis C virus-associated mixed cryoglobulinemia vasculitis in patients with sustained viral response. *Arthritis Rheum* 2008;58:604-611.
- [15] Gisbert JP, Garcia-Buey L, Pajares JM, Moreno-Otero R. Prevalence of hepatitis C virus infection in B-cell non-Hodgkin's lymphoma: systematic review and meta-analysis. *Gastroenterology* 2003;125:1723-1732.
- [16] Hausfater P, Cacoub P, Sterkers Y, Thibault V, Amoura Z, Nguyen L, et al. Hepatitis C virus infection and lymphoproliferative diseases: prospective study on 1,576 patients in France. *Am J Hematol* 2001;67:168-171.
- [17] Torres HA, Nevah MI, Barnett BJ, Mahale P, Kontoyiannis DP, Hassan MM, et al. Hepatitis C virus genotype distribution varies by underlying disease status among patients in the same geographic region: a retrospective multicenter study. *J Clin Virol* 2012;54:218-222.
- [18] Duberg AS, Nordstrom M, Torner A, Reichard O, Strauss R, Janzon R, et al. Non-Hodgkin's lymphoma and other nonhepatic malignancies in Swedish patients with hepatitis C virus infection. *Hepatology* 2005;41:652-659.
- [19] Morton LM, Engels EA, Holford TR, Leaderer B, Zhang Y, Zahm SH, et al. Hepatitis C virus and risk of non-Hodgkin lymphoma: a population-based case-control study among Connecticut women. *Cancer Epidemiol Biomarkers Prev* 2004;13:425-430.
- [20] Matsuo K, Kusano A, Sugumar A, Nakamura S, Tajima K, Mueller NE. Effect of hepatitis C virus infection on the risk of non-Hodgkin's lymphoma: a meta-analysis of epidemiological studies. *Cancer Sci* 2004;95:745-752.
- [21] Dal Maso L, Franceschi S. Hepatitis C virus and risk of lymphoma and other lymphoid neoplasms: a meta-analysis of epidemiologic studies. *Cancer Epidemiol Biomarkers Prev* 2006;15:2078-2085.
- [22] Moehlen M, Abbas A, Balart LA. Hepatitis B and C are associated with Non-Hodgkin Lymphoma: cross-sectional study of the National Inpatient Sample database. *Hepatology* 2012;56:631a-632a.
- [23] Libra M, Polesel J, Russo AE, De Re V, Cina D, Serraino D, et al. Extrahepatic disorders of HCV infection: a distinct entity of B-cell neoplasia? *Int J Oncol* 2010;36:1331-1340.
- [24] Nieters A, Kallinowski B, Brennan P, Ott M, Maynadie M, Benavente Y, et al. Hepatitis C and risk of lymphoma: results of the European multicenter case-control study EPILYMPH. *Gastroenterology* 2006;131:1879-1886.
- [25] de Sanjose S, Benavente Y, Vajdic CM, Engels EA, Morton LM, Bracci PM, et al. Hepatitis C and non-Hodgkin lymphoma among 4784 cases and 6269 controls from the International Lymphoma Epidemiology Consortium. *Clin Gastroenterol Hepatol* 2008;6:451-458.
- [26] Mele A, Pulsoni A, Bianco E, Musto P, Szklo A, Sanpaolo MG, et al. Hepatitis C virus and B-cell non-Hodgkin lymphomas: an Italian multicenter case-control study. *Blood* 2003;102:996-999.
- [27] Mazzaro C, Franzin F, Tullisi P, Pussini E, Crovatto M, Carniello GS, et al. Regression of monoclonal B-cell expansion in patients affected by mixed cryoglobulinemia responsive to alpha-interferon therapy. *Cancer* 1996;77:2604-2613.
- [28] Kelaidi C, Rollot F, Park S, Tulliez M, Christoforov B, Calmus Y, et al. Response to antiviral treatment in hepatitis C virus-associated marginal zone lymphomas. *Leukemia* 2004;18:1711-1716.
- [29] Tursi A, Brandimarte G, Torello M. Disappearance of gastric mucosa-associated lymphoid tissue in hepatitis C virus-positive patients after anti-hepatitis C virus therapy. *J Clin Gastroenterol* 2004;38:360-363.
- [30] Mazzaro C, De Re V, Spina M, Dal Maso L, Festini G, Comar C, et al. Pegylated-interferon plus ribavirin for HCV positive indolent non-Hodgkin lymphomas. *Br J Haematol* 2009;145:255-257.
- [31] Vallisa D, Bernuzzi P, Arcaini L, Sacchi S, Callea V, Marasca R, et al. Role of anti-hepatitis C virus (HCV) treatment in HCV-related, low-grade, B-cell, non-Hodgkin's lymphoma: a multicenter Italian experience. *J Clin Oncol* 2005;23:468-473.
- [32] Paulli M, Arcaini L, Lucioni M, Boveri E, Capello D, Passamonti F, et al. Subcutaneous 'lipoma-like' B-cell lymphoma associated with HCV infection: a new presentation of primary extranodal marginal zone B-cell lymphoma of MALT. *Ann Oncol* 2010;21:1189-1195.
- [33] Iannitto E, Ammatuna E, Tripodo C, Marino C, Calvaruso G, Florena AM, et al. Long-lasting remission of primary hepatic lymphoma and hepatitis C virus infection achieved by the alpha-interferon treatment. *Hematol J* 2004;5:530-533.
- [34] Pellicelli AM, Marignani M, Zoli V, Romano M, Morrone A, Nosotti L, et al. Hepatitis C virus-related B cell subtypes in non Hodgkin's lymphoma. *World J Hepatol* 2011;3:278-284.
- [35] Levine AM, Shimodaira S, Lai MM. Treatment of HCV-related mantle-cell lymphoma with ribavirin and pegylated interferon alfa. *N Engl J Med* 2003;349:2078-2079.
- [36] La Mura V, De Renzo A, Perna F, D'Agostino D, Masarone M, Romano M, et al. Antiviral therapy after complete response to chemotherapy could be efficacious in HCV positive non-Hodgkin's lymphoma. *J Hepatol* 2008;49:557-563.
- [37] Musto P, Dell'Olio M, La Sala A, Mantuano S, Cascavilla N. Diffuse B-large cell lymphomas (DBLCL) with hepatitis-C virus (HCV) infection: clinical outcome and preliminary results of a pilot study combining R-CHOP with antiviral therapy. *Blood* 2005;106:688a.
- [38] Arcaini L, Merli M, Passamonti F, Bruno R, Brusamolino E, Sacchi P, et al. Impact of treatment-related liver toxicity on the outcome of HCV positive non-Hodgkin's lymphomas. *Am J Hematol* 2010;85:46-50.
- [39] Besson C, Canioni D, Lepage E, Pol S, Morel P, Lederlin P, et al. Characteristics and outcome of diffuse large B-cell lymphoma in hepatitis C virus-positive patients in LNH 93 and LNH 98 Groupe d'Etude des Lymphomes de l'Adulte programs. *J Clin Oncol* 2006;24:953-960.
- [40] De Vita S, Quartuccio L, Isola M, Mazzaro C, Scaini P, Lenzi M, et al. A randomized controlled trial of rituximab for the treatment of severe cryoglobulinemic vasculitis. *Arthritis Rheum* 2012;64:843-853.
- [41] Saadoun D, Resche Rigon M, Sene D, Terrier B, Karras A, Perard L, et al. Rituximab plus Peg-interferon-alpha/ribavirin compared with Peg-interferon-alpha/ribavirin in hepatitis C-related mixed cryoglobulinemia. *Blood* 2010;116:326-334, quiz 504-325.
- [42] Dammacco F, Tucci FA, Lauletta G, Gatti P, De Re V, Conteduca V, et al. Pegylated interferon-alpha, ribavirin, and rituximab combined therapy of hepatitis C virus-related mixed cryoglobulinemia: a long-term study. *Blood* 2010;116:343-353.
- [43] Ennishi D, Maeda Y, Niitsu N, Kojima M, Izutsu K, Takizawa J, et al. Hepatic toxicity and prognosis in hepatitis C virus-infected patients with diffuse large B-cell lymphoma treated with rituximab-containing chemotherapy regimens: a Japanese multicenter analysis. *Blood* 2010;116:5119-5125.
- [44] Marignani M, Mangone M, Cox MC, Angeletti S, Veggia B, Ferrari A, et al. HCV positive status and hepatitis flares in patients with B-cell non-Hodgkin's lymphoma treated with rituximab-containing regimens. *Dig Liver Dis* 2011;43:139-142.
- [45] Hezode C, Forestier N, Dusheiko G, Ferenci P, Pol S, Goeser T, et al. Telaprevir and peginterferon with or without ribavirin for chronic HCV infection. *N Engl J Med* 2009;360:1839-1850.
- [46] Poordad F, McCone Jr J, Bacon BR, Bruno S, Manns MP, Sulkowski MS, et al. Boceprevir for untreated chronic HCV genotype 1 infection. *N Engl J Med* 2011;364:1195-1206.
- [47] Farnik H, Zeuzem S. New antiviral therapies in the management of HCV infection. *Antivir Ther* 2012;17:771-783.
- [48] Hofmann WP, Zeuzem S. Hepatitis C in 2011: a new standard of care and the race towards IFN-free therapy. *Nat Rev Gastroenterol Hepatol* 2012;9:67-68.
- [49] Sung VM, Shimodaira S, Doughty AL, Picchio GR, Can H, Yen TS, et al. Establishment of B-cell lymphoma cell lines persistently infected with hepatitis C virus in vivo and in vitro: the apoptotic effects of virus infection. *J Virol* 2003;77:2134-2146.
- [50] Conca P, Tarantino G. Hepatitis C virus lymphotropism and peculiar immunological phenotype: effects on natural history and antiviral therapy. *World J Gastroenterol* 2009;15:2305-2308.
- [51] Zignego AL, Giannini C, Monti M, Gagnani L. Hepatitis C virus lymphotropism: lessons from a decade of studies. *Dig Liver Dis* 2007;39:S38-S45.
- [52] De Re V, De Vita S, Marzotto A, Glohini A, Pivetta B, Gasparotto D, et al. Pre-malignant and malignant lymphoproliferations in an HCV infected type II mixed cryoglobulinemic patient are sequential phases of an antigen-driven pathological process. *Int J Cancer* 2000;87:211-216.
- [53] Pileri P, Umetsu Y, Campagnoli S, Galli G, Falugi F, Petracca R, et al. Binding of hepatitis C virus to CD81. *Science* 1998;282:938-941.
- [54] Zuckerman E, Slobodin G, Kessel A, Sabo E, Yeshurun D, Halas K, et al. Peripheral B-cell CD5 expansion and CD81 overexpression and their association with disease severity and autoimmune markers in chronic hepatitis C virus infection. *Clin Exp Immunol* 2002;128:353-358.
- [55] Carter RH, Fearon DT. CD19: lowering the threshold for antigen receptor stimulation of B lymphocytes. *Science* 1992;256:105-107.

## Review

- [56] Matsumoto AK, Martin DR, Carter RH, Klickstein LB, Ahearn JM, Fearon DT. Functional dissection of the CD21/CD19/TAPA-1/Leu-13 complex of B lymphocytes. *J Exp Med* 1993;178:1407–1417.
- [57] Rosa D, Saletti G, De Gregorio E, Zorat F, Comar C, D'Oro U, et al. Activation of naive B lymphocytes via CD81, a pathogenetic mechanism for hepatitis C virus-associated B lymphocyte disorders. *Proc Natl Acad Sci U S A* 2005;102:18544–18549.
- [58] De Re V, Caggiari L, Monti G, Libra M, Spina M, Dolcetti R, et al. HLA DR-DQ combination associated with the increased risk of developing human HCV positive non-Hodgkin's lymphoma is related to the type II mixed cryoglobulinemia. *Tissue Antigens* 2010;75:127–135.
- [59] Cacoub P, Renou C, Kerr G, Hue S, Rosenthal E, Cohen P, et al. Influence of HLA-DR phenotype on the risk of hepatitis C virus-associated mixed cryoglobulinemia. *Arthritis Rheum* 2001;44:2118–2124.
- [60] Marasca R, Vaccari P, Luppi M, Zucchini P, Castelli I, Barozzi P, et al. Immunoglobulin gene mutations and frequent use of VH1-69 and VH4-34 segments in hepatitis C virus-positive and hepatitis C virus-negative nodal marginal zone B-cell lymphoma. *Am J Pathol* 2001;159:253–261.
- [61] Allander T, Drakenberg K, Beyene A, Rosa D, Abrignani S, Houghton M, et al. Recombinant human monoclonal antibodies against different conformational epitopes of the E2 envelope glycoprotein of hepatitis C virus that inhibit its interaction with CD81. *J Gen Virol* 2000;81:2451–2459.
- [62] De Re V, De Vita S, Marzotto A, Rupolo M, Gloghini A, Pivetta B, et al. Sequence analysis of the immunoglobulin antigen receptor of hepatitis C virus-associated non-Hodgkin lymphomas suggests that the malignant cells are derived from the rheumatoid factor-producing cells that occur mainly in type II cryoglobulinemia. *Blood* 2000;96:3578–3584.
- [63] Quinn ER, Chan CH, Hadlock KG, Fong SK, Flint M, Levy S. The B-cell receptor of a hepatitis C virus (HCV)-associated non-Hodgkin lymphoma binds the viral E2 envelope protein, implicating HCV in lymphomagenesis. *Blood* 2001;98:3745–3749.
- [64] Chan CH, Hadlock KG, Fong SK, Levy S. V(H)1-69 gene is preferentially used by hepatitis C virus-associated B cell lymphomas and by normal B cells responding to the E2 viral antigen. *Blood* 2001;97:1023–1026.
- [65] Hermouet S, Corre I, Gassin M, Bigot-Corbel E, Sutton CA, Casey JW. Hepatitis C virus, human herpesvirus 8, and the development of plasma-cell leukemia. *N Engl J Med* 2003;348:178–179.
- [66] De Vita S, De Re V, Gasparotto D, Ballare M, Pivetta B, Ferraccioli G, et al. Oligoclonal non-neoplastic B cell expansion is the key feature of type II mixed cryoglobulinemia: clinical and molecular findings do not support a bone marrow pathologic diagnosis of indolent B cell lymphoma. *Arthritis Rheum* 2000;43:94–102.
- [67] Kitay-Cohen Y, Amiel A, Hilzenrat N, Buskila D, Ashur Y, Fejgin M, et al. Bcl-2 rearrangement in patients with chronic hepatitis C associated with essential mixed cryoglobulinemia type II. *Blood* 2000;96:2910–2912.
- [68] Libra M, Gloghini A, Malaponte G, Gangemi P, De Re V, Cacopardo B, et al. Association of t(14;18) translocation with HCV infection in gastrointestinal MALT lymphomas. *J Hepatol* 2008;49:170–174.
- [69] Zignego AL, Ferri C, Giannelli F, Giannini C, Caini P, Monti M, et al. Prevalence of bcl-2 rearrangement in patients with hepatitis C virus-related mixed cryoglobulinemia with or without B-cell lymphomas. *Ann Intern Med* 2002;137:571–580.
- [70] Zignego AL, Giannelli F, Marrochi ME, Mazzocca A, Ferri C, Giannini C, et al. T(14;18) translocation in chronic hepatitis C virus infection. *Hepatology* 2000;31:474–479.
- [71] Feldmann G, Nischalke HD, Nattermann J, Banas B, Berg T, Teschendorf C, et al. Induction of interleukin-6 by hepatitis C virus core protein in hepatitis C-associated mixed cryoglobulinemia and B-cell non-Hodgkin's lymphoma. *Clin Cancer Res* 2006;12:4491–4498.
- [72] Fabris M, Quartuccio L, Sacco S, De Marchi G, Pozzato G, Mazzaro C, et al. B-Lymphocyte stimulator (BLYS) up-regulation in mixed cryoglobulinemia syndrome and hepatitis-C virus infection. *Rheumatology (Oxford)* 2007;46:37–43.
- [73] Sene D, Limal N, Ghillani-Dalbin P, Saadoun D, Piette JC, Cacoub P. Hepatitis C virus-associated B-cell proliferation – the role of serum B lymphocyte stimulator (BLYS/BAFF). *Rheumatology (Oxford)* 2007;46:65–69.
- [74] Geri G, Terrier B, Semoun O, Saadoun D, Sene D, Charlotte F, et al. Surrogate markers of B cell non-Hodgkin's lymphoma in patients with hepatitis C virus-related cryoglobulinemia vasculitis. *Ann Rheum Dis* 2010;69:2177–2180.
- [75] Mackay F, Schneider P, Rennert P, Browning J. BAFF AND APRIL: a tutorial on B cell survival. *Ann Rev Immunol* 2003;21:231–264.
- [76] Batten M, Groom J, Cachero TG, Qian F, Schneider P, Tschoopp J, et al. BAFF mediates survival of peripheral immature B lymphocytes. *J Exp Med* 2000;192:1453–1466.
- [77] Basak S, Shih VF, Hoffmann A. Generation and activation of multiple dimeric transcription factors within the NF-kappaB signaling system. *Mol Cell Biol* 2008;28:3139–3150.
- [78] Peveling-Oberhag J, Crisman G, Schmidt A, Doring C, Lucioni M, Arcaini L, et al. Dysregulation of global microRNA expression in splenic marginal zone lymphoma and influence of chronic hepatitis C virus infection. *Leukemia* 2012;26:1654–1662.
- [79] Nassirpour R, Shao L, Flanagan P, Abrams T, Jallal B, Smeal T, et al. Nek6 mediates human cancer cell transformation and is a potential cancer therapeutic target. *Mol Cancer Res* 2010;8:717–728.
- [80] Lanford RE, Chavez D, Chisari FV, Sureau C. Lack of detection of negative-strand hepatitis C virus RNA in peripheral blood mononuclear cells and other extrahepatic tissues by the highly strand-specific rTth reverse transcriptase PCR. *J Virol* 1995;69:8079–8083.
- [81] Lerat H, Berby F, Trabaud MA, Vidalin O, Major M, Trepo C, et al. Specific detection of hepatitis C virus minus strand RNA in hematopoietic cells. *J Clin Invest* 1996;97:845–851.
- [82] Sansonno D, Lotesoriere C, Cornacchiolo V, Fanelli M, Gatti P, Iodice G, et al. Hepatitis C virus infection involves CD34(+) hematopoietic progenitor cells in hepatitis C virus chronic carriers. *Blood* 1998;92:3328–3337.
- [83] Curry MP, Golden-Mason L, Doherty DG, Deignan T, Norris S, Levy M, et al. Expansion of innate CD5pos B cells expressing high levels of CD81 in hepatitis C virus infected liver. *J Hepatol* 2003;38:642–650.
- [84] Sugawara Y, Makuuchi M, Kato N, Shimotohno K, Takada K. Enhancement of hepatitis C virus replication by Epstein-Barr virus-encoded nuclear antigen 1. *EMBO J* 1999;18:5755–5760.
- [85] Ito M, Murakami K, Suzuki T, Mochida K, Suzuki M, Ikebuchi K, et al. Enhanced expression of lymphomagenesis-related genes in peripheral blood B cells of chronic hepatitis C patients. *Clin Immunol* 2010;135:459–465.
- [86] Machida K, Tsukiyama-Kohara K, Sekiguchi S, Seike E, Tone S, Hayashi Y, et al. Hepatitis C virus and disrupted interferon signaling promote lymphoproliferation via type II CD95 and interleukins. *Gastroenterology* 2009;137:285–296.
- [87] Ishikawa T, Shibuya K, Yasui K, Mitamura K, Ueda S. Expression of hepatitis C virus core protein associated with malignant lymphoma in transgenic mice. *Comp Immunol Microbiol Infect Dis* 2003;26:115–124.
- [88] Kasama Y, Sekiguchi S, Saito M, Tanaka K, Satoh M, Kuwahara K, et al. Persistent expression of the full genome of hepatitis C virus in B cells induces spontaneous development of B-cell lymphomas in vivo. *Blood* 2010;116:4926–4933.
- [89] Tsukiyama-Kohara K, Sekiguchi S, Kasama Y, Salem NE, Machida K, Kohara M. Hepatitis C virus-related lymphomagenesis in a mouse model. *ISRN Hematol* 2011;2011:167501.
- [90] Machida K, Cheng KT, Sung VM, Shimodaira S, Lindsay KL, Levine AM, et al. Hepatitis C virus induces a mutator phenotype: enhanced mutations of immunoglobulin and protooncogenes. *Proc Natl Acad Sci U S A* 2004;101:4262–4267.
- [91] Hofmann WP, Fernandez B, Herrmann E, Welsch C, Mihm U, Kronenberger B, et al. Somatic hypermutation and mRNA expression levels of the BCL-6 gene in patients with hepatitis C virus-associated lymphoproliferative diseases. *J Viral Hepat* 2007;14:484–491.
- [92] Tucci FA, Broering R, Johansson P, Schlaak JF, Kuppers R. B cells in chronically hepatitis C virus-infected individuals lack a virus-induced mutation signature in the TP53, CTNBN1, and BCL6 genes. *J Virol* 2013;87:2956–2962.
- [93] Patriarca F, Silvestri F, Fanin R, Zaja F, Sperotto A, Baccarani M. Long-lasting complete remission of hepatitis C virus (HCV) infection and HCV-associated immunocytoma with alpha-interferon treatment. *Br J Haematol* 2001;112:370–372.
- [94] Casato M, Mecucci C, Agnello V, Fiorilli M, Knight GB, Matteucci C, et al. Regression of lymphoproliferative disorder after treatment for hepatitis C virus infection in a patient with partial trisomy 3, Bcl-2 overexpression, and type II cryoglobulinemia. *Blood* 2002;99:2259–2261.
- [95] Caramaschi P, Biasi D, Carletto A, Ambrosetti A, Mocella S, Randon M, et al. MALT lymphomas of the salivary glands. Review of the literature apropos of a case in a patient with hepatitis C virus infection. *Recenti Prog Med* 1999;90:585–591.
- [96] Bauduer F. MALT non-Hodgkin's lymphoma associated with hepatitis C virus infection treated by interferon alpha. *Am J Hematol* 1996;53:209.
- [97] Pitini V, Arrigo C, Righi M, Scaffidi M, Sturniolo G. Systematic screening for HCV infection should be performed in patients with splenic marginal zone lymphoma. *Br J Haematol* 2004;124:252–253.
- [98] Moccia F, Tognoni E, Boccaccio P. The relationship between splenic marginal zone B-cell lymphoma and chronic liver disease associated with hepatitis C virus infection. *Ann Ital Med Int* 1999;14:288–293.



- [99] Saadoun D, Suarez F, Lefrere F, Valensi F, Mariette X, Aouba A, et al. Splenic lymphoma with villous lymphocytes, associated with type II cryoglobulinemia and HCV infection: a new entity? *Blood* 2005;105:74–76.
- [100] Oda Y, Kou T, Watanabe M, Sakuma Y, Taguchi N, Kato Y, et al. Regression of B-cell lymphoma of the liver with hepatitis C virus infection after treatment with pegylated interferon-alpha and ribavirin. *Dig Dis Sci* 2010;55:1791–1793.
- [101] Mauro E, Pedata M, Ermacora A, Mazzaro C. An additional line of therapy with pegylated interferon and ribavirin after rituximab in a patient with hepatitis C virus-related mixed cryoglobulinaemia and indolent non-Hodgkin's lymphoma previously treated with interferon. *Blood Transfus* 2012;10:101–103.
- [102] Takahashi K, Nishida N, Kawabata H, Haga H, Chiba T. Regression of Hodgkin lymphoma in response to antiviral therapy for hepatitis C virus infection. *Intern Med* 2012;51:2745–2747.
- [103] Svoboda J, Andreadis C, Downs LH, Miller Jr WT, Tsai DE, Schuster SJ. Regression of advanced non-splenic marginal zone lymphoma after treatment of hepatitis C virus infection. *Leuk Lymphoma* 2005;46:1365–1368.