



Case report

A case of myocarditis after COVID-19 vaccination: incidental or consequential? ☆



Leona S. Alizadeh ^{a,b,c,*}, Vitali Koch ^{a,b}, Ibrahim Yel ^{a,b}, Leon D. Grünwald ^{a,b}, Daniel Mathies ^d, Simon Martin ^{a,b}, Thomas J. Vogl ^{a,b}, Dominic Rauschnig ^d, Christian Booz ^{a,b}

^a Department of Diagnostic and Interventional Radiology, University Hospital Frankfurt, Germany

^b Division of Experimental Imaging, Department of Diagnostic and Interventional Radiology, University Hospital Frankfurt, Germany

^c Department of Diagnostic and Interventional Radiology, Bundeswehrzentral Krankenhaus Koblenz, Koblenz, Germany

^d Department of Internal Medicine, Bundeswehrzentral Krankenhaus Koblenz, Koblenz, Germany

ARTICLE INFO

Keywords:

Myocarditis
Vaccination
COVID-19
MRI

ABSTRACT

Vaccination represents one of the fundamentals in the fight against SARS-CoV-2. Myocarditis has been reported as a rare but possible adverse consequence of different vaccines, and its clinical presentation can range from mild symptoms to acute heart failure. We report a case of a 29-year-old man who presented with fever and retrosternal pain after receiving SARS-CoV-2 vaccine. Cardiac magnetic resonance imaging and laboratory data revealed typical findings of acute myocarditis.

1. Introduction

Informed consent of the patient was obtained for the publication of this article. A 29-year-old male presented with fever and retrosternal pain to the emergency department after he had received a SARS-CoV-2-vaccination (Vaxzevria, Astra Zeneca) three days earlier. The patient had a medical history no known chronic illnesses or allergies and had not been using any medication. Vital signs were normal (blood pressure 125/85mmHg, heart rate 75bpm, respiratory rate 16/min, SpO₂ 99%). ECG showed ST-elevations of the posterolateral wall and depressions of the anterior wall (Figure 1, ECG leads II, III and aVF respectively V₁–V₃). In the initial laboratory testing (normal values in parenthesis) hscTroponin: 363pg (<14); CK-MB: 37U/l (<25) and nt-proBNP 347 pg/ml (<125) as well as CRP: 2,2 mg/dl (<0.50) were elevated. The remaining blood values including myoglobin were normal. Coronary heart disease was ruled out by an immediate invasive cardiac catheterization on the same day. Echocardiography showed a slightly impaired left ventricular ejection fraction (44%) without segmental wall motion abnormalities while other findings including B/M mode assessment as well as Colour Doppler, pulsed- and continuous-wave Doppler ultrasound and tissue Doppler examination revealed no structural changes or further functional disorders. The patient was transferred to a high care ward and a cardiac MRI was performed on the following day.

2. Findings of functional MRI

The magnetic resonance imaging (MRI) on the 5th day post Astra Zeneca vaccination was acquired as a multiparametric functional MRI using refocusing gradient echo technique “steady-state free-precession” cinematic MRI sequences (CINE) and morphologic T1 and T2-weighted (MORPHO) sequences after intra-venous application of 25 ml Dotarem in early and late contrast-enhanced phase. Motion corrected T1 and T2 mapping sequences were acquired. These sequences were used to analyze functional and volumetric information.

T1- and T2-weighted images as non-contrasted sequences and T1 after contrast agent injection. The sequences were acquired in short-axis transversal, 2-,3-,4- chamber view, as well as left ventricular outflow-tract view.

MRI-images (Figure 2A and B) showed normal morphology of atrium and ventricles as well as normal size of the left ventricular outflow tract. Physiological morphology of all valves without stenosis or insufficiency was present. Kinetic wall movement was not impaired. In T1-weighted sequences, diffuse spotty partial configurated lesions of the lateral ventricular wall were reported (Figure 2C and D). After intravenous application of contrast agent, delayed perfusion in these areas was present (late gadolinium enhancement [LGE]). Lateral ventricular wall edema was present in T2-weighted sequences. The left ventricular ejection

☆ This article is a part of the "Advanced Imaging in Cardiovascular Diseases" Special issue.

* Corresponding author.

E-mail address: leona.alizadeh@outlook.de (L.S. Alizadeh).

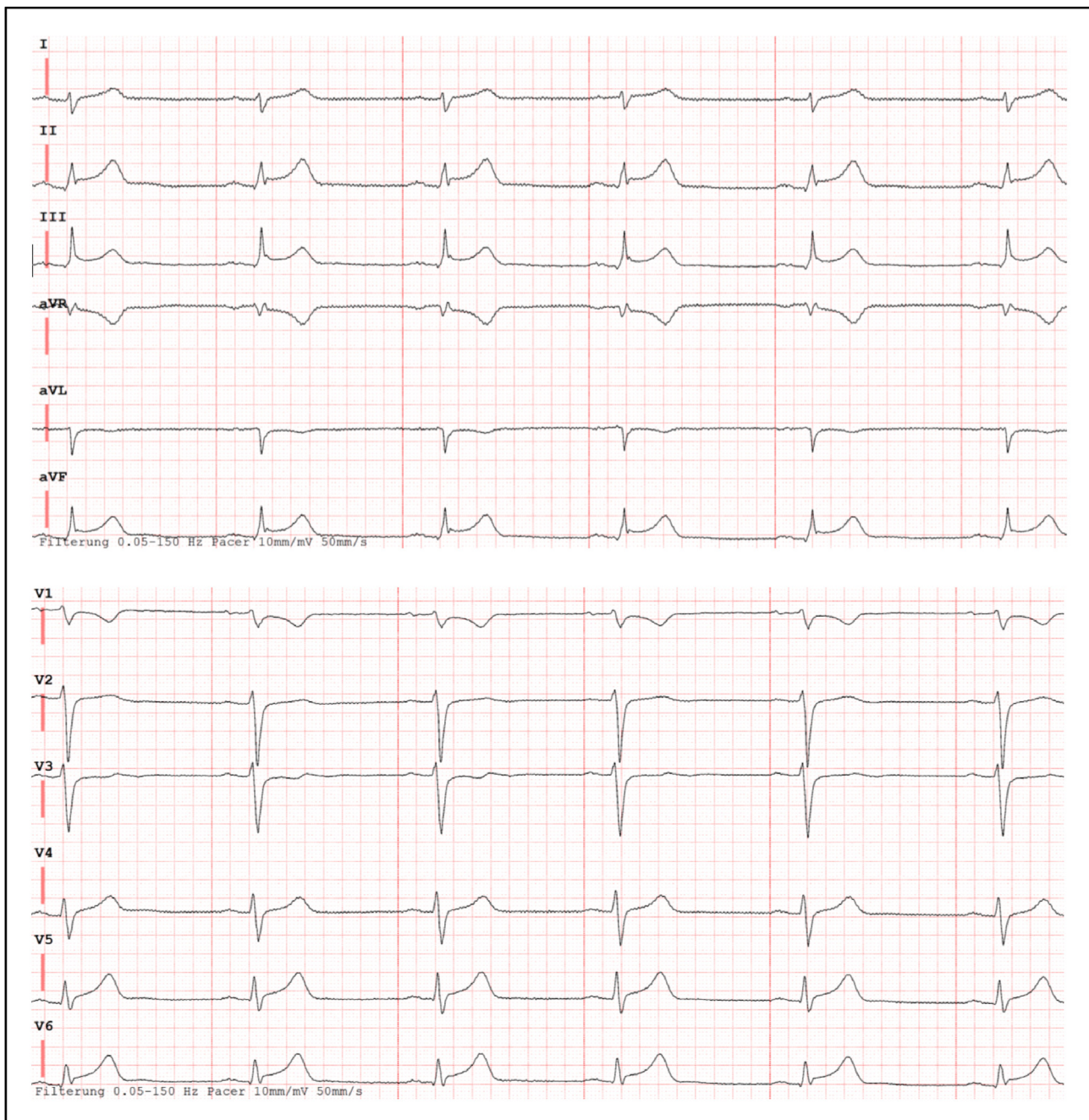


Figure 1. ECG on admission showing ST-elevations of the posterolateral wall and depressions of the anterior wall.

fraction (LVEF) was reported as slightly too high with 58%, with an end-systolic volume of 96 ml and 227 ml end-diastolic. No pericardial effusion was present. No signs of tumor, thrombosis, no atherosclerosis. During the examination, the heartbeat was 55 bpm. Based on the findings flurid myocarditis was diagnosed.

3. Clinical course

After MRI, the patient was treated with antiplatelet, ace-inhibitors and beta-blockers. PCR and serologic tests for viral infections (including influenza viruses, human cytomegalovirus, Epstein-Barr-Virus, adenoviridae, mykoplasma, toxoplasma gondii, borrelia burgdorferi and coxiella burnetii as well as repetitive testing for SARS-CoV 2 Virus) were negative, antibodies specific to SARS-CoV 2 were not tested. Symptoms improved as cardiac enzymes and inflammation markers decreased

during the further course. The patient suffered no relevant arrhythmias and was discharged after 24 h monitoring during as symptoms dissipated completely. Due to negative tests for viral infections and the spontaneous healing after few days, the vaccination represented the most likely cause. A checkup a week later showed a normal ECG and echocardiography, MRI was not repeated.

4. Discussion

Myocarditis is reported as being caused by SARS-CoV-2 but there have been a few cases reported after SARS-CoV-2 vaccination so far. Direct virus-induced cell damage to infected cardiomyocytes and T-cell-mediated cytotoxicity [1], as well as immunological processes in response to viral components of the vaccine or immunogenic adjuvants [2, 3], are suspected as a possible cause. These rare cases of myocarditis

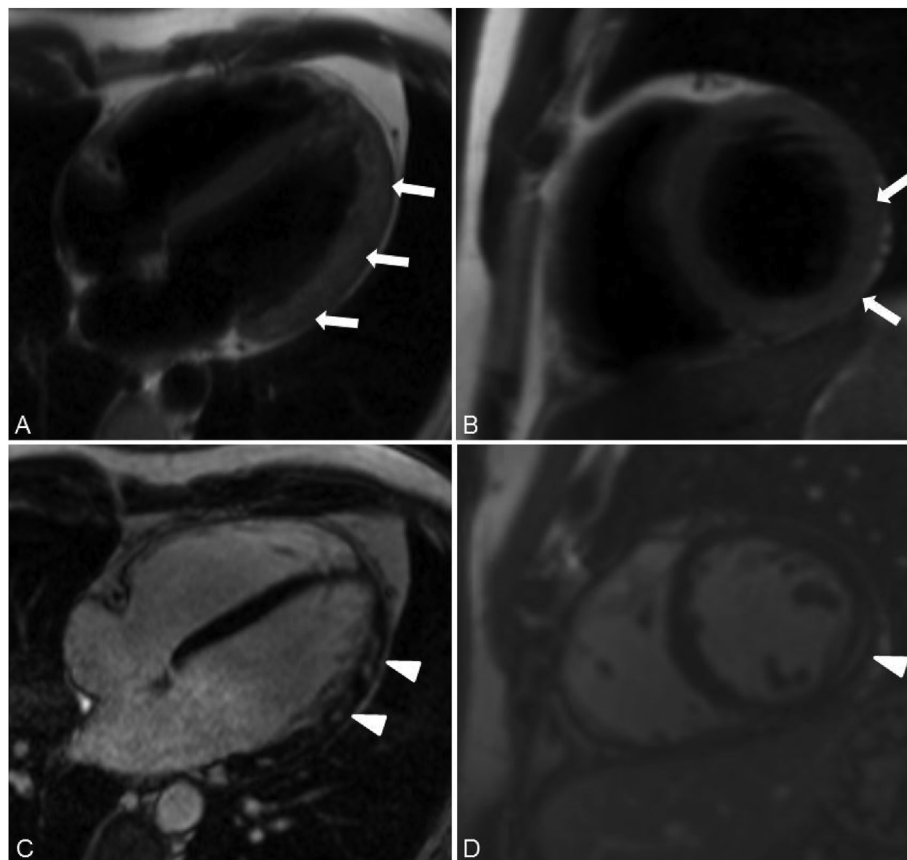


Figure 2. Cardiac MRI demonstrated lateral ventricular wall edema in T2-weighted images (A, B, arrows) with corresponding LGE in T1-weighted images (C, D, arrowheads) indicating acute myocarditis. In four-chamber view (Figure 2 A and B) spotty hyper hyperintensities corresponding to the lateral ventricular edema are confirming the diagnosis. Besides from these findings, indicating myocarditis, our cardiac MRI showed no other pathologies and physiological anatomy.

which were reported after SARS-CoV-2 vaccination mostly manifested over a short, self-limiting course without permanent impairment of cardiac function and predominantly affect young men with a mean age of 25 years [4, 5].

In this context, MRI is the diagnostic imaging modality of choice for patients with cardiac clinical symptoms, as it is non-invasive and causes no radiation exposition to young patients [6]. LGE, myocardial edema, and pericardial thickening as well as pathological findings in ECG and laboratory values confirm the diagnosis of myocarditis. In this context, the Lake Louis criteria are used to qualitatively assess cardiac MRI [7, 8]. Myocarditis is diagnosed when two of the following criteria are matched by the findings: myocardial edema in T2-WI; early Gadolinium enhancement indicating hyperemia; myocardial damage with non-ischemic morphology and corresponding LGE.

Myocarditis has been reported mainly after administration of mRNA vaccines [4, 5, 9]; only 8 cases have been reported to the German Paul Ehrlich Institute after vaccination with the adenovirus-based vector vaccine Vaxzevria (formerly known as COVID-19 vaccine AstraZeneca) with over 9 million doses of this vaccine recently administered in Germany [10]. The evaluation of foreign vaccination surveillance showed a rather negative association with the occurrence of myocarditis and vaccination with Vaxzevria or the COVID-19 vaccine Janssen [11].

From the view of pathophysiology, the literature suggests autoimmune myocarditis as the most likely cause for post-vaccination myocarditis [1, 4, 11]. This is explained by “molecular mimicry” as viral antigens are similar to the antigen-proteins on myocardial cells, thus an auto-immunological reaction causes lymphocytes, phagocytes, and granulocytes to attack the body's own cells. Secondly, a hypersensitivity reaction could have taken place after vaccination. In our case, the patient

only received a single dose of vaccine, making this overshooting reaction less likely compared to patients receiving two vaccinations (BioNTech, Moderna, etc) [2, 3, 11].

So far, myocarditis hasn't been confirmed as a specific complication after vaccination with a vector vaccine against SARS-CoV-2 but should be considered if there is a temporal coincidence and no other explanation. As our experience so far with a single patient may be an exception, there should be more cases collected and analyzed to prove this correlation between COVID-19 vaccination and myocarditis.

Declarations

Author contribution statement

All authors listed have significantly contributed to the investigation, development and writing of this article.

Funding statement

This research did not receive any specific grant from funding agencies in the public, commercial, or not-for-profit sectors.

Data availability statement

Data will be made available on request.

Declaration of interests statement

The authors declare no conflict of interest.

Additional information

No additional information is available for this paper.

References

- [1] M. Nassar, N. Nso, C. Gonzalez, S. Lakhdar, M. Alshamam, M. Elshafey, Y. Abdalazeem, A. Nyein, B. Punzalan, R.J. Durrance, M. Alfishawy, S. Bakshi, V. Rizzo, COVID-19 vaccine-induced myocarditis: case report with literature review, *Diabetes Metabol. Syndr.* 15 (2021) 102205.
- [2] M.P. Cheng, M.G. Kozoriz, A.A. Ahmadi, J. Kelsall, K. Paquette, J.M. Onrot, Post-vaccination myositis and myocarditis in a previously healthy male, *Allergy Asthma Clin. Immunol.* 12 (2016) 6.
- [3] Y.-J. Kim, J.-I. Bae, S.M. Ryoo, W.Y. Kim, Acute fulminant myocarditis following influenza vaccination requiring extracorporeal membrane oxygenation, *Acute Crit Care* 34 (2019) 165–169.
- [4] S. Pepe, A.T. Gregory, A.R. Denniss, Myocarditis, pericarditis and cardiomyopathy after COVID-19 vaccination, *Heart Lung Circ.* 30 (2021) 1425–1429.
- [5] N. Barda, N. Dagan, Y. Ben-Shlomo, E. Kepten, J. Waxman, R. Ohana, M.A. Hernán, M. Lipsitch, I. Kohane, D. Netzer, B.Y. Reis, R.D. Balicer, Safety of the BNT162b2 mRNA covid-19 vaccine in a nationwide setting, *N. Engl. J. Med.* 385 (2021) 1078–1090.
- [6] T. D'Angelo, A. Cattafi, M.L. Carerj, C. Booz, G. Ascenti, G. Cicero, A. Blandino, S. Mazziotti, Myocarditis after SARS-CoV-2 vaccination: a vaccine-induced reaction? *Can. J. Cardiol.* (2021). S0828282X21002865.
- [7] V.M. Ferreira, J. Schulz-Menger, G. Holmvang, C.M. Kramer, I. Carbone, U. Sechtem, I. Kindermann, M. Gutberlet, L.T. Cooper, P. Liu, M.G. Friedrich, Cardiovascular magnetic resonance in Nonischemic myocardial inflammation: expert recommendations, *J. Am. Coll. Cardiol.* 72 (24) (2018) 3158–3176. Dec 18.
- [8] M. Imbriaco, C. Nappi, M. Puglia, M. De Giorgi, S. Dell'Aversana, R. Cuocola, A. Ponsiglione, I. De Giorgi, M.V. Polito, M. Klain, F. Piscione, L. Pace, A. Cuocolo, Assessment of acute myocarditis by cardiac magnetic resonance imaging: comparison of qualitative and quantitative analysis methods, *J. Nucl. Cardiol.* 26 (3) (2019) 857–865. Jun.
- [9] H.M. Salah, J.L. Mehta, COVID-19 vaccine and myocarditis, *Am. J. Cardiol.* 157 (2021) 146.
- [10] Paul-Ehrlich-Institut, Bericht über Verdachtsfälle von Nebenwirkungen und Impfkomplicationen nach Impfung zum Schutz vor COVID-19 (Berichtszeitraum 27.12. bis 31.05.2021, 2021 (n.d.), https://www.pei.de/SharedDocs/Downloads/DE/newsroom/dossiers/sicherheitsberichte/sicherheitsbericht-27-12-bis-31-05-21.pdf?__blob=publicationFile&v=7. (Accessed 26 September 2021).
- [11] M. Kerneis, K. Bihan, J.-E. Salem, COVID-19 vaccines and myocarditis, *Arch Cardiovasc Dis* 114 (2021) 515–517.