



Novel surgical technique of sutureless artificial iris and intraocular lens scleral fixation using Yamane technique

Daniel Rudolf Muth, Dr. ^{a,*}, Siegfried Georg Priglinger, Prof. Dr. ^a, Mehdi Shajari, PD Dr. ^{a,b}, Thomas Christian Kreutzer, PD Dr. ^a, Wolfgang Johann Mayer, Prof. Dr. ^a

^a Department of Ophthalmology, University Hospital, LMU, Munich, Germany

^b Department of Ophthalmology, Goethe University, Frankfurt am Main, Germany

ARTICLE INFO

Keywords:

IOL scleral Fixation
Yamane
Artificial iris
Aphakia
Aniridia
Ocular trauma

ABSTRACT

Purpose: To describe a novel surgical technique of a combined implantation of an artificial iris and a scleral fixated intraocular lens (IOL) using flanged IOL haptics ("Yamane" technique).

Observations: The suturelessly implanted artificial iris-IOL-sandwich was stable with good functional as well as aesthetic results. However, our case showed a postoperative intraocular pressure rise.

Conclusions: The presented case demonstrates that a visual as well as cosmetical rehabilitation seems to be possible even after severe, penetrating ocular trauma with profound iris defects.

Importance: The sutureless IOL scleral fixation technique can also be used in combination with a sutureless artificial iris implantation. Further studies are needed to evaluate the long-term safety profile and rates of postoperative complications.

1. Introduction

Trauma eyes with aniridia and aphakia remain a surgical challenge. In the past, the results have been unrewarding for the patient and the surgeon alike, in terms of aesthetics and visual acuity (VA). With a portfolio of iris prostheses, intraocular lens (IOL) types and surgical techniques now available the options for cosmetical and visual rehabilitation have improved. Iris prosthesis were first implanted in the late 1950s by Peter Choyce in form of modified anterior chamber (AC) IOLs that had opaque colored haptics (available in ferrous brown, indocyanine green and cobalt blue).^{1,2} Forty-four years later, in 1994, *Sundmacher* et al. developed a polymethyl methacrylate (PMMA) IOL with a black diaphragm (black diaphragm IOL, BDI) produced by Morcher (Morcher GmbH, Stuttgart, Germany).³⁻⁵ Now, a colored version, the *Irismatch*, is available with 45 colors to choose from. In 2002, Ophtec (Ophtec BV, NR Groningen, The Netherlands) introduced the *Model 311* which was a PMMA IOL with a colored (black, blue, brown or green) opaque outer ring.⁶ It never achieved approval in the U.S. by the *Food and Drug Administration* (FDA).⁷ Recently, Ophtec launched their *Model CO/1* (sulcus fixation with/without optical correction) and *Model FO/1* (capsular bag fixation), produced by Reper (Reper-NN Ltd., Nizhny

Novgorod, Russia), which is a foldable acrylic iris-IOL available in a variety of 300 presets to choose from.^{6,8,9}

In 2007, Schmidt Intraocularlinsen (Schmidt Intraocularlinsen GmbH, Sankt Augustin, Germany) developed the first flexible iris prosthesis. The company was acquired by HumanOptics (HumanOptics AG, Erlangen, Germany).¹⁰ HumanOptics obtained *Conformité Européenne* (CE, since 2011¹¹) and FDA (since 2018¹¹) approval for the *Customflex Artificialiris* (hereafter referred to as AI) which allows a fully customized colored anterior surface. The HumanOptics AI can be implanted in parts or as a full iris replacement. It can be implanted alone or in combination with any IOL. Even the combination with a toric and a trifocal IOL have been described.^{12,13} The AI, however, is not recommended for implantation in phakic eyes due to the risk of premature cataract formation.^{14,15} An implantation into the anterior chamber (AC) is not recommended because of the high risk of secondary glaucoma.¹⁶ If necessary, an explantation of the AI is possible.¹⁶

2. Case report

A 17-year-old boy presented to our hospital with posttraumatic aphakia and aniridia on his left eye (OS) after trauma. The trauma had

* Corresponding author. Mathildenstr. 8, 80336, Munich, Germany.

E-mail addresses: dr-muth@t-online.de (D.R. Muth), siegfried.priglinger@med.uni-muenchen.de (S.G. Priglinger), mehdi.shajari@med.uni-muenchen.de (M. Shajari), thomas.kreutzer@med.uni-muenchen.de (T.C. Kreutzer), wolfgang.j.mayer@med.uni-muenchen.de (W.J. Mayer).

<https://doi.org/10.1016/j.ajoc.2022.101502>

Received 12 August 2021; Received in revised form 16 March 2022; Accepted 20 March 2022

Available online 25 March 2022

2451-9936/© 2022 The Authors. Published by Elsevier Inc. This is an open access article under the CC BY-NC-ND license (<http://creativecommons.org/licenses/by-nc-nd/4.0/>).

happened at the age of 10 years, in March 2014, and had been described as an injury with a human finger leading to a corneal perforation with rupture of the iris root and extraocular dislocation of parts of the phakic lens. A primary sclerocorneal wound closure had been performed at the day of the trauma. The following day a pars plana vitrectomy (ppv) with anterior chamber revision, complete phakic lens extraction and retinal endolaser coagulation due to retinal holes had been done. The patient presented now, almost seven years later in January 2021, with a stable aphakia and aniridia (Fig. 1a–c).

Despite the peripheral corneal scars, the patient had a corrected distance visual acuity (CDVA) with contact lenses of 0.00 logMAR as the optical zone was clear and intact (Table 1). However, the patient reported that he was heavily impaired by glare due to the aniridia and optical aberrations due to the peripheral corneal scars. The use of an iris-print contact lens was not tolerated.

As the patient had presented with stable retinal findings, normal electrophysiology (pattern electroretinogram, ERG) and color vision (Arden's color test) for years we decided on implantation of an artificial iris (AI) to reduce glare. Furthermore, an artificial iris would allow for cosmetic rehabilitation. Combined with a scleral fixated intraocular lens (IOL), the patient would be independent on contact lenses.

3. Methods

3.1. Surgical rationale

1. The goal was to correct the aniridia and aphakia in a single surgical session to keep the total surgical trauma for the eye as low as possible.
2. For aniridia correction, we decided to use a made-to-order HumanOptics *Customflex Artificialiris Fiber Free* (HumanOptics AG, Erlangen, Germany) as it allows the most customized reconstruction of an iris currently available. The fixed pupillary aperture of 3.35mm in diameter acts as a pinhole with positive effects on the contrast sensitivity.¹⁷
3. We wanted to attach the IOL for aphakia correction suturelessly to the AI by using the IOL haptics. This implied an implantation of the AI and the IOL together as a “sandwich”. Furthermore, we aimed for a sutureless scleral fixation of the AI-IOL-sandwich to avoid suture- and knot-associated complications. Therefore, we decided for a modified version of the IOL scleral fixation technique originally described by Yamane et al.,¹⁸ hereafter referred to as ‘Yamane technique’. We used the Kowa *AvanseePresetUV* 3-piece IOL (Kowa Company Ltd., Nagoya, Aichi, Japan) as we had already made good experience with this IOL type combined with the Yamane technique. As reported by Mayer et al. no biometry correction factor was used for the implanted AI-IOL-sandwich as the IOL, within the sandwich, is supposed to sit at the approximate same position as when implanted in the capsular bag.^{13,19}
4. Trimming of the AI to 10.5mm in diameter was done before hooking the IOL and before implantation to avoid chafing at the ciliary body and iris remnants and to prevent angle closure in case of an IOL tilt.

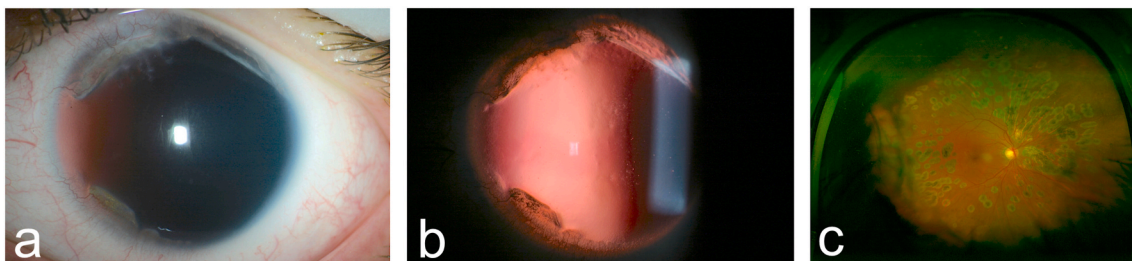


Fig. 1. a–c Corneal scars, aniridia and aphakia after trauma, primary wound closure and pars plana vitrectomy including endolaser coagulation.

Table 1

Patient data.

	Baseline	Post-surgery
Age [years] at surgery	16	16
IOP [mmHg]	18	17
BCDVA [logMAR]	0.00 (contact lens)	−0.10
Manifest refraction [D]	+13.50/−4.25/10°	+1.75/−1.50/10°
SE [D]	+11.38	+1.00
Axial length [mm]	23.90 ± 6.00	23.90 ± 6.00
Lens status	Aphakia	Pseudophakia (Kowa AvanseePreset UV®, +20.50 D)

BCDVA = best-corrected distance visual acuity.

D = diopters.

IOP = intraocular pressure.

SE = spherical equivalent.

5. No iridectomy was planned as we wanted to keep the AI as stable as possible as it should be attached to the IOL without sutures. Furthermore, we assumed that after trimming of the AI there should be enough space at the edges of the AI for aqueous humor circulation.

3.2. Surgical technique step-by-step

At first, two opposite scleral marks were made 2.0 mm from the limbus on the horizontal 0–180° axis. An additional scleral mark was created at the nasal side 2.0 mm below and at the temporal side 2.0 mm above the first scleral marks (Fig. 2). A pars plana 25-gauge infusion trocar was inserted to keep the intraocular pressure constant especially as the patient had already been vitrectomized previously in 2014.

Trimming of the HumanOptics *Customflex Artificialiris Fiber Free* was

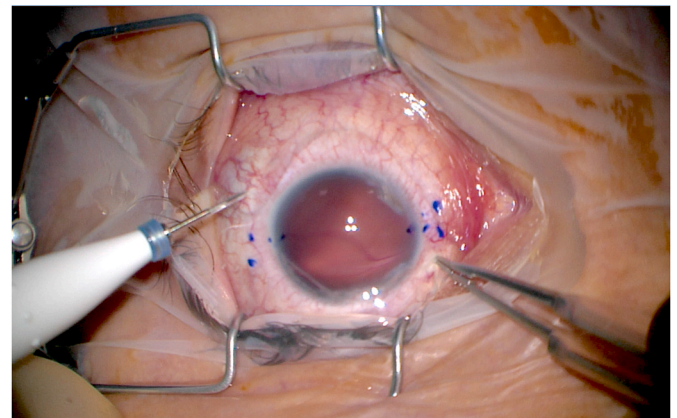


Fig. 2. Scleral marks for later IOL haptic externalization. 2.0 mm from limbus on 0–180° axis and 2.0 mm below and above 0–180° axis. 25-gauge pars plana infusion trocar.

made using a single-use trephine with a diameter of 10.5mm (Fig. 3a). The later penetration sites of the IOL haptics were marked at a 0–180° axis 1.0 mm away from the outer iris rim.(see Fig. 3b)

The three-piece Kowa *AvanseePresetUV* IOL with thin haptics was put behind the artificial iris. A bent 30-gauge thin-walled cannula was pierced through the artificial iris 1.0 mm from the outer rim at the marked sites. The haptics were inserted into the cannula and pierced through the artificial iris with the haptic ends eventually lying on top of the anterior surface of the artificial iris. The artificial iris lied centered and tension-free onto the IOL optic (Fig. 4).¹⁶

An additional 9-0 nylon “safety suture” was pierced through the artificial iris at 2.0 mm from the outer rim. The safety suture was supposed to stay extraocular throughout the whole implantation process and acted as retractor in case the IOL and iris subluxated into the vitreous cavity during scleral fixation.

A 5.5 mm sclerocorneal tunnel was prepared superior (Fig. 5a). The sandwich of IOL and artificial iris was folded using an IOL implantation forceps and was implanted through the tunnel (Fig. 5b). The safety suture ends were kept extraocular.

Now, the Yamane technique for scleral fixation of the IOL was completed as follows: A 30-gauge cannula was inserted ab externo starting at the scleral mark that laid below and above the horizontal axis. The cannula was moved intrasclerally to the other scleral mark that laid on the horizontal axis in a curved move penetrating the sclera and entering intraocularly at the 0° and 180° position respectively. The IOL haptics were introduced into the 30-gauge cannula using a forceps and then externalized, again in a curved move. The thin 3-piece IOL haptic was held externally with a forceps and the distal 1.0–2.0 mm were flanged using a mobile cautery device (Fig. 6). The flanged haptic end prevents the haptic to slip back through the sclera. The flange was buried subconjunctivally within the scleral tunnel. The same was done at the other side. At the end, the safety suture was pulled out through the sclerocorneal tunnel, and the tunnel was sutured with a self-resorbing polyglactin (Vicryl) 9-0 suture. The infusion trocar was removed and the sclerotomy was also sutured with a self-resorbing polyglactin (Vicryl) 9-0 suture (Fig. 7). The postoperative therapy was prednisolone acetate 1.0% eye drops, hydrocortisone 2.5% ointment and levofloxacin 5mg/ml eye drops.

4. Results

During the 11-month follow-up period an increased intraocular pressure (IOP) of 60 mmHg was noted five days after surgery. The maximum preoperative IOP in our records was 22 mmHg. The increased IOP was suspected to be due to a response reaction to the topical steroids. Therefore, the postoperative treatment topical regime was changed from prednisolone acetate 10mg/ml to loteprednole 0.5% and dorzolamide 20mg/ml and timolol 5mg/ml eye drops. With this treatment the IOP could be lowered to 23 mmHg. One week after, the patient

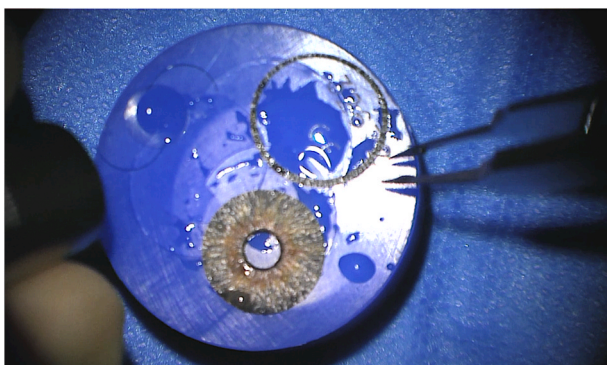


Fig. 3a. Trimming of artificial iris with 10.5 mm diameter trephine.

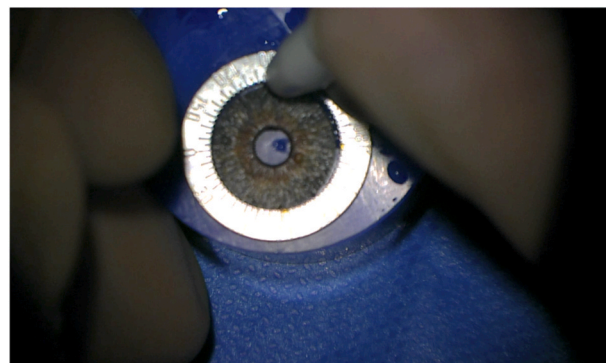


Fig. 3b. Marking of artificial iris at later IOL haptic penetration sites 1.0 mm from the outer iris rim on 0–180° axis.



Fig. 4. Artificial iris on top of IOL with pierced IOL haptics at 1.0 mm from the outer iris rim on 0–180° axis.

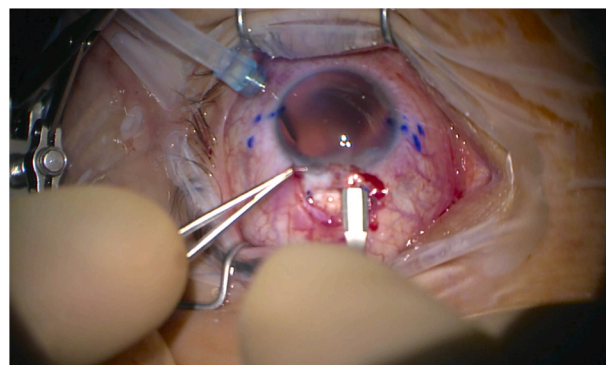


Fig. 5a. Preparation of sclerocorneal tunnel.

presented to our emergency department with a slight vitreous hemorrhage and an IOP increase up to 46 mmHg. As cause, we suspected a bleeding around the sclerotomy site that had slowly leaked postoperatively. Therefore, we decided for a pars plana vitrectomy (ppv) with removal of the intraocular blood. During the second procedure, a surgical iridectomy was created with intraocular scissors at the temporal-superior rim of the artificial iris. The IOP lowered to normal levels (17–22 mmHg) under timolol 5mg/ml eye drops and remained stable. The topical therapy was phased out slowly. During the 11-month follow-up period, the patient did not show any irido-pseudophakodonesis. There was a slight inferior decentration of the AI pupil aperture.

The best-corrected visual acuity after surgery increased up to –0.10 logMAR and the spherical equivalent reduced from 11.38 to 1.00

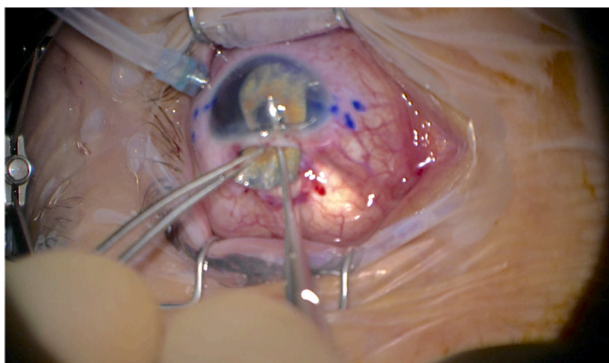


Fig. 5b. Implantation of artificial iris combined with IOL.

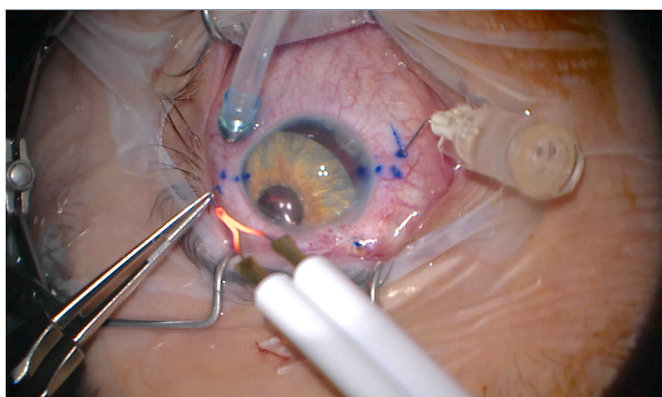


Fig. 6. IOL haptic flange using a mobile, single-use cautery device.

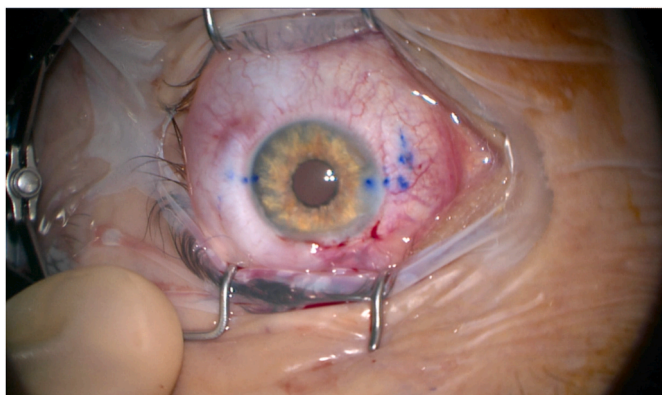


Fig. 7. Surgery end.

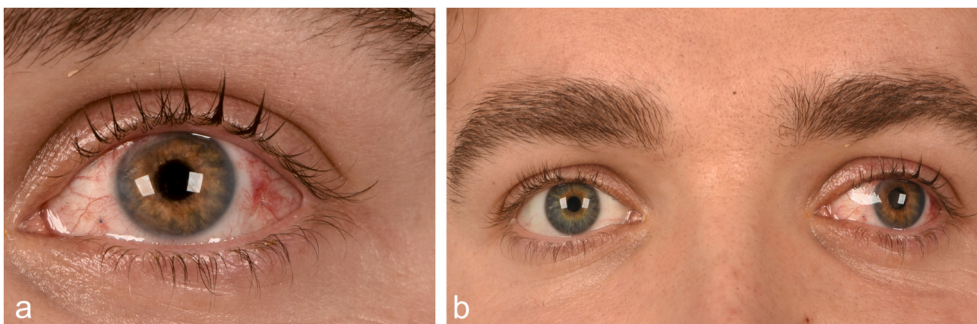


Fig. 8. a, b Results at follow up 1 week after surgery.

diopters. Eventually, the patient was very happy with the cosmetic as well as the functional results. (Fig. 8a and b).

5. Discussion

The presented case shows a good postoperative CDVA of the affected left eye. On the postoperative photos an exotropia of the left eye can be noted. However, the patient did not complain about double vision. The patient had presented to our hospital on the day of trauma for the first time. Therefore, we do not have reports about pre-trauma CDVA and strabismus status. The achievable CDVA and the fact that the trauma took place at the age of ten let us draw the conclusion that the patient had undergone a normal development of vision. Consequently, the patient should be capable of full stereo vision. An orthoptics examination is advisable during future follow-ups. Review of current literature identified *inter alia* 14 publications with combined HumanOptics Artificial Iris-IOL implantation, 6 publications with combined Morcher Black Diaphragm Intraocular Lens (BDI) implantation, 1 publication with a combined Morcher IrisMatch implantation, 7 publications with a combined Ophtec Model 311 Iris Reconstruction Lens implantation, 1 publication with a personalized Ophtec Black Diaphragm Intraocular Lens (BDI) implantation, 2 publications with a combined Ophtec Artisan Iris Reconstruction Intraocular Lens implantation, 3 publications with a combined Ophtec/Reper Artificial Iris implantation (see Table 2).

5.1. AI trimming

Preoperative biometry of the left eye showed a horizontal white-to-white (HWTW) distance of 11.9mm. The axial length of both eyes was normal (right: 24.1, left: 23.9 mm). Trephination of the AI makes an angle closure unlikely as there should be sufficient flow of aqueous humor around the peripheral rim of the artificial iris. In literature, there are different opinions on whether to trephine and on how much to trephine. *Bonnet* et al. suggest to use larger AI diameters and to avoid trephination if possible.²⁰ *Ayliffe* et al. suggest to add +0.5mm to the HWTW diameter.²¹ *Mayer* et al. would aim for an AI diameter of 9.5mm for an in-the-bag implantation and 11.5–12.5mm for sulcus-ciliaris implantation.¹⁹ *Rickman* et al. would subtract 0.5–1.0mm from the WTW distance and rather aim for a smaller AI diameter with a target of 11.0mm and 10.0mm in small eyes.²² For children, even smaller AI diameters of 8.0mm should be considered as *Jusufovic* et al. report.²³ In another publication *Mayer* et al. give the advice of trimming the AI diameter to WTW minus 0.5mm and point out that a removal of the residual iris in sutureless sulcus implantation of the AI might have a positive effect in the prevention of secondary glaucoma.¹¹ *Gooi* et al. recommend to assure that there is enough clearance of the outer AI rim to the IOL haptics to avoid iris and ciliary body chafing.²⁴ *Yoeruek* et al. suggest to subtract 1.0mm from the WTW distance.²⁵ Investigations of trimmed artificial iris suggest that AI with fiber show sharp fiber ends sticking out of the trimmed AI edge, being a possible cause for prolonged postoperative inflammation and bleeding.^{22,26} As our patient showed

Table 2
Literature overview of selected publications.

Year	Publication	Artificial iris type	Fixation of IOL to AI	Fixation of combined AI-IOL-sandwich	Mean follow-up rounded in [months]	Total clinical cohort (n)
2022	Mayer CS et al. ¹³	HumanOptics Customflex Artificialiris (with fiber)	Sutured: at optic-haptic junction	Sulcus ciliaris, sutured transsclerally (scleral tunnel)	3	n = 1
2021	Frisina R et al. ⁹	Ophtec/Reper Artificial Iris Model C	Combined implant by manufacturer	Anterior chamber, sutured transsclerally (10-0 polypropylene, through eyelets at each of the 3 haptics, scleral flaps)	12	n = 4
2021	Jakob-Girbig J et al. ⁶	Ophtec/Reper Artificial Iris Model C	Combined implant by manufacturer	Sulcus ciliaris, sutured transsclerally (10-0 polypropylene, through eyelets at each of the 3 haptics, Z-suture) Sulcus ciliaris, sutured transsclerally (10-0 polypropylene, cow hitch loop through eyelets at each of the 3 haptics, scleral flap)	3–4	n = 2
2021	Jiang S et al. ³³	Ophtec/Reper Artificial Iris Model F (?)	Combined implant by manufacturer	Anterior chamber, sutured transsclerally (Gore-Tex suture)	24	n = 1
2021	Mayer C et al. ¹⁹	HumanOptics Customflex Artificialiris (n/a)	<i>Various techniques inter alia:</i> Sutured: at IOL optic (haptics removed) (“Technique 4”)	<i>Various techniques inter alia:</i> Sulcus ciliaris, sutured transsclerally (9-0 polypropylene)	5	n = 44
2020	Mayer CS et al. ²⁷	HumanOptics Customflex Artificialiris (with fiber)	<i>Various techniques inter alia:</i> Sutured: through proximal haptic (distal haptic ends removed) (“Technique E”)	<i>Various techniques inter alia:</i> Sulcus ciliaris, sutured transsclerally (10-0 polypropylene)	5	n = 59
2020	Parikakis E et al. ³⁴	Ophtec Model 311 Iris Reconstruction Lens	Combined implant by manufacturer	Sulcus ciliaris (?) sutured transsclerally (CV-8 Gore-Tex, cow hitch knot at haptic eyelets, 4-point fixation)	6	n = 1
2020	Riedl JC et al. ³⁵	HumanOptics Customflex Artificialiris (n/a)	<i>Various techniques inter alia:</i> Sutureless: enclavation of iris fixated IOL (“Sandwich-Implantat”) Sutured? (“Hybridimplantation”)	<i>Various techniques inter alia:</i> Sulcus ciliaris, sutureless behind residual iris Sulcus ciliaris, sutured transsclerally (10-0 polypropylene)	41	n = 51
2020	Sousa Silva R et al. ¹⁰	<i>HumanOptics Customflex Artificialiris (with fiber)</i>	Sutured: through IOL eyelets (10-0 polypropylene)	Sulcus ciliaris, sutured transsclerally (7-0 CV-8 Gore-Tex)	6	n = 4
2020	Wang et al. ⁷	Ophtec Model 311 Iris Reconstruction Lens	Combined implant by manufacturer	<i>Various techniques inter alia:</i> Sulcus ciliaris, sutureless Sulcus ciliaris sutured transsclerally (9-0 polypropylene, scleral flaps as needed)	60	n = 38
2020	Wolf A et al. ¹²	HumanOptics Customflex Artificialiris (n/a)	Sutured: pierced through IOL plate haptic edges (4-point fixation)	Sulcus ciliaris, sutured transsclerally (Hoffman scleral pockets)	1–6	n = 2
2019	Yoeruek E et al. ²⁵	HumanOptics Customflex Artificialiris (n/a)	Sutureless: 3-piece IOL haptics directly through 0.9mm stab incisions (“belt-loop”)	Sulcus ciliaris (?), sutured transsclerally (10-0 polypropylene, Z-suture, 3-point fixation)	25	n = 5
2017	Mayer C et al. ¹⁶	HumanOptics Customflex Artificialiris (with fiber)	<i>Various techniques inter alia:</i> Sutured: through proximal haptic (distal haptic ends removed) (“Technique E”)	Sulcus ciliaris, sutured transsclerally (10-0 polypropylene)	NA	n = 51
2017	Villemont AS et al. ³⁶	Morcher Black Diaphragm Intraocular Lens (BDI) Model 67F and 67F Morcher IrisMatch Model 30B	Combined implant by manufacturer	Sulcus ciliaris sutured transsclerally (10-0 polypropylene, scleral flaps)	32	n = 17
2016	Gunenc U et al. ³⁷	HumanOptics Customflex Artificialiris (n/a)	Sutured: through haptic eyelets of PMMA IOL (9-0 polypropylene)	Sulcus ciliaris (?), sutured transsclerally (9-0 polypropylene, scleral tunnel)	0,25	n = 1
2016	Spitzer MS et al. ¹⁴	HumanOptics Customflex Artificialiris (n/a)	<i>Various techniques inter alia:</i> Sutureless: 3-piece IOL haptics directly through 0.9mm stab incisions (“belt-loop”)	<i>Various techniques inter alia:</i> Sulcus ciliaris, sutured transsclerally (10-0 polypropylene, Z-suture, 2-point fixation)	24	n = 34
2015	Mayer CS et al. ³⁸	HumanOptics Customflex Artificialiris (with fiber)	<i>Various techniques inter alia:</i> Sutured	<i>Various techniques inter alia:</i> Sulcus ciliaris, sutured transsclerally	14	n = 36
2014	Gooi P et al. ²⁴	HumanOptics Customflex Artificialiris (with fiber)	Sutureless: 3-piece IOL haptics directly through stab incisions (“belt-loop”)	Sulcus ciliaris, sutured transsclerally (scleral flaps, optionally fibrin glue)	4	n = 1
2013	Forlini C et al. ²⁹	HumanOptics Customflex Artificialiris (n/a)	<i>Various techniques inter alia:</i> Sutureless: retropupillary and prepupillary enclavation of iris-claw IOL (both unsuccessful) Sutured	<i>Various techniques inter alia:</i> Sulcus ciliaris, sutured transsclerally (10-0 polypropylene, scleral pockets, 3- and 4-point fixation)	6	n = 4
2012	De Grande V et al. ³⁹	Ophtec Model 311 Iris Reconstruction Lens	Combined implant by manufacturer	Posterior chamber, sutured transsclerally (CV-8 Gore-Tex, 3-point fixation at 2 haptic eyelets and 1 “sling suture” at haptic-optic junction, scleral patch, fibrin glue)	n/a	n = 1
2012	Spitzer MS et al. ²⁸	HumanOptics Customflex Artificialiris (n/a)	Sutureless: 3-piece IOL haptics directly through 0.9mm stab incisions (“belt-loop”)	Sulcus ciliaris, sutured transsclerally (10-0 polypropylene, Z-suture, 2-point fixation)	4–48	n = 4
2011	Mashor RS et al. ⁴⁰	Morcher Black Diaphragm Intraocular Lens (BDI) Model	Combined implant by manufacturer	Sulcus ciliaris (?), sutured transsclerally	2–44	n = 11

(continued on next page)

Table 2 (continued)

Year	Publication	Artificial iris type	Fixation of IOL to AI	Fixation of combined AI-IOL-sandwich	Mean follow-up rounded in [months]	Total clinical cohort (n)
2009	Roman S et al. ⁴¹	67G and 67F Ophtec Model 311 Iris Reconstruction Lens <i>Various devices inter alia:</i> Ophtec Model 311 Iris Reconstruction Lens Morcher Black Diaphragm Intraocular Lens (BDI)	Combined implant by manufacturer	<i>Various techniques inter alia:</i> Sulcus ciliaris, sutureless Sulcus ciliaris, sutured transsclerally (10-0 polypropylene)	44	n = 7
2008	Aslam SA et al. ⁴²	Morcher Black Diaphragm Intraocular Lens (BDI) Model 67F	Combined implant by manufacturer	Sulcus ciliaris, sutureless Sulcus ciliaris, sutured transsclerally	42	n = 40
2008	Sminia ML et al. ⁴³	Ophtec Artisan Iris Reconstruction Intraocular Lens	Combined implant by manufacturer	Anterior chamber, sutureless, enclavated to residual iris	106	n = 5
2007	Miller AR et al. ⁴⁴	Ophtec Model 311 Iris Reconstruction Lens	Combined implant by manufacturer	Sulcus ciliaris, sutured transsclerally (10-0 polypropylene)	3–36	n = 9
2005	Menezo JI et al. ⁴⁵	<i>Various implants inter alia:</i> Morcher Black Diaphragm Intraocular Lens (BDI) (Model 67G and 67F)	Combined implant by manufacturer	Capsular bag, sutureless Sulcus ciliaris, sutured transsclerally (10-0 polypropylene, scleral flap)	22	n = 7
2004	Price MO et al. ⁴⁶	Ophtec Black Diaphragm Intraocular Lens (BDI) (personalized) Ophtec Model 311 Iris Reconstruction Lens	Combined implant by manufacturer	Capsular bag, sutureless Sulcus ciliaris, sutureless Sulcus ciliaris, sutured transsclerally	12	n = 10
2003	Hanumanthu S et al. ⁴⁷	Ophtec Artisan Iris Reconstruction Intraocular Lens (custom-made, colored polymethyl methacrylate)	Combined implant by manufacturer	Anterior chamber, sutureless, enclavated to residual iris	10	n = 1
2000	Reinhard T et al. ⁴⁸	Morcher Black Diaphragm Intraocular Lens (BDI) Model 67 (various versions)	Combined implant by manufacturer	Sulcus ciliaris, sutureless	46	n = 19

some residual iris, we aimed for smaller AI diameter of 10.5mm to avoid contact of the artificial iris with the ciliary body in the event of an IOL tilt. Furthermore, we worked with a single-use trephine to assure best-possible sharpness of the instrument and to create a cutting edge of the fiber-free AI that was as smooth as possible. The AI without fiber has shown less risk for secondary glaucoma.²²

5.2. Sutured vs. sutureless

We favored a completely sutureless approach to avoid suture- and knot-associated complications such as suture erosion, suture breaks and suture loosening especially with regards to the long-term stability considering the young age of our patient.^{16,19,24,27} Therefore, even established suture techniques as well as novel suture-based approaches in combination with an AI such as the Z suture described by Spitzer et al.,²⁸ Rickann et al.²² and Yoeruek et al.²⁵ or the “slip-and-slide” technique by Wolf et al.¹² were not amongst our options. Forlini et al. reported the attempt of enclavating an iris-claw IOL to an AI.²⁹ An appealing approach because of its technical simplicity. However, the execution was reported unsuccessful.²⁹ Thus, we decided for a 3-piece IOL.²⁹ A 3-piece IOL held the possibility to suturelessly attach the IOL to the AI by the IOL haptics which would keep all possibilities for scleral fixation of the AI-IOL-sandwich.^{19,27} Spitzer et al. and Gooi et al. were amongst the first to publish a direct sutureless fixation of a 3-piece IOL to the AI using the IOL haptics held by created “belt-loops” within the AI.^{24,28} To reduce manipulation of the AI we chose a facilitated approach by simply piercing the IOL haptics through the peripheral AI with the help of a 30-gauge thin-walled cannula. In our opinion, the advantage of the Yamane technique in combination with a haptic fixated AI-IOL sandwich technique lies in its relative technical easiness and robustness. The Yamane technique keeps the scleral trauma to a minimum by not using intrascleral sutures (Z suture), tissue glue or scleral flaps (e.g. Hoffman scleral pockets³⁰) which may be impossible to create

in severely traumatized eyes.²⁸

5.3. Fiber vs. fiber-free

The fiber-free version of the HumanOptics Customflex Artificial Iris is less rigid and hence easier to fold and to implant, especially when combined with an IOL. Furthermore, the fiber-free artificial iris is lighter and thinner which reduces the risk of an IOL tilt and thereby reduces the risk of irritation and chafing of the iris remnants. A healthy phakic crystalline lens shows a mean unaccommodated thickness of around 4mm.^{31,32} The total thickness of the AI-IOL sandwich is estimated as follows: AI thickness 0.25mm (peripheral) to 0.40mm (central), IOL thickness 0.50mm–1.00mm and residual iris thickness approximately 0.50mm which is in sum less than a crystalline lens.¹⁶ A HumanOptics Artificial Iris fiber-free approximately weighs 31–34 g when trimmed to a diameter of 10.5mm according to the manufacturer. The manufacturer Kowa states an approximate mass for the IOL type Avanseepreset UV of 1,9 g. Consequently, the package of artificial iris and IOL weighs approximately 17 times more than the IOL alone. Moreover, trimming the AI seems to bear less complications with the fiber-free version as described above. With the presented technique no sutures remain within the AI. In this regard the fiber-containing version would not offer additional benefit. Previous studies have shown good results using the fiber-free version of the artificial iris.^{14,17,26} However, the AI is supposed to stay centered on top of the IOL via the IOL haptics. Spitzer et al. used both, the fiber and the fiber-free, version of the AI and they did not see the necessity to use the fiber-containing version as long as complete iris prostheses are implanted.²⁸ Gooi et al. used the fiber version for their “belt-loop” technique.²⁴

5.4. IOP and iridectomy

The postoperative IOP of our patient increased. He was under topical

dozalamide 20mg/ml and timolol 5mg/ml and loteprednole 0.5%. Due to the vitreous hemorrhage and the conservatively difficult to control IOP we made the decision for a pars plana vitrectomy. Our main concern was that an IOL tilt might push the AI anteriorly causing an angle closure. Even though the artificial iris did not show a bombée configuration, we performed a surgical iridectomy of the artificial iris during that same intervention. As the AI was stable and required no further manipulation the performed scissors-iridectomy should not decrease the stability of the AI as reported elsewhere.¹⁶ Even without fiber, the AI material is comparatively rigid. We therefore assume that a clinically visible iris bombée indicating for a pupillary block will not form in the same manner as it would do with a normal iris. Consequently, we did not dare to rely on the clinical presence of an iris bombée especially as we had already decided for the second intervention. The iridectomy was done as safety precaution also with regards to a possible future tilt of the Yamane IOL that might push the artificial iris forward and might cause an angle narrowing.

5.5. Alternative combined implants

As mentioned in the introduction, besides the HumanOptics Customflex Artificial Iris there are other iris prostheses that can be combined or are already combined with an IOL. Apart from the Ophtec/Reper Artificial Iris the HumaOptics Artificial Iris is the only foldable implant allowing small incisions 2.8–3.0mm. The Ophtec/Reper AI offers a color range of 300 presets to choose from whereas the HumanOptics AI is individually manufactured based on photographs of the partner eye and of iris remnants. Furthermore, the Ophtec/Reper Model A, C and F devices are only available with one IOL type whereas the HumanOptics AI theoretically can be combined with any IOL in the market. Therefore, we preferred the HumanOptics AI above the other combined AI-IOL devices that would have been available.

6. Conclusion

The sutureless scleral fixation technique described by Yamane et al.¹⁸ is a currently very popular and successful but comparatively young technique. Only very limited data on long-term stability and tilt resistance of these scleral fixated IOLs exists. Moreover, to our best knowledge, this report is the first to describe an IOL with flanged haptics that piggybacks an artificial iris. This technique is as minimally invasive and technically straight-forward as possible on the premise of avoiding sutures and their inherent long-term complication risks. However, especially stability has to be closely followed. A limitation of this report is the short follow-up time of 11 months. The patient will be seen and monitored during future appointments. Further improvements of the described technique are possible, such as using a modified 2.8–3.0 mm IOL cartridge to fold and shoot the IOL with the attached artificial iris through a clear cornea incision. This would have the advantage of a surgical technique being completely sutureless.

Long-term follow-ups of this case and similar cases are needed to prove stability and low complication rates.

Patient consent

This report does not contain any personal information that could lead to the identification of the patient. Approval of the Ethics Committee of the Ludwig-Maximilians-University (LMU) Munich was obtained (reference number: 21–0747).

Funding

No funding or grant support.

Conflicts of interest

The following authors have no financial disclosures regarding this publication: DRM, SGP, MS, TCK, WJM.

Authorship

All authors attest that they meet the current ICMJE criteria for authorship.

CRedit author statement

DRM: Validation, Writing - Review & Editing, Supervision, Writing - Original Draft, Visualization, Data Curation. **SGP:** Validation, Writing - Review & Editing, Supervision. **MS:** Validation, Writing - Review & Editing. **TCK:** Validation, Writing - Review & Editing. **WJM:** Validation, Writing - Review & Editing, Supervision, Writing - Original Draft, Visualization, Conceptualization.

Acknowledgements

None.

References

- Choyce DP. The uses of acrylic anterior chamber implants illustrated by cases shown. *Proc Roy Soc Med.* 1961;54:849–856.
- Pandey SK, Apple DJ. Professor Peter Choyce: an early pioneer of intraocular lenses and corneal/refractive surgery. *Clin Exp Ophthalmol.* 2005;33:288–293.
- Sundmacher R, Reinhard T, Althaus C. Black-diaphragm intraocular lens for correction of aniridia. *Ophthalmic Surg.* 1994;25:180–185.
- Sundmacher T, Reinhard T, Althaus C. Black diaphragm intraocular lens in congenital aniridia. *Ger J Ophthalmol.* 1994;3:197–201.
- Reinhard T, Sundmacher R, Althaus C. [Iris black diaphragm intraocular lenses in traumatic Aniridia]. *Klin Monbl Augenheilkd.* 1994;205:196–200.
- Jakob-Girbig J, Salewsky S, Meller D. Use of the Ophtec artificial Iris Model C1 in patients with aniridia/aphakia. *Klin Monbl Augenheilkd.* 2021;238:803–807.
- Wang H, Jung J, Lin SR, Olson MD, Miller KM. Safety and efficacy of colored Iris reconstruction lens implantation. *Am J Ophthalmol.* 2020;216:174–185.
- Bv O. Iris Prosthesis; 2022.
- Frisina R, De Biasi CS, Tozzi L, et al. Reper intraocular lens with artificial iris: implantation techniques and outcomes. *Eur J Ophthalmol.* 2021;31:1469–1474.
- Sousa Silva R, Pereira Bruxelles C, Costa Andrade G, Correa Maia A. A technique for the management of posttraumatic aniridia and aphakia. *GMS Ophthalmol Cases.* 2020;10:Doc19.
- Mayer CS, Laubichler AE, Masyk M, Prah P, Zapp D, Khoramnia R. Residual Iris retraction syndrome after artificial Iris implantation. *Am J Ophthalmol.* 2019;199:159–166.
- Wolf A, Shajari M. Slip-and-slide technique for combined small-incision artificial iris and IOL implantation. *J Cataract Refract Surg.* 2020;46:1433–1435.
- Mayer CS, Son HS, Labuz G, et al. Laboratory and clinical experience with a diffractive trifocal intraocular lens sutured to an artificial Iris. *J Refract Surg.* 2022;38:61–68.
- Spitzer MS, Nessmann A, Wagner J, et al. Customized humanoptics silicone iris prosthesis in eyes with posttraumatic iris loss: outcomes and complications. *Acta Ophthalmol.* 2016;94:301–306.
- Koch KR, Heindl LM, Cursiefen C, Koch HR. Artificial iris devices: benefits, limitations, and management of complications. *J Cataract Refract Surg.* 2014;40:376–382.
- Mayer C, Tandogan T, Hoffmann AE, Khoramnia R. Artificial iris implantation in various iris defects and lens conditions. *J Cataract Refract Surg.* 2017;43:724–731.
- Mayer CS, Reznicek L, Hoffmann AE. Pupillary reconstruction and outcome after artificial Iris implantation. *Ophthalmology.* 2016;123:1011–1018.
- Yamane S, Sato S, Maruyama-Inoue M, Kadonosono K. Flanged intrascleral intraocular lens fixation with double-needle technique. *Ophthalmology.* 2017;124:1136–1142.
- Mayer C, Khoramnia R. Double prosthesis implantation": biometry and refractive outcomes in combined intraocular lens and artificial Iris surgery. *Clin Ophthalmol.* 2021;15:799–805.
- Bonnet C, Miller KM. Safety and efficacy of custom foldable silicone artificial iris implantation: prospective compassionate-use case series. *J Cataract Refract Surg.* 2020;46:893–901.
- Ayliffe W, Groth SL, Sponkel WE. Small-incision insertion of artificial iris prostheses. *J Cataract Refract Surg.* 2012;38:362–367.
- Rickmann A, Szurman P, Januschowski K, et al. Long-term results after artificial iris implantation in patients with aniridia. *Graefes Arch Clin Exp Ophthalmol.* 2016;254:1419–1424.

23. Jusufovic V, Cabric E, Popovic-Beganovic A, Musanovic Z, Zvornicanin J. Treatment of congenital aniridia associated with subluxated infantile cataract. *Med Arch*. 2014; 68:212–214.
24. Gooi P, Teichman JC, Ahmed II. Sutureless intrascleral fixation of a custom-tailored iris prosthesis with an intraocular lens. *J Cataract Refract Surg*. 2014;40:1759–1763.
25. Yoeruek E, Bartz-Schmidt KU. A new knotless technique for combined transscleral fixation of artificial iris, posterior chamber intraocular lens, and penetrating keratoplasty. *Eye (Lond)*. 2019;33:358–362.
26. Mayer CS, Laubichler AE, Khoramnia R, et al. Challenges and complication management in novel artificial Iris implantation. *J Ophthalmol*. 2018;2018:3262068.
27. Mayer CS, Hoffmann AM, Praha P, Reznicek L, Khoramnia R. Functional outcomes after combined iris and intraocular lens implantation in various iris and lens defects. *BMC Ophthalmol*. 2020;20:370.
28. Spitzer MS, Yoeruek E, Leitritz MA, Szurman P, Bartz-Schmidt KU. A new technique for treating posttraumatic aniridia with aphakia: first results of haptic fixation of a foldable intraocular lens on a foldable and custom-tailored iris prosthesis. *Arch Ophthalmol*. 2012;130:771–775.
29. Forlini C, Forlini M, Rejda R, et al. Simultaneous correction of post-traumatic aphakia and aniridia with the use of artificial iris and IOL implantation. *Graefes Arch Clin Exp Ophthalmol*. 2013;251:667–675.
30. Hoffman RS, Fine IH, Packer M. Scleral fixation without conjunctival dissection. *J Cataract Refract Surg*. 2006;32:1907–1912.
31. Dubbelman M, van der Heijde GL, Weeber HA. The thickness of the aging human lens obtained from corrected Scheimpflug images. *Optom Vis Sci*. 2001;78:411–416.
32. Richdale K, Bullimore MA, Zadnik K. Lens thickness with age and accommodation by optical coherence tomography. *Ophthalmic Physiol Opt*. 2008;28:441–447.
33. Jiang S, Baig K, Kalevar A, Choudhry N, Gupta RR. Novel approach to scleral fixation of a reper intraocular lens and artificial Iris complex following pars plana lensectomy and vitrectomy for ectopia lentis and cataract in a patient with aniridia and nystagmus. *Retin Cases Brief Rep*. 2021;15:615–618.
34. Parikakis E, Batsos G, Kontomichos L, Peponis V, Christodoulou E, Karagiannis D. Traumatic aniridia and aphakia management with Iris reconstruction lens using gore-tex sutures, an ab-externo approach. *Am J Case Rep*. 2020;21, e924706.
35. Riedl JC, Schuster AK, Vossmerbaeumer U. [Indications and surgical techniques for implantation of the Artificial Iris(R)]. *Ophthalmologe*. 2020;117:786–790.
36. Villemont AS, Kocaba V, Janin-Manificat H, et al. [Management of post-traumatic aphakia and aniridia: retrospective study of 17 patients undergoing scleral-sutured artificial iris intraocular lens implantation. Management of aphakia-aniridia with scleral-sutured artificial iris intraocular lenses]. *J Fr Ophthalmol*. 2017;40:592–605.
37. Gunenc U, Ozturk T, Arikan G, Kaya M. Combined transscleral fixation of an artificial iris prosthesis with an intraocular lens. *Arq Bras Oftalmol*. 2016;79:53–55.
38. Mayer CS, Hoffmann AE. [Surgical treatment with an artificial iris]. *Ophthalmologe*. 2015;112:865–868.
39. De Grande V, Rosenthal K, Reibaldi M, Gentile RC. Artificial iris-intraocular lens implantation for traumatic aniridia and aphakia assisted by silicone oil retention sutures. *J Cataract Refract Surg*. 2012;38:2045–2048.
40. Mashor RS, Bahar I, Kaiserman I, Berg AL, Slomovic A, Rootman DS. Combined penetrating keratoplasty and implantation of iris prosthesis intraocular lenses after ocular trauma. *J Cataract Refract Surg*. 2011;37:582–587.
41. Roman S, Cherrate H, Trouvet JP, Ullern M, Baudouin C. [Artificial iris intraocular lenses in aniridia or iris deficiencies]. *J Fr Ophthalmol*. 2009;32:320–325.
42. Aslam SA, Wong SC, Ficker LA, MacLaren RE. Implantation of the black diaphragm intraocular lens in congenital and traumatic aniridia. *Ophthalmology*. 2008;115: 1705–1712.
43. Sminia ML, Odenthal MT, Gortzak-Moorstein N, Wenniger-Prick LJ, Volker-Dieben HJ. Implantation of the Artisan iris reconstruction intraocular lens in 5 children with aphakia and partial aniridia caused by perforating ocular trauma. *J AAPOS*. 2008;12:268–272.
44. Miller AR, Olson MD, Miller KM. Functional and cosmetic outcomes of combined penetrating keratoplasty and iris reconstruction lens implantation in eyes with a history of trauma. *J Cataract Refract Surg*. 2007;33:808–814.
45. Menezes JL, Martinez-Costa R, Cisneros A, Desco MC. Implantation of iris devices in congenital and traumatic aniridias: surgery solutions and complications. *Eur J Ophthalmol*. 2005;15:451–457.
46. Price MO, Price Jr FW, Chang DF, Kelley K, Olson MD, Miller KM. Ophtec iris reconstruction lens United States clinical trial phase I. *Ophthalmology*. 2004;111: 1847–1852.
47. Hanumanthu S, Webb LA. Management of traumatic aniridia and aphakia with an iris reconstruction implant. *J Cataract Refract Surg*. 2003;29:1236–1238.
48. Reinhard T, Engelhardt S, Sundmacher R. Black diaphragm aniridia intraocular lens for congenital aniridia: long-term follow-up. *J Cataract Refract Surg*. 2000;26: 375–381.