

AUTO- AND ISOTRANSPLANTATION, IN DOGS, OF THE PARATHYROID GLANDULES.¹

By W. S. HALSTED, M.D., Baltimore.

PLATES II AND III.

As regards the preservation of form merely, transplantation of the parathyroid glandules has been successfully undertaken by several investigators. In combination with the thyroid gland, and before the remarkable discovery by Gley and by Vassale and Generali of a vital function for the parathyroid glandules, v. Eiselsberg, in 1892, in experiments which have become classic, made transplantations of these bodies which were not only successful morphologically but also from the functional point of view. The correct interpretation of his results, of the tetany which followed the extirpation of the transplanted thyroid gland, could not even be surmised until about four years later. Enderlen in 1898 and Payr in 1906 transplanted, with morphological success, the "epithelial bodies" as they happened to be included in the thyroid grafts. Transplantation of the isolated parathyroid glandules were undertaken by Camus as early as 1904 (Leischner) and Christiani reports in 1905 that the transplanted epithelial bodies of a cat had undergone little change in five years. The first to obtain functional proof by their transplantation was Leischner.² His experiments were performed on rats, the donor of the glandules being the donee. He used about eighty rats in the investigation and reports eight cases in which functional proof seems to have been obtained. My work on transplantation of the parathyroid glands in dogs was begun in the autumn of 1906, and has been continued, interruptedly, until the present time. It was undertaken with a view to determine the course to be pursued by the surgeon when a parathyroid gland has been accidentally removed or deprived of its blood

¹ Received for publication November 9, 1908.

² Leischner, *Archiv für klin. Chir.*, 1907, lxxxiv, 208.

supply, and in the hope that it might be attended with such success as to justify the attempt to transplant this glandule from man to man. In the course of the work many questions have arisen, and we find ourselves still hardly beyond the threshold of the investigation. In a patient suffering greatly from subtetanic hypoparathyroidism as the result of two operations by myself upon a large colloid goitre which produced distress from pressure, tetany has for three years been averted and the status parathyreoprivus made endurable by the feeding of parathyroids, by hypodermic injections of the nucleoproteids of the parathyroid gland (Beebe) and for almost one year by the administration of calcium lactate (MacCallum and Voegtlin).³

My first transplantations in dogs of the parathyroid glands,⁴ and the first of which I know, were made into the thyroid gland of the donor; next into the spleen, on the announcement by Payr of the successful transplantations of the thyroid gland into this organ; and finally (1907–1908), on the appearance of Leischner's contribution (von Eiselsberg's clinic), within and behind the musculus rectus abdominis, and in the midline, præperitoneally.

Pfeiffer, Hermann, and Mayer⁵ have made two successful auto-transplantations in puppies.

Biedl, commenting on the unsuccessful attempts of Foges, Kreidl, and himself to transplant ovaries, testicles, and suprarenal glands, contrasts these failures with his success in transplantation of the parathyroid glands. He states that a year prior to his report,⁶ he transplanted in two dogs into the spleen "foreign" parathyroids, and "after a time" removed both thyroid lobes as well as the parathyroids. One animal lived seven months without a trace of tetany and finally died of what seemed to be "cachexia thyreo-

³ Reference has been made to this case in previous publications. In the two operations only one parathyroid gland was removed (specimens examined by Dr. MacCallum and myself), and this little body was recognized the instant the final resection-cut into the right thyroid lobe was made. It was not until six months later, in the autumn of 1906, that it occurred to me to attempt the transplantation of the parathyroids.

⁴ Hypoparathyreosis, Status Parathyreoprivus and Transplantation of the Parathyroid Glands, *Amer. Jour. of Med. Sciences*, 1907, cxxxiv, 1.

⁵ *Mitteilungen aus den Grenzgeb. der Med. und Chir.*, 1907, xviii, 377.

⁶ *Wien. klin. Woch.*, 1908, xxi, 304.

priva." The spleen contained, the report states, two well healed, intact parathyroid glands. The second dog had tetany of short duration. It recovered, however, entirely, still lives, and consequently has, the author believes, parathyroids in the spleen which are functionally sufficient.

With the exception of the two cases of Biedl, I find no report of the successful isotransplantation of the parathyroid glands, and besides my own the only successful autotransplantations of these glandules in dogs are, perhaps, the two in puppies reported by Pfeiffer, Hermann, and Mayer. As to the success of the isotransplantations of Professor Biedl, I confess to a little surprise in view of the fact that it is quite out of accord with what one, *a priori*, would expect, and is also at variance with the results of my experiments; and for the following reasons. (1) Parathyroid deficiency was not created by Prof. Biedl either prior to or at the time of the transplantations—not until "after a time." (2) *Two* of the glandules were transplanted in each instance and *both* are said to have lived and performed their function. If this were the case the dogs must each have been possessed for a time of six functioning parathyroid bodies. (3) The transplanted glandules were "foreign." I can not, with my present views, quite credit the observation that an animal in full possession of an organ or set of organs whose function it is to furnish an internal secretion is capable of sustaining in a functioning state a second organ or set of organs of the same kind, and particularly not when these transplanted organs are of "foreign" origin. (4) The functional proof is lacking inasmuch as the glandules were not excised during life.

The results of the experiments undertaken in the winter of 1906–7, and of a portion of those made in 1907–8 have, previously, been reported in briefest abstract.⁷ Since the publication of these reports there have been developments, the result of further experimentation, which should be recorded. The cases of especial interest will be considered in some detail, the remainder recounted in the briefest manner.

⁷ *Proceedings of the Path. Soc. of Philadelphia*, 1908, xi, 109; *Proceedings of the Soc. for Exper. Biol. and Med.*, 1908, v, 74.

Sixty dogs, approximately, have been used in this investigation and more than 130 parathyroid glands transplanted. The technique has been precisely that of the operating rooms of the Johns Hopkins Hospital.

Of the first series, performed in the winter of 1906-7, there follow brief notes, with comments, of a selected few of these experiments which, interpreted in the light of my work of the following winter, contribute something to our knowledge.

DOG A. Jan. 15, 1907. *Operation I.* Autotransplantation into thyroid lobes. Excised the four parathyroid glandules, leaving, perhaps, a film almost too fine for ocular demonstration, of the left internal one, on the thyroid gland. Three of the glandules were replaced, in new situations, in the thyroid lobes.

Feb. 25, '07. *Operation II.* Excision of such parts of the thyroid gland as were believed to contain the transplanted bodies. Only one of the autoplants or autografts, was found. It was smaller, harder and less red than the normal parathyroid gland. *Microscopic examination.* The nuclear staining is excellent. The transplanted epithelial body seems altogether normal except that a little reactive fibrous tissue surrounds it and, here and there, in delicate strands, enters it. It is obviously difficult to furnish convincing evidence of functional proof.

As the dog had no symptoms of tetania parathyreopriva after the first operation, we are inclined to believe that the film of parathyroid tissue left on the thyroid gland in the process of shaving off the left internal parathyroid was sufficient to hold them in check until one of the much needed autografts had obtained its new blood supply and resumed its function. That only one of the transplanted glandules lived surprised me at the time of the observation, when I had hoped to find all three of them surviving, but this is the finding which, with my added experience, I should now be prepared for. I am anticipating a little in making at this point the statement that only one of the transplanted parathyroid bodies in a given animal, has in our researches survived; and furthermore that only so much of the successfully grafted epithelial body has lived as seemed essential to prevent pronounced symptoms of tetany, and not enough of it to entirely obscure evidence of hypoparathyroidism, such as a slight fibrillary tongue tremor.

DOG E. Jan. 23, 1907. *Operation.* Autotransplantation into the spleen. The two glandulæ parathyroideæ of the right side of the neck and the superior glandula parathyroidea of the left were excised and planted into the spleen.⁸

⁸The technique of the splenic transplantations is described and illustrated in the first article published by me on the subject of transplantation of the parathyroid glandules in dogs, *Amer. Jour. of Med. Sciences, loc. cit.*

The left thyroid lobe was also excised to insure destruction of the fourth glandula parathyroidea which was not seen.

Jan. 25, '07. Tetany.

Jan. 26, '07. Dead. *Autopsy* negative. Death believed to be due to tetania parathyreopriva.

Dog G. Jan. 28, 1907. *Operation*. Autotransplantation into the thyroid lobes. The internal left parathyroid glandule was excised and reimplanted into the left lobe of the thyroid gland. The superior (external) right parathyroid glandule was implanted into the right thyroid lobe near its anterior border, about 1 cm. above its inferior pole.

Feb. 8, '07. Dog has not been at all well since the operation. Believed to be suffering from parathyroid privation due to the considerable insult to both thyroid glands as well as to the excision of two transplanted bodies.

May 8, '07. One hundred and nine days since the transplantations; killed. *Autopsy*. There is no trace of the transplanted bodies, except a little pigment at the site of the transplantation of each.

This case is cited as evidence favoring the view that the thyroid privation was either insufficient or not sufficiently long continued to insure success for the transplantation. The restoration of function in the maltreated, but non-transplanted glandules, may have taken place too rapidly to admit of the return to life of either of the two transplanted bodies.

Dog H. Feb. 5, 1907. *Operation*. Searched neck carefully and did not find a single parathyroid glandule. It is the only time that I have had this experience. Probably to be explained, in part at least, by careless operative technique.

Feb. 8, '07. Has not been well since the operation. Is very thin. Slight fibrillary tremors.

The experiment is cited to show what I observed very frequently in my experiments in transplantation and extirpation of the thyroid gland in 1888-9,⁹ that mere handling of the thyroid lobes may give rise to symptoms of parathyroid privation. Manipulation, not excessive, of the thyroid gland, in dogs, has several times in my experience produced fatal tetany.

Dog N. Apr. 10, 1907. *Operation I*. Isotransplantations. Into the spleen were placed five parathyroid bodies taken from three or possibly four dogs. The transplantations all took place very smoothly by means of the needle and thread method described in a previous article (*l. c.*). Some of the glandules were kept in blood serum for, possibly, half an hour. The last obtained were, however, promptly transplanted. Parathyroid deficiency was not created.

⁹ An Experimental Study of the Thyroid Gland of Dogs, with Especial Consideration of Hypertrophy of this Gland, *Johns Hopkins Hospital Reports*, 1896, i, 373.

Apr. 16, '07. *Operation II.* Panthyroidectomy performed on both sides in such manner as to remove or destroy the blood supply of the parathyroids. Dog was rather weak before this operation. His cage companion of a few days before had died of distemper. I was not aware of this until after this operation.

Apr. 17, '07. Dog has tetany; evidenced by general tremors and rigidity.

Apr. 18, '07. Barely able to stand; very emaciated. The tremors observed yesterday are not demonstrable today. Trousseau's phenomenon cannot be elicited. Has cough, and from the nose is a discharge of blood-tinged mucus. Vomits. Gave hypodermic injection of one phial (℥ xii) of a protonucleid extract of parathyroid gland kindly sent me by Dr. Beebe for the patient so often referred to by me. Dog is being fed chiefly on milk.

Apr. 19, '07. No tremor nor spasms nor stiffness and dog runs about with surprising activity considering the great emaciation. Cough persists; also the discharge from nose.

Apr. 20, '07. 1.30 P. M. Dog much worse. The signs of tetany have all returned. Fell in tonic spasms with all four legs drawn to belly and toward mid-line, reminding one of the comparison to the obstetrician's hand in cases of tetany in the human subject. Second injection of nucleoproteid (Beebe).

Apr. 22, '07. Dog weaker than ever and greatly emaciated. Can, however, stand and totter about. Laps water in characteristic way, for minutes at a time, without lowering the level of the water in the basin.

Apr. 23, '07. Died last night. *Autopsy.* Each pleural cavity contained about one pint of blood-stained, slightly purulent fluid. Peritoneal cavity negative. The spleen was carefully sliced. One little necrotic body, smaller than and with the color of a mustard seed was found in the spleen near its surface, otherwise only a blood stain here and there remained as traces of the transplantations made two weeks ago.

The protonucleid extract (Beebe) was used in two of the dogs with tetany and with some effect, it was thought. The above dog lived six days after removal of his parathyroid glands, a long time considering the finding in the pleural cavities. Possibly the absorption of the five isoplants as well as the administration of the Beebe extract influenced the result. It can well be objected in this case that the glandules, or at least three of them, used in the isografting were not transferred to the spleen with sufficient promptness, and that their failure to survive was due in part to distemper and the thoracic complication.

In operations involving a large number of dogs and so many operating tables I was assisted by my house surgeon, Dr. Sowers, and by several other members of my hospital staff who made possible such an undertaking without delay and with the observance of a technique almost above criticism. Quite a large piece of the

thyroid gland was usually excised with its internal epithelial body to support and thereby facilitate the cutting of the latter; but only a small piece of the former remained in the isograft as prepared for the transplantation. The transplantations were on the whole very smoothly done.

Dog O. Apr. 24, 1907. Heavy, vigorous, young fox terrier. Estimated age one and a half years. *Operation I.* Isotransplantations, into spleen, of eight parathyroid glandules obtained from five dogs. The glands to be grafted were given a raw surface when external, cut with thyroid tissue when internal and each kept in the blood serum appertaining to it. Parathyroid deficiency not created until nineteen days later.

Apr. 25, '07. Dog is doing well.

Apr. 26, '07. Has appetite and runs happily about.

May 7, '07. Perfectly well and vigorous.

May 13, '07. *Operation II.* All thyroids with parathyroids excised.

May 14, '07. 8 A. M. Already severe tetany. 2 P. M. Severe symptoms have abated. Has tongue tremors still and laps water in the characteristic way. Refuses food.

Apr. 15, '07. 4.30 P. M. Extremities quite rigid. Fine tremors. Beebe's nucleo-proteid injected (about 10 minims). 4.45 P. M. Dog seems definitely brighter. Laps a little milk effectually. Stands up quite naturally. Fine tremors of tongue and of shoulder muscles persist. Refuses meat.

Apr. 16, '07. Found dead. *Autopsy* negative. Peritoneal and thoracic cavities normal. Spleen very carefully examined. The isografts have all been absorbed. Not a trace of them remains. At the surface of the spleen within the area of transplantation, a tiny white speck which we thought might possibly be the remains of a graft was preserved for microscopic examination. It proved to be nothing but fibrous tissue.

This case is one which, perhaps, above all others convinced me of the inadvisability at this time of further attempts at transplantation without the production of a parathyroid deficiency. I had not as yet ascertained that for isografts the likelihood of survival is, to say the least, very little. I have hoped for an opportunity to test isografting between dogs of one litter.

Results (winter of 1906-1907);¹⁰ Autotransplantation.—A de-

¹⁰ In 1906-07, I was assisted by members of my house staff and by medical students, especially Messrs. Chesnutt and Dinsmore; this year Dr. Hennington has rendered me great service in the operative and kennel work. The vicissitudes have been many—pneumonia, distemper, accidents, and escapes. On one occasion the laboratory was broken into, presumably by a discharged employee, and many of my most prized dogs set at large. Some of these dogs were awaiting the ultimate functional test of the transplantation after two or more operations.

gree of parathyroid deficiency is of necessity created in the autotransplantations. Of five autografts into the thyroid lobes of three dogs, two were successful (macroscopic and microscopic proof). Of eight autografts into the spleens of three dogs, one only succeeded (macroscopic proof). In no instance was functional proof of the success of these transplantations obtained. Such proof can not, of course, be convincingly obtained in the cases of transplantation into the thyroid because of the lack of certainty that no parathyroid tissue except that transplanted remains at the time of the final operation, at which well nourished thyroid tissue, sufficient to insure the life of the transplanted parathyroid gland, must be left.

Isotransplantation.—In five cases Dogs (K, L, M, N and O), two, seven, five, five, and eight parathyroids, respectively, were transplanted into the spleen. In only one dog (K) was a parathyroid deficiency created. In no instance was the transplantation successful; furthermore, tetany supervened and death occurred just as promptly, after removal of the thyroids and parathyroids in the neck, in these dogs with so many intrasplenic isoplants, as in the ungrafted dog. Hence we conclude that, in this instance, life was probably little, if at all, prolonged by the absorption of the parathyroids transplanted into the spleen.

The Technique of the Transplantation behind the Rectus Abdominis Muscle.—In the earlier transplantations the autografts, whether in the mid-line or behind the *Musculus rectus abdominis*, were, as a rule, placed either at the bottom of the wound or in its immediate vicinity with the view that, in the ultimate search for them, proximity to the wound would facilitate their discovery. It was, however, soon noted that the glandules behind the rectus muscle could distinctly be seen through the several layers of delicate and transparent fascia, namely, the posterior sheath of the muscle, the subperitoneal fascia and the peritoneum. They would instantly be detected from a mid-line wound on reflecting outward the abdominal wall. It became then our established procedure (1) to make an incision 1 cm. or less in length through the aponeurosis in front of the *Musculus rectus abdominis* over the inner edge of this muscle; (2) with the blades of our fine "mosquito-forceps," to liberate this border of the muscle from the mid-line fascia; and (3) with

a second pair of this forceps, to introduce the glandula parathyroidea between the widely separated blades of the first, to as high a point as feasible behind and within the sheath of the rectus muscle. In this manner the autograft is carried an inch or two above the line of incision through the anterior sheath of the muscle and well out of the sphere of influence of a possible drop or fraction of a drop of blood. The glandules successfully transplanted in this wise produced, except in one instance, no opacity of the fasciæ through which they were to be observed, and, at a glance, were discoverable under the glistening lining of the abdominal wall. The incision through the aponeurosis anterior to the Musculus rectus abdominis was closed with one mattress suture of China bead or the finest black silk. Over this the skin was brought together with sub- and intracutaneous and epithelial stitches. The abdominal wounds healed *per primam* without exception. The wounds of the neck were very carefully closed with continuous layer-sutures of the finest black silk (A or O) in a milliner's needle. Oozing points were included in the sutures, of which there were usually five or six rows—one each for (1) the mid-line muscles; (2) the deep fascia and muscle sheath; (3) the platysma and deep layer of superficial fascia; (4) the deep cutis and superficial layer of superficial fascia; (5) the mid-cutis; (6) the epithelium. The stitch which we designate as "epithelial" is particularly useful in the surgery of animals. It excites no irritation and includes so little more than the cuticle that it is finally shed with the latter, unless it, previously, be peeled or ripped off. The sewing with the fine straight needle may be accomplished with unusual rapidity. Aseptic precautions, thanks to the skillful assistance of Dr. C. W. Hennington, were throughout as perfect as we could make them. With perhaps five exceptions the neck wounds healed throughout *per primam*. It was chiefly in connection with the second operations carried out in the line of the original wound that the suppurations occurred.

Dog No. 1. Feb. 3, 1908. *Operation I.* Excised the superior, right parathyroid gland and transplanted it into the right rectus abdominis muscle. There was no bleeding. Excised the right thyroid lobe entire. Layer suture with black silk, collodion dressing.

Feb. 9, '08. Convalescence without incident. Both wounds healed *per primam*.

Feb. 10, '08. *Operation II.* Transplanted a small, freely movable parathyroid gland found resting on the thyroid gland, about midway between its poles, into the left rectus abdominis muscle. Excised the left thyroid gland, entire. The dog is now probably deprived of all parathyroid glands except the two transplanted ones.

Feb. 11, '08. Dog fairly well. No fibrillary tremor of tongue. No muscle twitching.

Feb. 12, '08. No definite sign of tetany.

Feb. 13, '08. 10 A. M. Dog very ill. Respirations 160-180 per minute. Pulse too rapid to be counted. Blood-tinged foam at mouth. Walks a few steps then falls and crawls with head close to the floor. Typical tremors. About 2 P. M. great improvement and at 6 P. M. nearly complete recovery. Pulse 120.

Feb. 14, '08. 10 A. M. Quite ill. Fibrillary tongue tremors, and clonico-tonic contractions of temporal and other muscles; characteristic gait. 5 P. M. calcium lactate, 4 grammes, in water administered per stomach tube by Dr. Voegtlin. Marked relief after one and a quarter hours.

Feb. 15, '08. Condition about as it was yesterday, before the exhibition of the drug. Calcium lactate again administered, and with difficulty, for attempts to pass the stomach tube excited convulsions. Improvement.

Feb. 16, '08. Sunday. Dog observed but once. Little if any better.

Feb. 17, '08. Definitely worse. Very ill. Calcium lactate administered for the third time. Prompt and marked improvement.

Feb. 18, '08. Better. Fibrillary tremors of tongue. Calcium lactate, fourth dose. Beneficial effect.

Feb. 19, '08. Improved. Tongue tremors persist, but are fainter. Calcium lactate, fifth dose.

Feb. 20, '08. Dog much better. Calcium lactate, sixth dose. Benefited.

Feb. 21, '08. Fairly well. Trace of tongue tremor.

Feb. 24, '08. No calcium for four days. Dog not so well. Marked tongue tremor and slight general muscular twitching. Calcium withheld.

Feb. 25, '08. Better. Tongue tremors.

Feb. 27, '08. Improving, active. Slight tongue tremors.

Mar. 2, '08. Much improved. Gaining in weight. Tongue tremors persist,

Mar. 6, '08. Fairly well. Tongue tremors very slight.

Mar. 11, '08. Quite well. Tongue tremors still demonstrable. It is twenty days since the last dose of calcium was given, and thirty days that the dog has been deprived of all parathyroids except the ones transplanted.

Mar. 20, '08. Dog is becoming much stouter, seems in excellent health. Frisks about as if life were enjoyed. But faint tongue tremor is, still, always to be seen.

Mar. 30, '08. Dog is strikingly plump. Faint tongue tremors, and rather general fibrillary twitchings are still manifest on careful observation.

Apr. 4, '08. Dog "fat" in the extreme. Contrasted with the other dogs, it seems quite certain that myxœdema has developed.

Apr. 9, '08. Normally active and apparently healthy. Continually increasing in size. Thickening of skin and subcutaneous tissue particularly conspicuous in nape of neck. Trace of tongue tremor usually visible.

Apr. 23, '08. Myxœdema increasing steadily. Dog somewhat deformed by it.

June 11, '08. Dog's plumpness is monstrous and rather uncanny. His hair is falling out. Activity, spirits and general health are good.

June 15, '08. Transferred to Drs. Voegtlin and Strouse for observations and experimentation during the summer.

Nov. 1, '08. This dog died during the past summer.

The cause of death was undiscoverable at autopsy. Dr. Voegtlin, who observed him carefully, is positive that tetania parathyreopriva did not at any time develop. He will publish a photograph which he took of the animal to show the state of excessive myxœdema, which has so rarely been produced in the dog. The preparations containing, presumably, the autograft and the subaortic accessory thyroid glands were, through a misunderstanding, destroyed by a servant to whom they had been, for a moment, intrusted. We are, therefore, in doubt to which of the two autoplants, in case only one survived, the prevention of tetany is to be ascribed.

It is conceivable, of course, that portions of two or more autoplants may live. This should, I think, be more likely to occur when two glandulæ parathyroidiæ are transplanted at the same time. I am inclined to believe that a very considerable parathyroid privation, greater, perhaps, than is ordinarily produced by the excision of the two parathyroids of one side may be essential to the success of the transplantation.

Dog No. 2. Feb. 3, 1908. *Operation I.* Total right thyroparathyroid-lobectomy (right panthyroidectomy¹¹) and transplantation of the right internal parathyroid gland in the mid-line, just external to the peritoneum.

Mar. 10, '08. Dog has been perfectly well since the operation. Wounds healed *per primam*. *Operation II.* Total thyroparathyroidectomy on left side and transplantation of the left internal parathyroid gland in the midline, præperitoneally. Dog has now, presumably, no parathyroid glands except those transplanted.

Mar. 15, '08. Has been perfectly well since the operation. Has manifested no signs of tetania parathyreopriva. Observed once or twice daily by Dr. Hennington and repeatedly by me.

Mar. 18, '08. A. M. Observed by Dr. Hennington, who, on careful examination of his tongue, found no trace of tremor.

Mar. 19, '08. Found dead in cage late yesterday afternoon. 12 M. *Autopsy.* Blood in nostrils, abdomen slightly distended, normal peritoneal cavity. Both lungs quite solid, and on section, dark red-black and infiltrated with blood-stained exudate. In the search for the transplanted parathyroid glands two

¹¹ A word proposed for the sake of brevity, but with some misgiving and disapproval

very small brown-red bodies were found in the mid-line subperitoneally, in the line of the cicatrix, and perfectly isolated from all tissues which might resemble them. They had the color which, as we learned later, is common to the successfully transplanted parathyroid glands. They have, of course, been preserved for microscopic examination (Path. No. 8764).

Death was quite certainly caused by pneumonia, and the time *post operativum* is too brief for conclusions. The absence of signs of tetany, however, for eight days after the second operation, and the fact that the transplanted epithelial bodies had not become necrotic is evidence in favor of the success of the transplantation. This is the only instance, in our experiments, in which, apparently, two autografts, at least part, have survived. I regret that sections have not as yet been made.

Dog No. 3. Feb. 5, 1908. *Operation I.* Autotransplantation of the right external parathyroid into the right rectus abdominis muscle. Removal of the right lobe of the thyroid with the internal parathyroid gland. In Dogs Nos. 1 and 2 the rectus muscle was prepared for the transplantation before the parathyroid body was excised, in the belief that the time of exposure of this body to the air might be shortened. But a very few seconds, if indeed any, were saved by this procedure and hence it was abandoned. The epithelial bodies to be transplanted were thenceforth kept in the blood of the wound, sometimes within, at other times without the body, the time required for the transfer rarely exceeding a few seconds. In case of the slightest bleeding a new pocket in the rectus would have been made.

Feb. 20, '08. Dog recovered from Operation I without incident. Both wounds healed *per primam*. *Operation II.* Procedure, precisely as described above, carried out on the left side, except that the internal parathyroid was used for transplantation instead of the external glandule. The dog is thus deprived of both thyroid lobes and for parathyroids is reduced to the two transplanted glandules.

Feb. 23, '08. Dog seemed fairly well for forty-eight hours *post operativum*. No signs of tetany could be detected. Found dead to-day. *Autopsy.* No blood in nostrils. Trachea and bronchi contain blood-stained frothy mucus. Right lung airless, heavy, congested. On section there exudes a bloody exudate. Sections made of the lung indicate a pneumonic process. The autopsy findings are otherwise negative. The parathyroid transplanted Feb. 5 was found on the posterior surface of the right rectus muscle much reduced in size and of a yellowish-brown color. The second gland, transplanted only three days before death, was surrounded by blood clots which may have been responsible for its death as well as, in part, for the death of the animal.

Dog No. 4. Feb. 5, 1908. *Operation I.* Right superior parathyroid gland transplanted *præperitoneally* in the mid-line, above the umbilicus. Removal of right lobe of thyroid gland with its internal epithelial body.

Feb. 29, '08. Dog perfectly well since operation. *Operation II.* Excised left

thyroid lobe with its parathyroid glandules and transplanted, præperitoneally, in the middle line, the left superior and inferior parathyroids, the latter being in two parts, contiguous, and each about 1.5 mm. in diameter. Dog deprived of both thyroid lobes and all parathyroids except the transplanted three.

Feb. 22, '08. Dog disinclined to come out of cage. Wags tail and stands up when petted. Faint trace of fibrillary tongue tremor.

Feb. 23, '08. About as yesterday—a little worse, perhaps.

Feb. 24, '08. Cough; muco-purulent discharge from nose which dog constantly licks. Licking of the nose, even when dry, is a characteristic symptom in tetania parathyreopriva. Faint fibrillary tremor linguæ. Other muscles not demonstrably affected. Dog decidedly worse, but we have the impression that his illness is not altogether due to hypoparathyroidism.

Feb. 25, '08. Calcium lactate, one dose, was given without definite effect.

Feb. 26, '08. 10 A. M. No tremor, but dog much weaker and very thin. Muco-purulent discharge from nose continues. Died about 3 P. M. *Autopsy.* Abdominal cavity negative. Wounds healed *per primam*. Barely a trace remains of the transplanted parathyroid glands. Left lung negative, except for small central induration. Right lung, lower lobe, consolidated and in state of hepatization beginning to resolve. Pneumonia must have hastened the death of this dog, and possibly was in a measure responsible for the failure of the transplantation.

Dog No. 5. Feb. 5, 1908. *Operation I.* Autotransplantation. Right superior parathyroid glandule transplanted behind right rectus muscle. Excised right thyroid lobe with its internal epithelial body.

Feb. 20, '08. Dog has been well since Operation I. Both wounds healed *per primam*. *Operation II.* Left superior parathyroid not found. Left internal glandule planted behind left rectus muscle. Left thyroid lobectomy. Dog reduced to the transplanted glandules.

Feb. 22, '08. Dog seems fairly well.

Feb. 23, '08. Not so well. Panting respiration.

Feb. 24, '08. A. M. Explosive expiratory efforts frequent. Tremors not demonstrable. Neck wound broken down. This is the first instance in these experiments of failure to heal *per primam*. P. M. Tongue tremors very pronounced.

Feb. 25, '08. Dog died about 2 P. M. Calcium lactate not administered in this case. *Autopsy.* Thoracic cavity negative except for a remarkable finding in the anterior mediastinum. There is an infiltration of blood, only three or four drachms in quantity, between the pleural leaves and lying chiefly on the pericardium, entirely outside of this sac. The blood-infiltration extends into the left neck to a point hardly above the subclavio-jugular junction. There is nothing to indicate that the blood gravitated from the neck to the mediastinum, for the former is perfectly healed and unstained, and the mediastinal blood staining fails to reach the neck wound by 3 or 4 cm. The mediastinal blood is not infected. It has excited no reaction, and the contiguous serous membranes have their natural lustre. I conclude that some traumatism, a fall or a self-inflicted blow on the mediastinum during recovery from the anæsthetic was responsible for this lesion. The blood extravasation was too slight, it seemed to me, to have been a factor in the death of this animal. A very careful search

for the transplanted glandules by Dr. Hennington and myself failed to reveal a trace of either except a minute area of tissue staining. *This is the first dog of the series of autotransplantations, behind or in the musculus rectus abdominis, to die of uncomplicated tetany.*

Dog No. 6. Pregnant bitch. Feb. 6, 1908. *Operation.* Autotransplantation. The right superior parathyroid gland planted into the right rectus abdominis muscle. Excision of right thyroid lobe.

Apr. 5, '08. Well since operation. Wound suppured. Gave birth to-day to five pups. No evidences of hypoparathyroidism during pregnancy or since delivery.

Apr. 7, '08. One of the pups, female, found dead. Each thyroid lobe measures 1 cm. in its vertical and 4 cm. in its transverse diameter. The lobes are connected by an isthmus covering one ring and two interannular spaces. The left superior (external) parathyroid is distinctly seen, though very minute. Weight of puppy 232 grams. Length from tip of nose to tips of hind feet, 26 cm.

Apr. 9, '08. During the past two days the four remaining pups have died. They had increased little if any in size. The average weight of the thyroid gland in each of these was .055 grams; the average length of the lobes 8 mm. and average width 3.5 mm.

Apr. 11, '08. Dog under observation. Retained for completion of the experiment.

Dog No. 7. Feb. 6, '08. *Operation I.* Autotransplantation. The left external parathyroid, situated as low as the middle of the thyroid lobe at its intero-posterior border, was transplanted behind the right rectus abdominis muscle just above the umbilicus. The right parathyroids were not found. Both thyroid lobes were considerably damaged in the search for the abnormally situated parathyroids; neither lobe was excised. The circulation of the unexcised parathyroids was probably much interfered with and thus a *considerable parathyroid privation caused, a factor in my opinion essential to the success of the transplantation.*

Feb. 7, '08. 9 A. M. Dog feels badly, whereas the three other dogs operated upon for autotransplantation about the same time yesterday seem perfectly well. He not only refuses to leave cage, but lies down immediately when placed on the floor of the room. His gait on walking and trotting is uncertain. No fibrillary tremors of tongue. Pulse 152. 4 P. M. Pulse 128.

Feb. 10, '08. Has been slowly improving since last note.

Feb. 15, '08. Seems perfectly well. Have at no time observed positive symptoms of tetania parathyreopriva, but believe that he suffered from hypoparathyroidism for several days after the operation.

Feb. 20, '08. *Operation II.* Both thyroid lobes excised and, presumably, the circulation of any remaining parathyroid destroyed. The wound was left open on account of a fine fistulous track in the cicatrix from the first operation.

Feb. 22, '08. Dog has been quite well since operation. No signs whatever of hypoparathyroidism.

Feb. 26, '08. Dog in fair health and spirits. On most careful and prolonged examination very faint fibrillary tongue tremors were observed. Hence the autoplant must have "taken," and, presumably, the parathyroid glandules excised in the double thyroidlobectomy were defunctioned by the first operation.

Mar. 2, '08. Dog is lively, quite well and hungry. No signs of tetany although I have the feeling that he is suffering from very slight parathyroid privation.

Mar. 3, '08. Quite well. *Operation III.* Laparotomy, to explore the posterior surface of the right rectus muscle *and if possible obtain functional proof of the success of the transplantation.* The transplanted glandule was at once recognized and excised. It was apparently full sized, shimmering clearly through the peritoneum. Its relation to the surrounding tissues, so far as reaction in them is concerned seemed to be precisely that of the external parathyroids in the neck. It could be slid about as freely as when in its normal position. I was unable to detect any departure from the normal color of the glandule. In this respect it differed from the transplanted glandules, observed before and more frequently later, in which, although functioning, partial absorption and invasion by fibrous tissue had taken place. In these the red hue was toned by yellow and brown.

Mar. 4, '08. Dog ill, but no tremors observed.

Mar. 5, '08. Very ill. Complete picture of tetania parathyreopriva. *Operation IV.* Isotransplantation of three parathyroid glands behind the left rectus abdominis muscle. Lactate of calcium exhibited.

Mar. 6, '08. Dog found dead this A. M. *Autopsy.* Negative as concerns complications. Death attributable to tetania parathyreopriva. A section of this unusually normal-looking autograft is illustrated in Plate I. That the drawing in Plate I seems inferior to that in Plate II is due to the fact that the transplanted parathyroid from this dog (No. 7) was overheated in xylol.

Dog No. 8. Feb. 6, 1908. *Operation I.* Autotransplantation. The right superior glandula parathyreoidea consisted of two distinct portions quite equal in size; the one, the gland proper, the other, a cyst closely attached to and part of it. The right thyroid lobe was not excised, but it became necessary in the course of its investigation to ligate the vessels at its inferior pole. From the left thyroid lobe, also not removed at this operation, an unusually large internal parathyroid gland was excised and transplanted præperitoneally in the middle line.

Feb. 20, '08. Uneventful convalescence. No suggestion of tetany. *Operation II.* Both thyroid lobes excised in such manner as to include the remaining glandulæ parathyreoideæ. The dog is now reduced to one autoplant.

Feb. 22, '08. Well.

Feb. 23, '08. Well.

Feb. 24, '08. Not quite so well, but signs of tetany not discoverable. Wound healed *per primam.*

Feb. 26, '08. Dog becoming weak and thin. Muco-purulent discharge from nose. Trace of tongue tremor.

Feb. 27, '08. Condition little changed. Tongue tremor questionable. Discharge from nose a little less profuse, seemingly.

Feb. 28, '08. Brighter. Eats with some avidity. Barely perceptible tongue tremor.

Mar. 2, '08. Much better, gaining in weight. Eyes clear, nasal discharge has ceased. Faint fibrillary tremors of tongue and occasionally also of temporal muscles.

190 *Auto- and Isotransplantation of Parathyroid Glandules.*

Mar. 20, '08. Dog increasing in size. Myxœdema (?). Mucous membranes pale; slight tongue tremors. Appetite good.

Mar. 30, '08. No conspicuous change in condition.

Apr. 4, '08. Tongue tremor not observable to-day. The myxœdema has been increasing.

Apr. 9, '08. Seems quite well. Is awkwardly and unpleasantly plump. No tremors.

Apr. 23, '08. Hair becoming somewhat thinner.

June 11, '08. Myxœdema has increased. Hair is beginning to fall out. State of health apparently unchanged. Transferred to Drs. Voegtlin and Strouse for the summer, who will later report the results of their observations, and of their experiments with three of the myxœdematous dogs of this series.

Dog No. 9. Feb. 6, 1908. *Operation I.* Autotransplantation. Right internal glandula parathyroidea planted behind musculus rectus abdominis. The superior glandula parathyroidea is very small indeed and in two parts. The right thyroid lobe was excised.

Mar. 24, '08. Autotransplantation behind left rectus of a low-lying superior glandula parathyroidea. A second left glandula parathyroidea was very near the one removed, on the outer surface of the thyroid lobe, below its middle. Left parathyroidectomy. Dog is reduced to the two transplanted parathyroid glands.

Mar. 25, '08. Dog seems unaffected by the operation. Is as lively as ever.

Mar. 26, '08. About as usual. Faint tongue tremors.

Mar. 27, '08. Tongue tremor seen only at times and with difficulty.

Mar. 30, '08. Slight tongue and also temporal tremors. Dog not so well.

Apr. 1, '08. Better. No signs of parathyroid privation.

Apr. 4, '08. In unusually good spirits. No tremors.

May 9, '08. Seems very well. No tremors. Has gained in size.

May 23, '08. Abnormally stout. Myxœdema (?).

June 11, '08. Increasing in size. No tremors. Health seems good. Transferred to Drs. Voegtlin and Strouse for the summer.

Dog No. 10. An old dog. Feb. 10, 1908. *Operation I.* Autotransplantation. Right superior glandula parathyroidea transplanted into præperitoneal pocket, just above umbilicus. Excision of right thyroid lobe (right parathyroidectomy). The transplanted body is so large that I questioned for a time its nature but finally decided that it must be a parathyroid gland. Its edge was characteristically sharp, and, a little softer than usual, it resembled in consistence and form the human glandule.

Feb. 27, '08. *Operation II.* The left internal glandule was transplanted præperitoneally in the middle line below the navel. The left superior glandula parathyroidea is very small. Left panthyroidectomy. Dog is now reduced to the two transplanted glandules.

Feb. 28, '08. Faint tongue and temporal tremors.

Feb. 29, '08. No tremors observed.

Mar. 1, '08. No tremors.

Mar. 2, '08. No tremors. Wounds healed *per primam*. Dog better.

Mar. 5, '08. A. M. Dog jumps about quite happily in his cage and seems

fairly well. P. M. Dog is very ill. Has general muscular twitching and presents the picture of tetania parathyreopriva.

Mar. 6, '08. Dog died during night. *Autopsy*. Made and dictated by Dr. Hennington. Heart and lungs normal. On opening the peritoneal cavity an extravasation of blood into the omentum was observed and, on more complete exposure, a large round worm (*Eustrongylos gigas* or *Dioctophyme renale* (?)), 90 cm. long and 1 cm. in diameter, presented itself free in the peritoneal cavity in the neighborhood of the spleen. It was still alive and on being placed in warm water, executed slight movements. The intestinal peritoneum was thickened and granular-looking. The parietal peritoneum presented in places small, indefinitely circumscribed, roughened areas. More careful examination of the omentum showed that the extravasated blood followed the ramifications of the blood vessels. The liver presented on its surface whitish nodules one to three millimeters in diameter. On section there seemed to be a great increase of fibrous tissue in this organ. The surface of the spleen was slightly roughened; pancreas apparently normal. Stomach dilated with gas. The intestines, large and small, showed no abnormality. Mesenteric glands enlarged. Kidneys quite normal in appearance. The transplanted parathyroids were much changed in appearance and probably necrotic.

The remarkably sudden and very late appearance of the tetany in the above described dog is worthy of comment. This dog was aged. The dogs of this series were, with the exception of this one, quite young—estimated between one and two years of age.

Dog No. 11. Feb. 10, 1908. *Operation I*. Autotransplantation. The right superior glandula parathyroidea, rather small, was transplanted into the right rectus abdominis opposite the umbilicus.

Feb. 27, '08. Dog has been well since Operation I. *Operation II*. The left superior glandula parathyroidea imbedded about 3 mm. below the upper pole of the thyroid, was transplanted through the fibers of the left rectus abdominis muscle on the posterior sheath of this muscle. Excision of entire left thyroid lobe. The dog is, presumably, reduced to the two transplanted parathyroid glands.

Feb. 28, '08. No tremors.

Feb. 29, '08. No tremors.

Mar. 2, '08. No tremors. Dog seems fairly well.

Mar. 30, '08. Dog has been, apparently, perfectly well since last note.

Apr. 23, '08. Well. Has gained considerably in weight.

June 11, '08. *Operation III*. The autoplants were very thoroughly searched for and only the left one found. This little body did not shimmer through the peritoneum as the transplanted bodies usually do but, projecting slightly, could be felt as a hard round nodule. On section it presented a kind of hilus of connective tissue, and at the cortex five minute brownish dots, separated from each other by a little fibrous tissue, were seen. These dots had the color which seems to characterize the transplanted thyroid and parathyroid glands which have been

partially absorbed and invaded by connective tissue. I have already described this color as a little less red than the normal and as having a browner tinge with a suggestion of yellow.

The dog died of tetania parathyreopriva on the second (or third?) day after the third operation, the operation of functional test.

June 16, '08. *The autoplant has been very carefully cut and all the sections preserved. They cover fifteen slides. On each slide are ten sections. Parathyroid tissue appears in none of the sections except those mounted on slides, Nos. 14 and 15, and in all of these (vid. Plate II).*

This case is of particular interest proving, as it does, that a very minute piece of parathyroid gland may be sufficient to prevent all objective symptoms of hypoparathyroidism.

Of the macroscopically visible brownish-red dots of the successfully transplanted autograft, the largest proved on microscopic examination to be a fragment of thyroid gland; the smaller dots, barely to be seen with the naked eye, were portions of parathyroid gland, discrete, and separated from each other by strands of connective tissue. The largest of the parathyroid dots is the one depicted so beautifully by August Horn in Plate II. The microscope revealed one or two minute areas of parathyroid tissue, too small to have been detected macroscopically. I regret that there is not time for the making of low-power drawings from these sections.

ISOTRANSPLANTATIONS.

Dog No. 12. March 3, 1908. *Operation I.* Transplantation of the right external and internal parathyroid glands from Dog No. 13 behind the right musculus rectus abdominis, just above the umbilicus. The right superior glandula parathyroidea from this dog was transplanted behind the right rectus of Dog No. 13. Right parathyroidectomy.

Mar. 6, '08. Dog has been well since operation. Is naturally vicious and inclined to bite, hence difficult to examine. No tongue tremors.

Mar. 10, '08. Has been well since last note. 2.30 P. M. *Operation II.* Completed the isotransplantation with Dog 13.

Mar. 11, '08. Dog fairly well but so vicious that a careful examination was not made.

Mar. 12, '08. 9 A. M. Dog is very ill. General twitchings. Calcium lactate administered per stomach tube by Dr. Voegtlin. 4 P. M. Dog wonderfully better. There are no demonstrable twitchings.

Mar. 16, '08. Has been treated daily by Dr. Voegtlin with calcium lactate. Dog still suffers from tetany, partially controlled, however, by the drug.

Mar. 19, '08. Slight fibrillary tremors of the tongue still present but animal looks badly and refuses food.

Mar. 21, '08. Little change in dog's condition. Still refuses food and has faint tongue tremors. No general tremors observed. Calcium lactate discontinued.

Mar. 23, '08. Dog is dead. *Autopsy.* Entirely negative. A few drops of pus were found in the neck wound in mid-line under the skin. There was no trace of the parathyroid gland first transplanted. The second isoplant was necrotic.

Dog No 13. Mar. 3, '08. Isotransplantation with Dog 12. Died of pneumonia two days after the final transplantation.

Dogs Nos. 12, 13, 15, 16, 17, 18, 19, 20, 21, 22, 23, 24, 25, 26, 27 and 28 were employed for isotransplantation experiments and in no instance with success. The dogs were taken in twos and the transplantations made as described for the pair Nos. 12 and 13. In no instance did privation symptoms appear after one-sided panthyroidectomy, but they always supervened on removal from the neck of the final parathyroid gland unless pneumonia carried off the dogs before the tetany had time to develop. The transplanted bodies were absorbed (usually leaving a trace of pigment at the site of the transplantation), or partially absorbed or simply necrotic in accord with the time elapsed after the transplantation. Calcium lactate, which was of such great assistance in several of the cases of autotransplantation, did not suffice to prolong, for more than a few days, the lives of the dogs wholly dependent upon the isografts. To Dog No. 12, developing tetany on the second day after the final isotransplantation, Dr. Voegtlin gave the calcium lactate for nine days, and with great improvement at first; but the animal died of tetany on the tenth day after its incidence.

Results (Winter of 1907-1908); Autotransplantation in or behind the Musculus Rectus Abdominis.—Of eighteen autotransplantations in 12 dogs, 7 parathyroids were absorbed or necrotic (Dogs Nos. 3, 4, 5 and 10); 5 to 7 lived and performed their function (Dogs Nos. 1, (2?), 7, 8, 9 and 11)—in Dog No. 2 for a very short time. In only one instance have we observed the survival of two grafts in one animal whether the transplantation was made in the thyroid, the spleen, or behind the rectus muscle. In the exceptional case the dog died on the ninth day of distemper, without symptoms of tetany. The autografts were very much smaller than when transplanted (vid. history of Dog No. 2).

In Dogs Nos. 7 and 11 the functional test was made. On removal of the sustaining autograft both died promptly of tetania parathyreopriva. In Dog 7, on the development of tetany, isografting was tried without success. Three isografts were placed. Dogs Nos. 8 and 9 still await the functional test. The former is sustained by the one autograft, transplanted February 6, 1908, nine months ago. The latter has been reduced to one or other or both of his autografts since March 24, 1908, a period of seven months. Dog No. 8 has been myxœdematous for about eight months. The myxœdema seems to be hardly as pronounced now (November, '08) as it was in June. Dog No. 9 is only slightly myxœdematous, at least as compared with Dog No. 8. Both have an eczema, dependent, probably, upon the thyroid privation. The falling out of hair has not been great. Neither dog on his return to the laboratory yesterday, November 3, 1908, manifested any of the signs of tetania parathyreopriva.

Isotransplantation in or behind the Musculus Rectus Abdominis.
—Of 35 isotransplantations in 17 dogs with created deficiency (Dogs Nos. 7, 12, 13, 15, 16, 17, 18, 19, 20, 21, 22, 23, 24, 25, 26, 27 and 28), thirty-two parathyroids were either absorbed or necrotic. Three were transplanted only twenty-four hours before the death of Dog (No. 7). In this case isotransplantation (two grafts) was unsuccessfully resorted to twenty-four hours after the supervention of tetany. Deprived of all parathyroids except the one transplanted (an autograft), this dog lived in good health and spirits for twenty-five days, or until, at a final operation, the sustaining parathyroid was removed. There was in this dog, at times, a suggestion of hypoparathyroidism in a barely perceptible fibrillary tremor of the tongue and of the temporal muscles. On removal of the perfectly normal autograft (vid. Plate I) behind the rectus muscle, tetany developed within twenty-four hours. The following day the isografting was made, and without result, as stated (vid. history of Dog No. 7).

We have not as yet determined that one tissue or site is better than another for the transplantation, and do not even know that parathyroid glandules deprived of their blood supply in the course of operation or by experimentation might not, in some cases at

least, survive if left undisturbed in the original situation in the neck. Inasmuch, however, as drainage is usually employed in thyroid lobectomy, and the drain usually carried to the precise situation of the parathyroids, to the deepest part of the wound, the better site for the transplantation of the glandules would be the opposite lobe of the thyroid gland.

Dr. W. L. Moss has very kindly tested the sera of a number of the dogs used in the experiments of isotransplantation. Reactions such as hemolysis and agglutination have not been obtained.

GENERAL CONSIDERATION.

Isotransplantations without created deficiency were made into the thyroid gland and into the spleen and were uniformly unsuccessful. In the isotransplantations with created deficiency the grafts were, with few exceptions, placed behind the *musculus rectus abdominis*. In not a single instance in our experience has an isograft lived. An autotransplantation entails necessarily, at least for a time, a deficiency of some degree. When the loss has been of two parathyroids only, as in one-sided panthyroidectomy, the grafts have invariably and promptly been absorbed (Dogs G, 3, 4, 5, 6 and 10). In other words, all the autotransplantations made at the first operation, at which the parathyroid glandules of one side only were excised have failed. In two instances (Dogs 7 and 8) the autograft transplanted at the first operation survived, but in each case a prolonged search for the glandules was made on both sides of the neck at this operation and so great a degree of parathyroid privation brought about that both dogs were ill with symptoms of hypoparathyroidism, presumably in consequence of the damage done to the circulation of the unexcised parathyroid bodies. Dog 7 was used for the functional test, and Dog 8 has been sustained nine months by one parathyroid glandule; he still lives and, except for myxœdema of a very pronounced type, seems in good health. In the two instances in which to the present time operation for the functional test has been made, a living autoplant has been found; in one of these it was the glandule transplanted at the second operation after complete thyroid privation (Dog 11); in the other, although the first,

it was the only graft, and had been transplanted, as I have said (vid. history of Dog 7), after an operation so destructive to the parathyroid bodies as to cause tetany. In another of the successfully grafted dogs (Dog 1), which died during my summer vacation from cause other than tetany (autopsy by Dr. Voegtlin) it was probably the second and not the first graft that lived because the dog had very severe tetany after Operation II and would have died, we thought, if calcium lactate had not been given for several days. Such severe tetany we have seen only after complete parathyroid privation. A mild degree of tetany might conceivably be induced by anæsthetization and operation even though one parathyroid glandule were in a measure performing its function.

Two dogs, with myxœdema, await the functional test (Nos. 8 and 9). In the case of Dog 9, alive and in good health except for thyroid deficiency (slight myxœdema) and sustained by one parathyroid body for the past seven and one-half months, it has not been determined which one of the two autografts survives. That he has slight symptoms of tetany following the second operation does not enable us to arrive at a conclusion, for with only one parathyroid glandule, and that a graft, such slight manifestations of hypoparathyroidism might not only appear after anæsthetization and operation but even persist, as our observations have taught us (Dogs 1, 7 and 8), for months.

In the light of the work of last winter, the re-study of the experiments of the year preceding strengthens the view that a considerable degree of deficiency is essential to the success of the transplantations. For, of the autotransplantations into the thyroid gland and spleen, only those were successful in which as many as three glandules were excised. In the single case of autotransplantation into the thyroid gland in which the deficiency did not exceed one-half of the normal parathyroid supply (Dog G), both autografts, searched for not until three months and twenty days after their transplantation, were completely absorbed.

In only one instance of autotransplantation were all of the parathyroid bodies excised at one operation. In this case (Dog E) the four grafts were placed in the spleen. Death from tetany occurred on the third day after the operation. It is possible that

calcium lactate might have rescued this dog from the list of failures; but the experiment was made in the year preceding this very important discovery of MacCallum and Voegtlin. That this salt was of great service to us in several cases, converting failure into success, there can be little doubt; and hence the query, is not success more likely to attend transplantations in animals such as rats, which may for a long time (weeks or even months), and in a state of chronic hypoparathyroidism, survive total loss of the parathyroid tissue, than in dogs which so commonly succumb before the end of the third day when the parathyroid privation is complete? For the success, then, of the transplantation of a completely extirpated organ the animal must be able to survive the total privation long enough for the grafts to acquire a circulation sufficient for, at least, a partial exercise of their function, unless chemical or other assistance be rendered. If death might be expected to follow complete privation of an organ furnishing an internal secretion, within say twenty-four hours, successful grafting might be impossible unless the period necessary for the "taking," or "catching" of the graft could be bridged over by the administration of doses of the missing gland, or of its chemical equivalent. It is significant that pneumonia occurred only in dogs whose parathyroid glandules had been totally excised.

The experiments have not been, in number, sufficient to establish as fact the necessity for creating a deficiency, but they lend strong support to this view. It is conceivable that the organism may sustain of transplanted parathyroid tissue only enough to prevent symptoms of privation or to preserve life and not an amount sufficient for the maintenance of perfect health. Is it then worth while in the human subject to transplant a parathyroid removed or injured in single thyroid lobectomy, which creates at most only a moderate degree of insufficiency and not enough perhaps to make probable the success of the grafting? What may be true of dogs need not be true of human beings. Nor can we know in a given case that the parathyroids are four in number, of equal size, and regularly distributed. The transplantation into the opposite lobe after thyroid lobectomy would require but a few moments, and should, in my opinion, not be neglected when a parathyroid body has been

cut off from its blood supply. A glandule removed in the course of operation upon the second lobe (an accident which will rarely occur in the future) might, we believe, be more likely to survive transplantation than a glandule excised at the first operation, but only in case parathyroid privation, sustained for sufficient time, had been brought about by the original lobectomy.

SUMMARY.

1. The autotransplantation of parathyroid glandules into the thyroid gland and behind the musculus rectus abdominis has been successful in sixty-one per cent. of the cases in which a deficiency greater than one-half has been created.

2. In no instance has the autotransplantation succeeded without the creation of such deficiency.

3. Isotransplantation has been uniformly unsuccessful.

4. Parathyroid tissue transplanted in excess of what is urgently required by the organism has not lived.

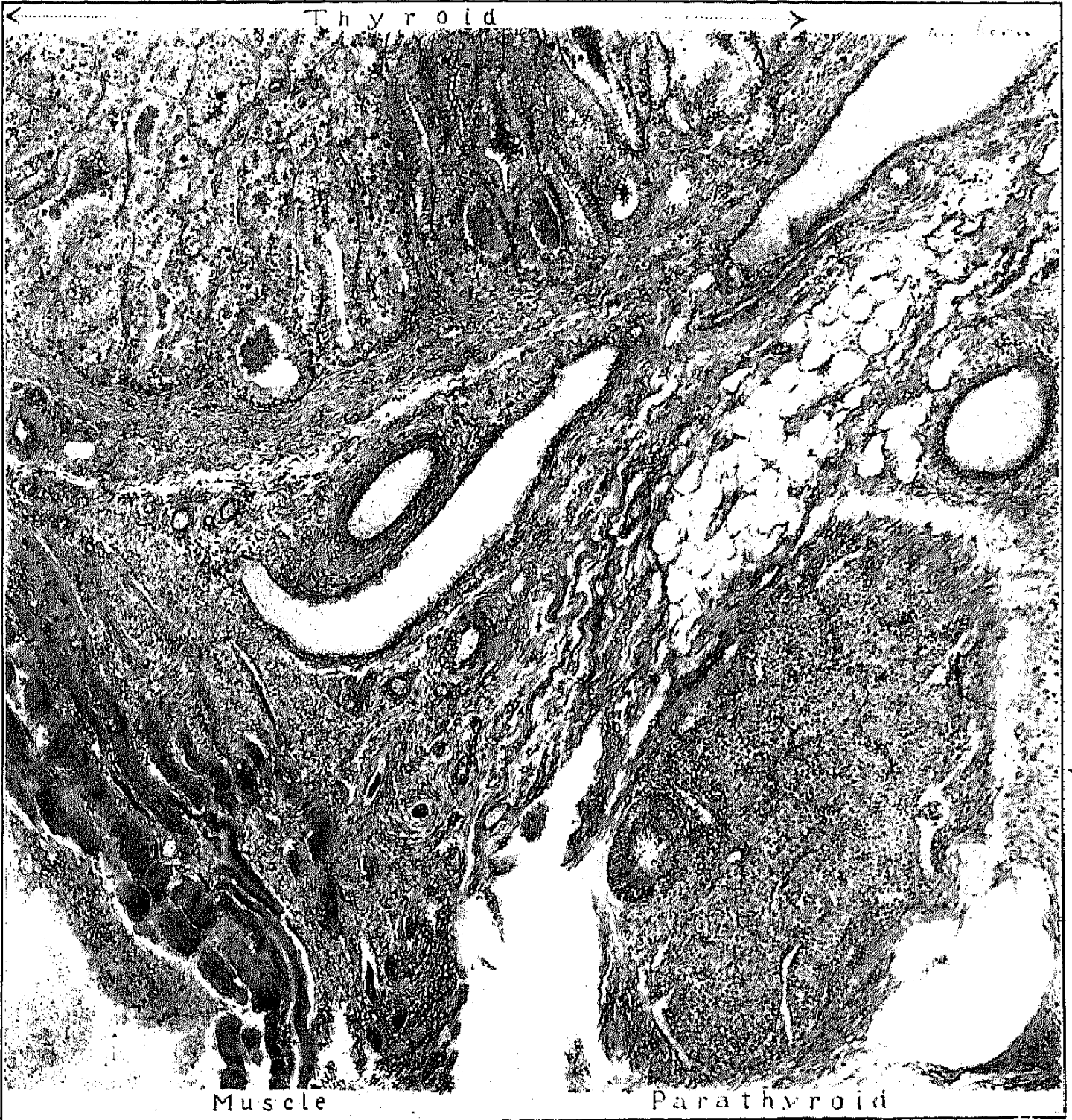
5. One parathyroid autograft may suffice to maintain the animal in good health and spirits for many months and possibly for years.

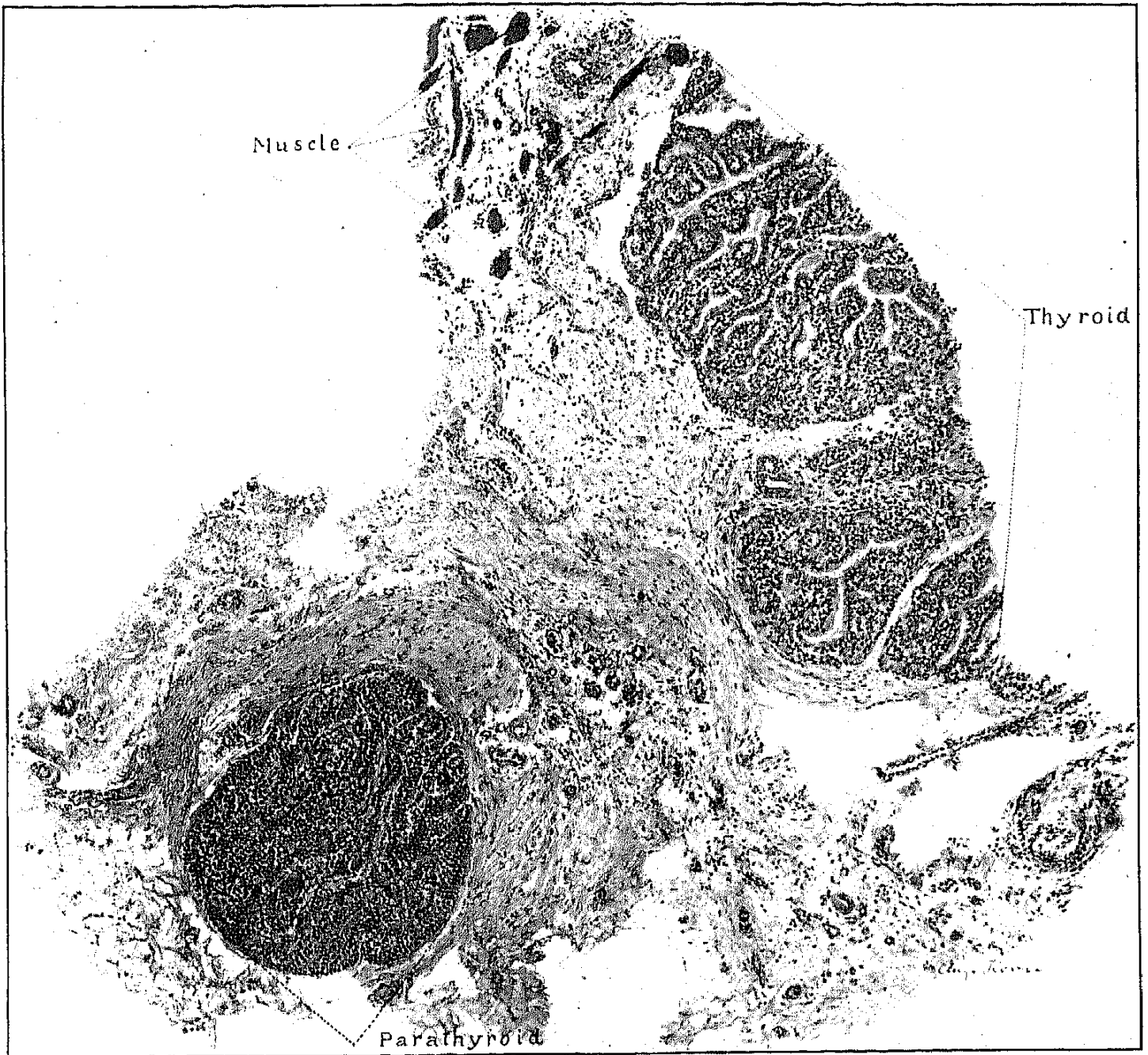
6. Excised or deprived of their blood supply in the course of operation upon the human subject, parathyroid glands should, in the present state of our knowledge, be grafted, and probably into the thyroid gland.

7. Complete excision of the thyroid lobes in dogs may be well borne for a year or more. The myxœdema which usually has manifested itself within a few weeks has not increased after the first few months. May it subsequently diminish with the hypertrophy of accessory thyroids?

8. Parathyroid tissue is essential to the life of dogs, as has been conclusively proved by the result of excision of the sole, sustaining graft.

There may be found, perhaps, in our experiments, explanation of the fact observed by others (Enderlen, Payr) that, when transplanted, thyroid preserves its integrity less well than parathyroid tissue. In the instances recorded the amount of thyroid gland excised may have been insufficient to make possible the fullest success of the transplantation; and particularly so when we consider the extent of the hypertrophy of which the thyroid gland seems capable.





EXPLANATION OF PLATES.

PLATE II. Enlarged 125/1. The autograft from Dog No. 7, excised at the operation of functional test, one month after its transplantation. Death from tetany promptly followed its excision.

PLATE III. Enlarged 90/1. The autograft from Dog No. 11, excised at the operation of functional test, four months after its transplantation. Death from tetania parathyreopriva promptly followed its excision.