



Invasive *Scedosporium* spp. and *Lomentospora prolificans* infections in pediatric patients: Analysis of 55 cases from FungiScope® and the literature



Danila Seidel^{a,b,*}, Angela Hassler^c, Jon Salmanton-García^{a,b}, Philipp Koehler^{a,b}, Sibylle C. Mellinghoff^{a,b}, Fabianne Carlesse^d, Matthew P. Cheng^e, Iker Falces-Romero^f, Raoul Herbrecht^g, Alfredo Jover Sáenz^h, Nikolai Klimkoⁱ, Mihai Maresş^j, Cornelia Lass-Flörl^k, Pere Soler-Palacín^l, Hilmar Wisplinghoff^{m,n,o}, Oliver A. Cornely^{a,b,p}, Zoi Pana^q, Thomas Lehrnbecher^c

^a Cologne Excellence Cluster on Cellular Stress Responses in Aging-Associated Diseases (CECAD), University of Cologne, Cologne, Germany

^b University of Cologne, Faculty of Medicine, Department I of Internal Medicine, European Excellence Center for Medical Mycology (ECMM), Cologne, Germany

^c Pediatric Hematology and Oncology, Hospital for Children and Adolescents, University Hospital, Goethe University, Frankfurt, Germany

^d Instituto de Oncologia Pediátrica - GRAACC/UNIFESP, São Paulo, SP, Brazil

^e Montreal, McGill University, Department Microbiology and Immunology, Montreal, Canada

^f Clinical Microbiology and Parasitology Department, Hospital Universitario La Paz, IdiPaz, Madrid, Spain

^g University Hospital of Strasbourg, Hôpital de Hautepierre, Department of Oncology and Hematology, Strasbourg, France

^h Territorial Unit of Nosocomial Infection and antibiotic policy (TUNI), University Hospital Arnau de Vilanova, Lleida, Spain

ⁱ North-Western State Medical University named after I.I. Mechnikov, St. Petersburg, Russia

^j Laboratory of Antimicrobial Chemotherapy, Ion Ionescu de la Brad University, Iaşi, Romania

^k Medical University of Innsbruck, Institute of Hygiene und Medical Microbiology (HMM), Innsbruck, Austria

^l Pediatric Infectious Diseases and Immunodeficiencies Unit, Vall d'Hebron Barcelona Hospital Campus, Barcelona, Catalonia, Spain

^m Wisplinghoff Laboratories, Cologne, Germany

ⁿ Institute for Virology and Microbiology, University Witten/Herdecke, Witten, Germany

^o Institute for Medical Microbiology, University of Cologne, Cologne, Germany

^p Clinical Trials Centre Cologne (ZKS Köln), University of Cologne, Cologne, Germany

^q Department of Medicine, European University of Cyprus (EUC), Cyprus

ARTICLE INFO

Article history:

Received 17 October 2019

Received in revised form 10 December 2019

Accepted 12 December 2019

Keywords:

Scedosporium spp.

Lomentospora prolificans

Invasive fungal infections

Pediatric patients

Children

Voriconazole

Surgery

FungiScope® registry

ABSTRACT

Objectives: Current knowledge on infections caused by *Scedosporium* spp. and *Lomentospora prolificans* in children is scarce. We therefore aim to provide an overview of risk groups, clinical manifestation and treatment strategies of these infections.

Methods: Pediatric patients (age ≤ 18 years) with proven/probable *Scedosporium* spp. or *L. prolificans* infection were identified in PubMed and the FungiScope® registry. Data on diagnosis, treatment and outcome were collected.

Results: Fifty-five children (median age 9 years [IQR: 5–14]) with invasive *Scedosporium* spp. (n = 33) or *L. prolificans* (n = 22) infection were identified between 1990 and 2019. Malignancy, trauma and near drowning were the most common risk factors. Infections were frequently disseminated. Most patients received systemic antifungal therapy, mainly voriconazole and amphotericin B, plus surgical treatment. Overall, day 42 mortality was 31%, higher for *L. prolificans* (50%) compared to *Scedosporium* spp. (18%). *L. prolificans* infection was associated with a shorter median survival time compared to *Scedosporium* spp. (6 days [IQR: 3–28] versus 61 days [IQR: 16–148]). Treatment for malignancy and severe disseminated infection were associated with particularly poor outcome (HR 8.33 [95% CI 1.35–51.40] and HR 6.12 [95% CI 1.52–24.66], respectively). Voriconazole use at any time and surgery for antifungal treatment were associated with improved clinical outcome (HR 0.33 [95% CI 0.11–0.99] and HR 0.09 [95% CI 0.02–0.40], respectively).

* Corresponding author at: University of Cologne, Faculty of Medicine, Department I of Internal Medicine, European Excellence Center for Medical Mycology (ECMM), Cologne, Germany.

E-mail address: Danila.seidel@uk-koeln.de (D. Seidel).

Conclusions: *Scedosporium* spp. and *L. prolificans* infections in children are associated with high mortality despite comprehensive antifungal therapy. Voriconazole usage and surgical intervention are associated with successful outcome.

© 2019 University Hospital of Cologne. Published by Elsevier Ltd on behalf of International Society for Infectious Diseases. This is an open access article under the CC BY-NC-ND license (<http://creativecommons.org/licenses/by-nc-nd/4.0/>).

Introduction

Scedosporium spp. and *Lomentospora prolificans* (formerly known as *Scedosporium prolificans*) are ubiquitous molds (Chaya-kulkeeree et al., 2006). Although these fungi are not commonly pathogenic, they can cause severe disease, in particular among immunocompromised patients or subsequent to trauma or near-drowning accidents, due to contaminated soil or water (Cortez et al., 2008). Invasive infections caused by *Scedosporium* spp. or *L. prolificans* can affect all organs, and dissemination via the bloodstream is common (Cortez et al., 2008; Bhat et al., 2007; Rodriguez-Tudela et al., 2009). In addition, patients with cystic fibrosis frequently have colonized lungs predisposing to chronic lung infection that may become invasive and lifethreatening (Harun et al., 2010; Schwarz et al., 2017).

Treatment of *Scedosporium* spp. and *L. prolificans* infection is challenging due to intrinsic resistance to numerous antifungals (Cortez et al., 2008). Surgical debridement should be performed whenever feasible, and voriconazole is recommended as firstline antifungal treatment (Tortorano et al., 2014). Although *in vitro* results are promising, reports on the clinical benefit of combination therapy with terbinafine are inconsistent, and mortality rates remain high (Seidel et al., 2019; Jenks et al., 2018; McCarthy et al., 2018).

Current knowledge on infections with these pathogens predominantly is based on case reports and single-center reviews, particularly in the pediatric setting. We therefore aim to identify children with *Scedosporium* spp. and *L. prolificans* infections from the literature and the global FungiScope[®] registry to characterize pediatric specific risk factors, clinical manifestations and treatment strategies, which will hopefully improve the management of these patients.

Methods

Study population

Clinical data of patients ≤ 18 years with invasive *Scedosporium* spp. or *L. prolificans* infection were identified either through an electronic literature search in PubMed or in the FungiScope[®] registry. Patients with proven or probable infection were included in the analysis (De Pauw et al., 2008). If the respective culture was not available or unspecific but the fungal pathogen was confirmed by sequencing or matrix-assisted laser desorption ionization time-of-flight (MALDI-TOF), cases were included. FungiScope[®] is a global, retrospective registry for rare fungal infections, in which anonymized clinical information of patients is documented (Seidel et al., 2017). A literature search for case reports published in the past 30 years, since 1990, when liposomal amphotericin B was introduced (Ng and Denning, 1995), was performed in PubMed on June 1, 2019 using the search filter “(Scedospori* OR Pseudallescheri* OR Lomentospori*) AND (invasive OR disseminated OR infection) AND (child OR pediatric OR boy OR girl OR neonate OR newborn OR adolescent)”, resulting in 184 articles in English, French, German, Japanese, Spanish, and Turkish. Eligible cases were identified through the review of each publication, and article references were checked for additional cases (Supplementary Figure S1). Information extracted from the reported cases and the FungiScope[®]

database included demographic characteristics, causative fungal pathogen, underlying diseases, risk factors for invasive fungal disease, diagnostic tests, sites of infection, treatment (antifungal agents, length of treatment, concomitant use of antifungal agents, and surgical interventions, e.g. abscess drainage and surgical debridement), and clinical outcome. Cases were reviewed to eliminate duplicates. Patients were categorized as immunocompromised (e.g., patients with hematological malignancies, chronic granulomatous disease (CGD), hyper-IgE-syndrome or HIV/AIDS) or presumably immunocompetent (e.g., after trauma or near drowning, patients with cystic fibrosis were categorized as immunocompetent patients). Infection of the central nervous system (CNS) was considered disseminated disease, if no direct inoculation, e.g. during brain surgery or traumatic injuries, was suggested. Observation time was defined between first day of signs or symptoms of invasive fungal disease and day of last contact. For the comparison of one-year survival between cases reported in FungiScope[®] with those from the literature, we performed a matched analysis using R applying the following matching criteria: (I) Immunocompromised with allogeneic hematopoietic stem cell transplantation (HSCT), immunocompromised other, and immunocompetent; (II) Severe infection (blood, CNS, disseminated with lung involvement), localized lung infection, and other “non-severe” infection (localized skin, deep soft tissue, joint infections); (III) Surgery for IFI treatment; (IV) Causative pathogen.

Statistical analysis

Statistical analyses were performed using SPSS 25 (IBM Corp., USA). Categorical and continuous variables were compared by Fisher's exact or Mann-Whitney U test. The Kaplan-Meier estimator was used to compare survival between groups. To identify independent predictors of survival, simple and multivariable logistic regression models were performed. Associates of survival with a *P* value of ≤ 0.1 in their respective simple logistic regression models and clinically relevant variables were entered into the multivariable Cox regression model. Final multivariable model was established using the backward elimination method, based on the significance of each variable to estimate hazard ratios (HR) and 95% confidence interval (CI). *P* value ≤ 0.05 was considered statistically significant if not stated otherwise. Median observation time and treatment duration were calculated using median and interquartile ranges (IQR).

Results

Patient populations

Fifty-five pediatric patients (17 girls, 38 boys) with invasive *Scedosporium* spp. ($n = 33$, 60%) or *L. prolificans* ($n = 22$, 40%) infection reported since 1990 were identified in the literature ($n = 44$) and FungiScope[®] ($n = 11$, two published (Holle et al., 2014; Jover-Saenz et al., 2016)) (Abzug and Walsh, 2004; Acharya et al., 2006; Barbaric and Shaw, 2001; Bhagavatula et al., 2014; Bonduel et al., 2001; Chakraborty et al., 2005; Chen et al., 2014; Chiam et al., 2013; Cruysmans et al., 2015; Dalton et al., 2006; Gatto et al., 1997; Gompels et al., 2002; Hachimi-Idrissi et al., 1990; Hell et al., 2011; Holle et al., 2014; Jabado et al., 1998; Jover-Saenz et al., 2016; Kesson et al., 2009; Klopfenstein et al., 2003; Lee et al., 2018;

Madriral et al., 1995; Marques et al., 2011; Matlani et al., 2013; Messori et al., 2002; Mursch et al., 2006; Nielsen et al., 1993; Penteadó et al., 2018; Pickles et al., 1996; Romero Gomez and Garcia Rodriguez, 2010; Ruchel and Wilichowski, 1995; Slack et al., 1999; Sobottka et al., 1999; Song et al., 2011; Sparrow et al., 1992; Steinbach et al., 2003; Stripeli et al., 2009; Studahl et al., 2003; Sydnor et al., 2003; Tapia et al., 1994; Vazquez-Tsuji et al., 2006; Whyte et al., 2005; Wilichowski et al., 1996; Wood et al., 1992; Zarkovic and Guest, 2007). Cases were reported from 21 countries without evidence for endemic occurrence of the infection (Europe [n = 26], North America [n = 8], South America [n = 4], Asia [n = 5], Oceania [n = 12]) (Supplementary Figure S2). Median patient age was 9 years (range 1.3–18, IQR: 5–14), and did not significantly differ between patients with *Scedosporium* spp. and *L. prolificans* infection ($P = 0.188$) (Table 1, Supplementary Table S1). Most fungal infections were proven (n = 49, 89%), based on a positive culture of tissue material in most cases, blood, abscess aspirate or other sterile sites in the respective cases. One patient with diagnosis based on positive PCR 18S rRNA results from broncho-alveolar lavage sample and another for which blood culture was inconclusive but *Lomentospora prolificans* was identified using MALDI-TOF were also included in the study as probable infection. Post-mortem diagnosis was made in four patients with *Scedosporium* (three with CNS infection, one with skin lesions) and two *Lomentospora*-related infection (one with positive culture from blood collected before death and the other based on repeatedly positive counter-immunoelectrophoresis results). In 33 children with *Scedosporium* spp. infection, the causative pathogens were *S. apiospermum*, *S. boydii* and *S. dehoogii* in 23 (70%), seven (21%) and one (3%) patients, respectively. In two patients, the fungus was not

identified to the species level. One patient with an *L. prolificans* infection had a coinfection with *Scedosporium apiospermum* and *Lichtheimia* spp., another with *Aspergillus fumigatus*.

Among the 55 children, about half of the patients (n = 29, 53%) were presumably immunocompetent at the time of infection, which mostly occurred after trauma in both groups or was associated with near drowning or cystic fibrosis in the *Scedosporium* spp. group. In three patients no underlying conditions was identified. Twenty-six children (47%) were considered immunocompromised at the time of infection, with a slightly higher proportion in children with *L. prolificans* than with *Scedosporium* spp. infection (n = 13, 39% versus n = 13, 59%, $P = 0.178$). The majority of immunocompromised patients had an underlying hematological and oncological disease and were receiving chemotherapy and/or underwent HSCT (n = 18, 33%) prior to the fungal infection (Table 1). Acute myelogenous and lymphocytic leukemia accounted for 6 (11%) and 5 (9%) cases, respectively. Three patients (5%) had aplastic anemia, and others received treatment for retinoblastoma, advanced neuroblastoma, Burkitt lymphoma or chronic myelogenous leukemia.

Sites of infections and clinical symptoms

Disseminated infection occurred in 22 patients (40%), similar to patients with infection due to *Scedosporium* spp. and those due to *L. prolificans* (n = 12 [36%] versus n = 10 [45%], $P = 0.580$), overall more often in immunocompromised patients than in immunocompetent patients (12/26 [46%] versus 10/29 [35%], $P = 0.420$) (Table 1). Bone/joints, lungs, central nervous system (CNS), and blood were the most frequent affected sites overall (27%, 27%, 20%, and 18%, respectively) (Table 1). The lungs were affected in both

Table 1
Patient and infection characteristics of 55 children with *Scedosporium* spp. and *Lomentospora prolificans* infection.

	All patients N = 55	<i>Scedosporium</i> spp. N = 33	<i>Lomentospora prolificans</i> N = 22	P value
Male (%)	38 (69)	22 (67)	16 (73)	0.769
Median age, years	9	10	8	0.188
range	1.3–18	1.3–18	3–17	
IQR	5–14	7–15	5–11	
Proven (according to EORTC/MSG criteria)	49 (89)	27 (82)	22 (100)	0.071
Predominant underlying condition, N (%)				
Immunocompromised patients ^o	26 (47)	13 (39)	13 (59)	0.178
Malignancy	18 (33)	6 (18)	12 (55)	0.008 *
Chemotherapy	17 (31)	6 (18)	11 (50)	0.097
HSCT	6 (11)	3 (9)	3 ¹ (14)	1.000
Primary immunodeficiency ²	6 (11)	5 (15)	1 (5)	0.384
HIV/AIDS	2 (4)	2 (6)	0 (0)	0.480
Febrile Neutropenia	8 (15)	2 (6)	6 (27)	0.202
Immunocompetent patients	29 (53)	20 (61)	9 (41)	0.178
Trauma	15 (27)	7 (21)	8 (36)	0.014 *
Cystic fibrosis	4 (7)	4 (12)	0 (0)	0.280
Near drowning	7 (13)	7 (21)	0 (0)	0.066
No risk factor identified	3 (6)	2 (6)	1 (5)	1.000
Sites of infection, N (%) ^o				
Blood	10 (18)	3 (9)	7 (32)	0.070
Brain	11 (20)	10 (30)	1 (5)	0.036 *
Eye	4 (7)	3 (9)	1 (5)	0.642
Paranasal sinuses	2 (4)	2 (6)	0 (0)	0.511
Lung	15 (27)	10 (30)	5 (23)	0.758
Abdominal	4 (7)	0 (0)	4 (18)	0.021 *
Bone/joint	15 (27)	5 (15)	10 (46)	0.028 *
Skin/deep soft tissue	9 (16)	3 (9)	6 (27)	0.134
Disseminated ³	22 (40)	12 (36)	10 (45)	0.580

P values (*Scedosporium* spp. vs *Lomentospora prolificans* cases).

^oNumbers are super-additive.

IQR interquartile range.

¹ Allogeneic (2), Autologous (1); 1 allogeneic HSCT for treatment of chronic granulomatous disease.

² *Scedosporium* spp.: Chronic granulomatous disease (4), Hyper IgE Syndrome (1); *Lomentospora* spp.: Chronic granulomatous disease (1).

³ Includes: Fungemia, central nervous system infection if not caused by direct implantation, and infections at two or more non-contiguous anatomic sites; 1 *Scedosporium* spp. infection of spine.

groups with similar frequency. Patients with *L. prolificans* compared to children with *Scedosporium* spp. infection presented three times more frequently with fungemia ($P = 0.07$), bone/joint infection ($P = 0.028$), and skin/deep soft tissue infection ($P = 0.134$). Abdominal infections were caused by *L. prolificans* only ($n = 4$), all in severely ill patients treated for underlying malignancy. Except in one of these cases, where *L. prolificans* caused a necrotizing enterocolitis and the infection progressed to the kidneys, the patients had disseminated disease with positive blood cultures; only one survived. CNS infections were mainly caused by *Scedosporium* spp. ($n = 10$ [30%] versus $n = 1$ [5%] caused by *L. prolificans*). Six of the 11 cases (55%) with CNS infection were associated with near drowning accidents. The lungs were affected in all patients with cystic fibrosis, whereas bone and joint infections were mainly associated with traumatic injuries (9/15, 56%). Seven out of ten children with fungemia had at least one additional organ affected. Eye infections were less common, and associated with traumatic injuries (3 of 4 cases).

Fever at the time of diagnosis of invasive fungal disease was frequently reported ($n = 35$, 64%). For eight (32% of the immunocompromised) patients febrile neutropenia was noted (Table 1). Clinical symptoms were mostly associated with the site

of fungal infection, e.g., neurological symptoms were seen on 10/11 children (91%) with CNS infection and pulmonary signs such as chest pain, dyspnea and cough in 10/15 patients (67%) with lung involvement (data not presented).

Treatment and outcome

Independent of the causative organism, the majority of patients received antifungal agents (53/55, 96%) and were treated surgically (34/55, 62%) (Table 2). Specifically, surgical interventions were performed in all patients with bone and joint infection, in six out of eleven patients with CNS infection (abscess drainage) and in three out of four patients with eye infection (vitrectomy in two, corneal transplantation in one). Overall, immunocompetent patients were more often surgically treated than immunocompromised patients (22/29 [76%] versus 13/26 [40%], $P = 0.056$). The 13 immunocompromised patients without surgery died in a median of after 6 days (IQR: 3–28), eight had severe disseminated disease, five with blood stream infection due to *L. prolificans*. Voriconazole and amphotericin B were the most frequently administered antifungals, similar to patients with *Scedosporium* spp. and *L. prolificans* infection (Table 2). In contrast, terbinafine was more often used in children with *L.*

Table 2
Antifungal therapy of *Scedosporium* spp. and *Lomentospora prolificans* infections in 55 children.

N (%)	All patients N = 55	<i>Scedosporium</i> spp. N = 33	<i>Lomentospora prolificans</i> N = 22
Treatment strategy			
Antifungals only	19 (35)	8 (24)	11 (50)
Antifungals and surgery	33 (60)	23 (70)	10 (46)
Antifungals and CVC removal	1 (2)	1 (3)	0 (0)
Surgery only	1 (2)	1 (3)	0 (0)
No treatment	1 (2)	0 (0)	1 (5)
Antifungal prophylaxis			
Azole ¹	5 (9)	4 (12)	1 (5)
Antifungals administered ^o			
Amphotericin B	30 (55)	18 (55)	12 (55)
Itraconazole	19 (35)	10 (30)	9 (41)
Posaconazole	2 (4)	2 (6)	0 (0)
Voriconazole	32 (58)	21 (64)	11 (50)
Terbinafine	9 (16)	2 (6)	7 (32)
Echinocandin ^{2, o}	7 (13)	3 (9)	4 (19)
Other antifungals ^{3, o}	15 (27)	11 (33)	4 (18)
Monotherapy	16 (21)	8 (24)	8 (36)
Amphotericin B	3 (19)	0 (0)	3 (38)
Voriconazole	8 (50)	7 (88)	1 (13)
Other ⁴	5 (31)	1 (12)	4 (50)
Sequential monotherapy ^{5, o}	14 (25)	12 (36)	2 (9)
Amphotericin B	6 (43)	5 (42)	1 (50)
Voriconazole, other azoles ⁶	8 (57)	7 (58)	1 (50)
Combination therapy ^{7, o}	33 (55)	20 (61)	13 (59)
Terbinafine + azole ⁸	10 (30)	2 (10)	8 (62)
Voriconazole + other ⁹	9 (27)	6 (30)	3 (23)
Amphotericin B + other ¹⁰	12 (36)	10 (50)	2 (15)
Other combination ¹¹	2 (6)	2 (10)	0 (0)
Median treatment duration, days (IQR) ¹²	88 (28–344)	92 (56–368)	36 (15–205)

^oNumbers are super-additive.

¹ *Scedosporium* spp.: fluconazole (1), itraconazole (1), posaconazole (1), posaconazole + voriconazole (1); *Lomentospora prolificans*: voriconazole (1).

² *Scedosporium* spp.: caspofungin (3); *Lomentospora prolificans*: caspofungin (3), micafungin (1).

³ *Scedosporium* spp.: fluconazole (2), 5-flucytosine (3), miconazole (3), isoconazole (1), saperconazole (1); *Lomentospora prolificans*: fluconazole (2), 5-flucytosine (1), multifosine (1).

⁴ *Scedosporium* spp.: itraconazole (1); *Lomentospora prolificans*: itraconazole (3), fluconazole (1).

⁵ Sequential mono: 15 administered agents in 7 patients (*Scedosporium* spp. (6), *Lomentospora prolificans* (1)).

⁶ *Scedosporium* spp.: voriconazole (3), itraconazole (2), miconazole (2); *Lomentospora prolificans*: itraconazole (1).

⁷ 33 combinations in 30 patients (*Scedosporium* spp. (18), *Lomentospora prolificans* (12); two different combinations in 2 *Scedosporium* cases and 1 *Lomentosporacase*);

Switch from mono- to combination therapy: In 8 *Scedosporium* spp. and 7 *Lomentospora prolificans* cases.

⁸ *Scedosporium* spp.: Terbinafine with voriconazole (2); *Lomentospora prolificans*: Terbinafine with voriconazole (7) and itraconazole (1).

⁹ *Scedosporium* spp.: voriconazole with /amphotericin B (4), ./posaconazole (1), ./caspofungin (1); *Lomentospora prolificans*: ./amphotericin B (2), ./caspofungin (1).

¹⁰ *Scedosporium* spp.: amphotericin B with ./itraconazole (6), ./5-flucytosine (2), ./posaconazole (1), ./caspofungin (1); *Lomentospora prolificans*: amphotericin B with ./itraconazole (1), ./5-flucytosine (1).

¹¹ *Scedosporium* spp.: 5-flucytosin with ./fluconazole (1), ./miconazole (1); *Lomentospora prolificans*: amphotericin B with ./itraconazole (2), ./5-flucytosine (1).

¹² Treatment duration known for 30 *Scedosporium* spp. cases and 16 *Lomentospora prolificans* cases.

prolificans infection (32% versus 6% in *Scedosporium* spp. cases, $P = 0.022$). Monotherapy or sequential and combination therapy were given to 23 (42%) and 30 (55%) patients, respectively. There was no major difference between the two patient populations except for sequential monotherapy, which was administered mostly in children with *Scedosporium* spp. infection. Patients received systemic antifungals for a median of 88 days (IQR: 28–344), those who survived for 195 days (IQR: 88–478). Five children received triazoles for antifungal prophylaxis prior to diagnosis of scedosporiosis for a median of 38 days (range 32–1,218).

Overall all-cause mortality was 46%, without a significant difference between the pathogens ($P = 0.595$) (Table 3). The mortality rate for immunocompromised patients with *L. prolificans*-related infection was higher compared to the *Scedosporium* spp. group (85% versus 46%, $P = 0.097$). No immunocompetent patient with infection due to *L. prolificans* died, whereas mortality in the *Scedosporium* spp. group was 40% ($P = 0.033$). Overall day-42 mortality was 31%, significantly higher in the *L. prolificans* group ($P = 0.018$). All immunocompromised patients with an *L. prolificans* infection died within 42 days versus one out of six patients in the *Scedosporium* spp. group ($P = 0.001$) (Table 3). Twelve of the 17 (71%) patients who died within 6 weeks after diagnosis had CNS or blood stream infection, six of those with additional organ involvement.

The analysis of treatment strategies of children with *Scedosporium* spp. infection revealed that seven patients received voriconazole as monotherapy for a median of 138 days (IQR: 73–365). Five of these seven patients survived; all were immunocompetent, four children who had a trauma and underwent additional surgical debridement and one child with pneumonia after near drowning. Eighteen patients (55%) received combination therapy with at least two antifungal agents, mostly including amphotericin B ($n = 13$, 72%) and voriconazole ($n = 7$, 39%), either administered concomitantly ($n = 4$, 22%) or in combination with other agents (amphotericin B with other than voriconazole [$n = 9$, 50%] or voriconazole in combination with other than amphotericin B [$n = 3$, 17%]). Terbinafine was administered together with voriconazole in two patients with *Scedosporium* spp. infection, one with CNS infection after near drowning who survived and one CGD patient with lung infection whose death was unrelated to the infection. Regarding the other five patients with CNS infection after near drowning, one survived with combination therapy of amphotericin B and itraconazole, whereas the other four died within two months despite neurosurgical drainage of brain abscesses in three patients.

Of the eleven children who survived the *L. prolificans* infection, nine were immunocompetent at time of diagnosis presenting with bone, joint or deep soft tissue infection, and one of the two children with leukemia presented with disseminated disease. Ten

of these underwent surgery in addition to systemic antifungal treatment, which included voriconazole in nine patients, six in combination with terbinafine. Only one out of seven children with *L. prolificans*-related blood stream infection, all with underlying malignancy, survived with voriconazole and terbinafine combination therapy for one year, whereas the other six patients died within two weeks after diagnosis of the infection.

In total, of the nine children receiving a combination therapy of terbinafine with triazole, six were immunocompetent and all underwent surgery; eight (89%) of them survived and the one death was unrelated to the fungal infection.

Overall, using a simple Cox regression model four dichotomic variables were identified as potentially predictive for outcome: compromised immune status at time of infection diagnosis ($P = 0.045$), severe disseminated disease ($P = 0.002$), voriconazole use ($P = 0.002$), and surgery ($P = 0.001$) (Table 4). Sex ($P = 0.164$) and species ($P = 0.273$) were not significant in the simple Cox regression but were included for further analysis. The final multivariable regression model was adjusted for sex, species (*Scedosporium* spp., *L. prolificans*), risk factors (near drowning, others in immunocompetent patients, malignancy, allogeneic HSCT, others in immunocompromised patients), severity of infection (localized disease other than lung, localized lung infection, severe infection [CNS infection, fungemia, and dissemination to different organs]), combination therapy, voriconazole use, amphotericin B use, and surgery. Treatment for malignancy, especially allogeneic HSCT, and severe infection were significantly associated with an increased risk of death with adjusted hazard ratios of 8.33 (95% CI 1.35–51.40), 20.31 (95% CI 2.07–199.13) and 6.12 (95% CI 1.52–24.66), respectively (Table 4). Near drowning was not significantly predictive for worse outcome. Children had a lower risk of death if voriconazole and surgery were part of the antifungal treatment regimen (HR 0.33 [95% CI 0.11–0.99] and HR 0.09 [95% CI 0.02–0.40], respectively). Overall, the worst outcome was seen in children with severe disseminated fungal infection in immunocompetent (6/9 died, 67%) and immunocompromised patients (8/12 died, 67%) (log rank $P = 0.562$) (Figure 1). Mortality for patients receiving first-line voriconazole compared to other antifungal agents was similar in immunocompetent (2/11 [18%] versus 4/13 [31%] died, $P = 0.649$) and in immunocompromised patients (3/3 [100%] versus 10/14 [71%] died, $P = 0.541$).

Discussion

In the present study, we summarized the current epidemiological data on *Scedosporium* spp. and *L. prolificans* infections in children, using patient information identified in the global

Table 3
Outcome of *Scedosporium* spp. and *Lomentospora prolificans* infections in 55 children.

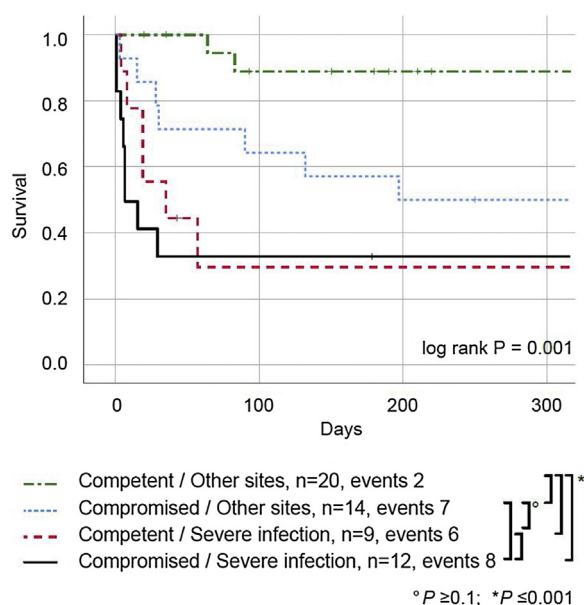
N (%)	All patients N=55		<i>Scedosporium</i> spp. N=33		<i>Lomentospora prolificans</i> N=22		P Value
Mortality overall, N (%)							
Overall	25	(46)	14	(42)	11	(50)	0.595
Day 42	17	(31)	6	(18)	11	(50)	0.018
Mortality, Immunocompromised, N (%)							
Overall	17	(65)	6	(46)	11	(85)	0.097
Day 42	12	(46)	1	(8)	11	(85)	0.001
Mortality, Immunocompetent, N (%)							
Overall	8	(28)	8	(40)	0	(0)	0.033
Day 42	5	(17)	5	(25)	0	(0)	0.153
Observation time, days median (IQR)							
Overall	180 (20 - 600)		197 (39 - 730)		90 (6 - 248)		0.065
Alive	517 (188 - 1091)		600 (180 - 1185)		220 (190 - 790)		0.464
Deceased	19 (5 - 74)		61 (16 - 148)		6 (3 - 28)		0.009

P values comparing *Scedosporium* spp. with *Lomentospora prolificans* group.
IQR interquartile range.

Table 4Logistic regression assessing factors influencing one-year survival in 55 patients with *Scedosporium* spp. and *Lomentospora prolificans* infection.

	Univariate				Multivariate			
	P value	HR	95% CI		P value	Adjusted HR	95% CI	
Sex								
Male	0.164	0.545	0.232	1.280	0.609	0.725	0.211	2.486
Species								
<i>Scedosporium</i> spp.
<i>Lomentospora prolificans</i>	0.273	1.600	0.690	3.709	0.276	0.449	0.107	1.894
Risk factor								
Immunocompetent
Immunocompromised	0.045	2.438	1.022	5.817				
Immunocompetent patients								
Immunocompetent other
Near drowning	0.062	3.757	0.935	15.099	0.175	3.604	0.566	22.960
Immunocompromised patients								
Immunocompromised other	0.860	1.249	0.105	14.884
Malignancy	0.041	8.777	1.092	70.526	0.022	8.335	1.352	51.396
Allogeneic HSCT	0.038	10.283	1.134	93.268	0.010	20.305	2.071	199.131
Site of infection								
Skin/bone/joints localized
Lung localized	0.620	1.437	0.343	6.020	0.920	0.919	0.176	4.783
Disseminated CNS/blood/lung	0.002	5.063	1.803	14.214	0.011	6.118	1.518	24.658
Antifungal therapy								
Voriconazole	0.002	0.248	0.104	0.596	0.048	0.333	0.112	0.989
Amphotericin B	0.693	1.187	0.507	2.778	0.388	1.823	0.466	7.122
Combination therapy	0.457	0.715	0.296	1.730	0.147	0.362	0.092	1.430
Surgery	0.001	0.153	0.062	0.376	0.001	0.093	0.022	0.401

HR Harzard Ratio, 95% CI confidence interval.

HR adjusted for sex, species (*Scedosporium* spp., *L. prolificans*), risk factors (near drowning, others in immunocompetent patients, malignancy, allogeneic HSCT, others in immunocompromised patients), severity of infection (localized disease other than lung, localized lung infection, severe infection [CNS infection, fungemia, and dissemination to different organs]), combination therapy, voriconazole use, amphotericin B use, and surgery.**Figure 1.** Survival curves for 55 children with *Scedosporium* spp. and *Lomentospora prolificans* infections. Kaplan Meier curves for immunocompetent and immunocompromised patients with severe fungal infections (including fungemia, central nervous system infection, and other disseminated infection) compared to other, localized infections (including bone, joints, eye, and skin infections). Significant differences are indicated with an asterisk below.

FungiScope® registry and the relevant literature published since 1990, when liposomal amphotericin B became available. As we did not observe significant differences regarding patients characteristics and one-year survival (Supplementary Table S1, matched pair analysis (data not shown)), both patient populations were

combined for analysis. Recently, a comprehensive review on epidemiology and clinical course of these infections included 264 adult patients (Seidel et al., 2019). We observed a predominance of *Scedosporium* spp. (n = 33) over *L. prolificans* (n = 22) infection in children, supporting the epidemiological trend we observed in adults. Due to potential reporting bias, our data most likely does not reflect the true incidence. A retrospective multicenter analysis in adult leukemic patients estimated that infections due to *Scedosporium* spp. and *L. prolificans* account for less than 1% of mold infections (Caira et al., 2008).

In our analysis, *Scedosporium* spp. and *L. prolificans* infections occurred slightly more often in immunocompetent than in immunocompromised children (53% versus 47%), which was the opposite in adults, where the infections were diagnosed more often in immunocompromised patients (Seidel et al., 2019). The difference might be explained by the fact that in the adults, *Scedosporium* spp. and *L. prolificans* infections were seen in 58/118 patients after solid organ transplantation, a patient population that is comparably uncommon in the pediatric setting. Corroborating the data in adults, disseminated disease was more common in children with *L. prolificans* than with *Scedosporium* spp. infection, mostly attributable to fungemia infection. Similar to adults, most commonly affected sites were lungs, CNS, bone/joints and skin with or without deep soft tissue involvement (Seidel et al., 2019). CNS involvement was seen in children after near drowning or traumatic injuries mostly, whereas in adults the most common risk factor for CNS infection, besides near drowning, was immunosuppressive treatment for malignancy or solid organ transplantation. No child with endocarditis was identified. In adults heart infection was mostly associated with lung or heart transplantation and thorax or heart surgery; these risk factors were not present in the pediatric cases. Eye infections were infrequent in children because common risk factors such as work related injuries, uncontrolled diabetes mellitus and solid organ transplantation as seen in adults were not present.

Mortality was high, about half of the children died within a median of three weeks after diagnosis of the infection. Not surprisingly, the mortality rate was higher in immunocompromised than immunocompetent children (65% versus 28%), which was comparable to overall mortality in adults (51.3% for immunocompromised versus 29.5% for immunocompetent adults (Seidel et al., 2019)). Disseminated infection was more frequent in immunocompromised patients; both are associated with worse outcome. Notably, a significant proportion of children and adults died within 42 days after diagnosis of the fungal infection.

The treatment options for these infections are still limited, both in children and adults, due to the intrinsic resistance of *Scedosporium* spp. to numerous and of *L. prolificans* to almost all antifungal agents (Tortorano et al., 2014). This also explains the high risk of breakthrough infection in patients receiving antifungal prophylaxis (Cornely et al., 2019). The 2014 European Society of Clinical Microbiology and Infectious Diseases (ESCMID) and European Confederation of Medical Mycology (ECMM) guidelines recommend voriconazole first line treatment in combination with surgical debridement for *Scedosporium* spp. infections (Tortorano et al., 2014). The combination of voriconazole with another class of antifungal drugs, such as polyene, echinocandin or terbinafine, has shown synergistic effects against both *Scedosporium* spp. and *L. prolificans*. However, combination therapy has demonstrated variable clinical outcomes (McCarthy et al., 2018). Surgical interventions are associated with improved outcome in our dataset and should be considered for treatment of *Scedosporium* spp. and *L. prolificans* whenever possible. Our analysis demonstrates that, similar to adult patients (Seidel et al., 2019), the mortality rates of children treated with voriconazole were lower compared to those treated with other antifungals alone. The combination of voriconazole with terbinafine may have a beneficial effect on survival (Jenks et al., 2020). However, due to the small number of children and the presence of numerous confounding factors, it is not possible to draw a firm conclusion from our dataset on the benefit of terbinafine in the setting of combination therapy. Interestingly, terbinafine has been tested for systemic therapy of invasive mold infections in several animal models without showing useful efficacy and it was therefore not developed in humans (Dixon and Polak, 1987; Schmitt et al., 1990). The likely explanation is the strong lipophilicity and serum protein binding that reduces bioavailability and hinders the drug from reaching its target in the internal organ systems (Jensen, 1989; Schafer-Korting et al., 1995). Whether isavuconazole, which is not approved for use in children, might be a treatment option is unclear, as there are no data in children and data in adults are inconclusive (Cornely et al., 2018). New antifungal agents, such as olorofim or fosmanogepix (APX001), which demonstrate good *in vitro* activity against *Scedosporium* spp. and *L. prolificans*, are currently in clinical trials and may offer new treatment options for children in the future (Biswas et al., 2018; Pfaller et al., 2019).

Infections caused by *Scedosporium* spp. and *L. prolificans* are extremely rare, with few cases described in the pediatric population. Immunocompromised patients, particularly those with severe disseminated disease have a poor clinical outcome. Similar to adult patients, voriconazole and surgical intervention were associated with improved outcome, whereas the benefit of terbinafine as combination therapy needs confirmation in a more homogenous population. Newly developed antifungal agents show promise and may soon be available for children with *Scedosporium* spp. and *L. prolificans* infection.

Author contributions

DS: coordinates the FungiScope[®] registry, enrolled patients and performed formal validation in FungiScope[®], performed a

literature search, extracted data from FungiScope[®] and case reports, performed statistical analysis, wrote the initial draft of the manuscript, created tables and figures.

AH: extracted data from case reports.

JS G: enrolled patients in FungiScope[®], reviewed statistical methods used in this manuscript.

JS G, PK, SCM: performed formal validation in FungiScope[®].

FC, MPC, IF-R, RH, AJS, NK, MM, CL-F, PS-P: provided clinical data of respective patients to FungiScope[®].

HW: runs the FungiScope[®] central laboratory, performs formal identification and susceptibility test of fungal isolates, biobanks fungal isolates.

OAC: chairs FungiScope[®], provided clinical details of patients.

ZP, TL: interpreted the data, wrote the initial draft of the manuscript, revised tables and figures.

All: revised and approved the final manuscript.

Ethical approval

FungiScope[®] has received a valuable report from the Clinical Ethics Committee of the University Hospital of Cologne first on September 12, 2005 and again on April 1, 2019 for an amended protocol (Study number 05-102).

Funding

FungiScope[®] is supported by unrestricted grants of Amplyx Pharmaceuticals, Basilea Pharmaceutica, Cidara Therapeutics, F2G Ltd., Matinas BioPharma, MSD Sharp & Dohme GmbH, and SCYNEXIS Inc. FungiScope[®] has been supported in the past by unrestricted grants of Astellas Pharma, Gilead Sciences, and Pfizer Inc.

Conflict of interest

Philipp Koehler has received non-financial scientific grants from Miltenyi Biotec GmbH, Bergisch Gladbach, Germany, and the Cologne Excellence Cluster on Cellular Stress Responses in Aging-Associated Diseases, University of Cologne, Cologne, Germany, and received lecture honoraria from Akademie für Infektionsmedizin e. V., Astellas Pharma, Gilead Sciences, and MSD Sharp & Dohme GmbH outside the submitted work

Sibylle C. Mellinghoff has received research grants by DMMyKG and Koeln Fortune, University of Cologne, Cologne, Germany and was a consultant to Octapharma.

Fabianne Carlesse received educational grants from Pfizer; United Medical, Astellas, MSD and TEVA nothing related with this study.

Nikolai Klimko has received personal fees from Pfizer, MSD, Gilead, and Astellas, outside the submitted work.

Cornelia Lass-Flörl reports grant support from Gilead Sciences and Astellas Pharma, travel/accommodation/payment for lectures/consultancy from Gilead Sciences, Astellas Pharma, Basilea, Pfizer Inc. outside the submitted work.

Pere Soler-Palacián has received research grants from Gilead Sciences, Pfizer Inc. and Astellas Pharma.

Oliver A. Cornely is supported by the German Federal Ministry of Research and Education and the European Commission, and has received research grants from, is an advisor to or received lecture honoraria from, Actelion, Allegra Therapeutics, Amplyx, Astellas Pharma, Basilea, Biosys UK Limited, Cidara, Da Volterra, Entasis, F2G Ltd., Gilead, IQVIA, Janssen Pharmaceuticals, Matinas, Medicines Company, MedPace, Melinta Therapeutics, Menarini Ricerche, Merck/MSD, Octapharma, Paratek Pharmaceuticals, Pfizer Inc., PSI, Rempex, Scynexis, Seres Therapeutics, Tetrphase, and Vical outside the submitted work.

Thomas Lehrnbecher has received research grants from Gilead Sciences, is a consultant to Astellas, Basilea, Gilead Sciences, and Merck/MSD, and served at the speaker's bureau of Astellas, Gilead Sciences, Merck/MSD, and Sanofi Pasteur.

Other authors: None.

Appendix A. Supplementary data

Supplementary material related to this article can be found, in the online version, at doi:<https://doi.org/10.1016/j.ijid.2019.12.017>.

References

- Abzug MJ, Walsh TJ. Interferon-gamma and colony-stimulating factors as adjuvant therapy for refractory fungal infections in children. *Pediatr Infect Dis J* 2004;23:769–73.
- Acharya A, Ghimire A, Khanal B, Bhattacharya S, Kumari N, Kanungo R. Brain abscess due to *Scedosporium apiospermum* in a non immunocompromised child. *Indian J Med Microbiol* 2006;24:231–2.
- Barbaric D, Shaw PJ. *Scedosporium* infection in immunocompromised patients: successful use of liposomal amphotericin B and itraconazole. *Med Pediatr Oncol* 2001;37:122–5.
- Bhagavatula S, Vale L, Evans J, Carpenter C, Barnes RA. *Scedosporium prolificans* osteomyelitis following penetrating injury: a case report. *Med Mycol Case Rep* 2014;4:26–9.
- Bhat SV, Paterson DL, Rinaldi MG, Veldkamp PJ. *Scedosporium prolificans* brain abscess in a patient with chronic granulomatous disease: successful combination therapy with voriconazole and terbinafine. *Scand J Infect Dis* 2007;39:87–90.
- Biswas C, Law D, Birch M, Halliday C, Sorrell TC, Rex J, et al. In vitro activity of the novel antifungal compound F901318 against Australian *Scedosporium* and *Lomentospora* fungi. *Med Mycol* 2018;56:1050–4.
- Bonduel M, Santos P, Turienzo CF, Chantada G, Paganini H. Atypical skin lesions caused by *Curvularia* sp. and *Pseudallescheria boydii* in two patients after allogeneic bone marrow transplantation. *Bone Marrow Transplant* 2001;27:1311–3.
- Caira M, Girmenia C, Valentini CG, Sanguinetti M, Bonini A, Rossi G, et al. *Scedosporiosis* in patients with acute leukemia: a retrospective multicenter report. *Haematologica* 2008;93:104–10.
- Chakraborty A, Workman MR, Bullock PR. *Scedosporium apiospermum* brain abscess treated with surgery and voriconazole. *Case report. J Neurosurg* 2005;103:83–7.
- Chayakulkeeree M, Ghannoum MA, Perfect JR. Zygomycosis: the re-emerging fungal infection. *Eur J Clin Microbiol Infect Dis* 2006;25:215–29.
- Chen S, Aronow ME, Wang C, Shen D, Chan CC. Classical pathology of sympathetic ophthalmia presented in a unique case. *Open Ophthalmol J* 2014;8:32–8.
- Chiam N, Rose LV, Waters KD, Elder JE. *Scedosporium prolificans* endogenous endophthalmitis. *J AAPOS* 2013;17:627–9.
- Cornely OA, Mullane KM, Ostrosky-Zeichner L, Maher RM, Croos-Dabrera R, Lu Q, et al. Isavuconazole for treatment of rare invasive fungal diseases. *Mycoses* 2018;61:518–33.
- Cornely OA, Hoenigl M, Lass-Flörl C, Chen SC, Kontoyiannis DP, Morrissey CO, et al. Defining breakthrough invasive fungal infection—position paper of the mycoses study group education and research consortium and the European Confederation of Medical Mycology. *Mycoses* 2019;62:716–29.
- Cortez KJ, Roilides E, Quiroz-Telles F, Meletiadis J, Antachopoulos C, Knudsen T, et al. Infections caused by *Scedosporium* spp. *Clin Microbiol Rev* 2008;21:157–97.
- Cruysmans C, Rodriguez-Villalobos H, Fomekong E, Dumitriu D, Nassogne MC, Van der Linden D. Epidural abscess caused by *Scedosporium apiospermum* in an immunocompetent child. *Pediatr Infect Dis J* 2015;34:1277–8.
- Dalton PA, Munckhof WJ, Walters DW. *Scedosporium prolificans*: an uncommon cause of septic arthritis. *ANZ J Surg* 2006;76:661–3.
- De Pauw B, Walsh TJ, Donnelly JP, Stevens DA, Edwards JE, Calandra T, et al. Revised definitions of invasive fungal disease from the European Organization for Research and Treatment of Cancer/Invasive Fungal Infections Cooperative Group and the National Institute of Allergy and Infectious Diseases Mycoses Study Group (EORTC/MSG) Consensus Group. *Clin Infect Dis* 2008;46:1813–21.
- Dixon DM, Polak A. In vitro and in vivo drug studies with three agents of central nervous system phaeocephomycosis. *Chemotherapy* 1987;33:129–40.
- Gatto J, Paterson D, Davis L, Lockwood L, Allworth A. Vertebral osteomyelitis due to *Pseudallescheria boydii*. *Pathology* 1997;29:238–40.
- Gompels MM, Bethune CA, Jackson G, Spickett GP. *Scedosporium apiospermum* in chronic granulomatous disease treated with an HLA matched bone marrow transplant. *J Clin Pathol* 2002;55:784–6.
- Hachimi-Idrissi S, Willemsen M, Desprechins B, Naessens A, Goossens A, De Meirleir L, et al. *Pseudallescheria boydii* and brain abscesses. *Pediatr Infect Dis J* 1990;9:737–41.
- Harun A, Gilgado F, Chen SC, Meyer W. Abundance of *Pseudallescheria/Scedosporium* species in the Australian urban environment suggests a possible source for scedosporiosis including the colonization of airways in cystic fibrosis. *Med Mycol* 2010;48 Suppl 1:S70–76.
- Hell M, Neureiter J, Wojna A, Presterl E, Willinger B, de Hoog GS, et al. Post-traumatic *Pseudallescheria apiosperma* osteomyelitis: positive outcome of a young immunocompetent male patient due to surgical intervention and voriconazole therapy. *Mycoses* 2011;54 Suppl 3:43–7.
- Holle J, Leichsenring M, Meissner PE. Nebulized voriconazole in infections with *Scedosporium apiospermum*—case report and review of the literature. *J Cyst Fibros* 2014;13:400–2.
- Jabado N, Casanova JL, Haddad E, Dulieu F, Fournet JC, Dupont B, et al. Invasive pulmonary infection due to *Scedosporium apiospermum* in two children with chronic granulomatous disease. *Clin Infect Dis* 1998;27:1437–41.
- Jenks JD, Reed SL, Seidel D, Koehler P, Cornely OA, Mehta SR, et al. Rare mould infections caused by *Mucorales*, *Lomentospora* proliferans and *Fusarium*, in San Diego, CA: the role of antifungal combination therapy. *Int J Antimicrob Agents* 2018;52:706–12.
- Jenks JD, Seidel D, Cornely OA, Chen S, van Hal S, Kauffman C, et al. Voriconazole plus terbinafine combination antifungal therapy for invasive *Lomentospora proliferans* infections: analysis of 41 patients from the FungiScope® registry 2008–2019. , doi:<http://dx.doi.org/10.1016/j.cmi.2020.01.012>.
- Jensen JC. Clinical pharmacokinetics of terbinafine (Lamisil). *Clin Exp Dermatol* 1989;14:110–3.
- Jover-Saenz A, Altermir-Martinez V, Barcenilla-Gaite F, Garrido-Calvo S. [Infectious arthritis with osteomyelitis due to *Scedosporium proliferans* in an immunocompetent patient]. *Med Clin (Barc)* 2016;146:e15–16.
- Kesson AM, Bellemore MC, O'Mara TJ, Ellis DH, Sorrell TC. *Scedosporium proliferans* osteomyelitis in an immunocompetent child treated with a novel agent, hexadecylphosphocholine (miltefosine), in combination with terbinafine and voriconazole: a case report. *Clin Infect Dis* 2009;48:1257–61.
- Klopfenstein KJ, Rosselet R, Termuhlen A, Powell D. Successful treatment of *Scedosporium pneumonia* with voriconazole during AML therapy and bone marrow transplantation. *Med Pediatr Oncol* 2003;41:494–5.
- Lee MG, Choi JG, Son BC. *Scedosporium apiospermum*: an emerging fatal cause of fungal abscess and ventriculitis after near-drowning. *Asian J Neurosurg* 2018;13:792–6.
- Madrigal V, Alonso J, Bureo E, Figols FJ, Salesa R. Fatal meningoencephalitis caused by *Scedosporium inflatum* (*Scedosporium proliferans*) in a child with lymphoblastic leukemia. *Eur J Clin Microbiol Infect Dis* 1995;14:601–3.
- Marques DS, Pinho Vaz C, Branca R, Campilho F, Lamelas C, Afonso LP, et al. Rhizomucor and *scedosporium* infection post hematopoietic stem-cell transplant. *Case Rep Med* 2011;2011:830769.
- Matlani M, Kaur R, Shweta. A case of *scedosporium proliferans* osteomyelitis in an immunocompetent child, misdiagnosed as tubercular osteomyelitis. *Indian J Dermatol* 2013;58:80–1.
- McCarthy MW, Katragkou A, Iosifidis E, Roilides E, Walsh TJ. Recent advances in the treatment of scedosporiosis and fusariosis. *J Fungi (Basel)* 2018;4:E73.
- Messori A, Lanza C, De Nicola M, Menichelli F, Capriotti T, Morabito L, et al. Mycotic aneurysms as lethal complication of brain pseudallescheriasis in a near-drowned child: a CT demonstration. *AJNR Am J Neuroradiol* 2002;23:1697–9.
- Mursch K, Trnovec S, Ratz H, Hammer D, Horre R, Klinghammer A, et al. Successful treatment of multiple *Pseudallescheria boydii* brain abscesses and ventriculitis/ependymitis in a 2-year-old child after a near-drowning episode. *Childs Nerv Syst* 2006;22:189–92.
- Ng TT, Denning DW. Liposomal amphotericin B (AmBisome) therapy in invasive fungal infections. Evaluation of United Kingdom compassionate use data. *Arch Intern Med* 1995;155:1093–8.
- Nielsen K, Lang H, Shum AC, Woodruff K, Cherry JD. Disseminated *Scedosporium proliferans* infection in an immunocompromised adolescent. *Pediatr Infect Dis J* 1993;12:882–4.
- Penteado FD, Litvinov N, Sztajn bok J, Thomaz DY, Dos Santos AM, Vasconcelos DM, et al. *Lomentospora proliferans* fungemia in hematopoietic stem cell transplant patients: first report in South America and literature review. *Transpl Infect Dis* 2018;20:e12908.
- Pfaller MA, Huband MD, Flamm RK, Bien PA, Castanheira M. In vitro activity of APX001A (Manogepix) and comparator agents against 1,706 fungal isolates collected during an international surveillance program in 2017. *Antimicrob Agents Chemother* 2019;63: e00840-00819.
- Pickles RW, Pacey DE, Muir DB, Merrell WH. Experience with infection by *Scedosporium proliferans* including apparent cure with fluconazole therapy. *J Infect* 1996;33:193–7.
- Rodriguez-Tudela JL, Berenguer J, Guarro J, Kantarcioglu AS, Horre R, de Hoog GS, et al. Epidemiology and outcome of *Scedosporium proliferans* infection, a review of 162 cases. *Med Mycol* 2009;47:359–70.
- Romero Gomez MP, Garcia Rodriguez J. [Invasive fungal infection in a patient with Burkitt lymphoma]. *Rev Iberoam Micol* 2010;27:214–5.
- Ruchel R, Wilichowski E. Cerebral *Pseudallescheria* mycosis after near-drowning. *Mycoses* 1995;38:473–5.
- Schafer-Korting M, Korting HC, Rittler W, Obermuller W. Influence of serum protein binding on the in vitro activity of anti-fungal agents. *Infection* 1995;23:292–7.
- Schmitt HJ, Andrade J, Edwards F, Niki Y, Bernard E, Armstrong D. Inactivity of terbinafine in a rat model of pulmonary aspergillosis. *Eur J Clin Microbiol Infect Dis* 1990;9:832–5.
- Schwarz C, Brandt C, Antweiler E, Krannich A, Staab D, Schmitt-Grohe S, et al. Prospective multicenter German study on pulmonary colonization with *Scedosporium/Lomentospora* species in cystic fibrosis: epidemiology and new association factors. *PLoS One* 2017;12: e0171485.
- Seidel D, Duran Graeff LA, Vehreschild M, Wisplinghoff H, Ziegler M, Vehreschild JJ, et al. FungiScope® -Global Emerging Fungal Infection Registry. *Mycoses* 2017;60:508–16.
- Seidel D, Meissner A, Lackner M, Piepenbrock E, Salmanton-Garcia J, Stecher M, et al. Prognostic factors in 264 adults with invasive *Scedosporium* spp. and

- Lomentospora prolificans infection reported in the literature and FungiScope®. *Crit Rev Microbiol* 2019;45:1–21.
- Slack CL, Watson DW, Abzug MJ, Shaw C, Chan KH. Fungal mastoiditis in immunocompromised children. *Arch Otolaryngol Head Neck Surg* 1999;125:73–5.
- Sobottka I, Deneke J, Pothmann W, Heinemann A, Mack D. Fatal native valve endocarditis due to *Scedosporium apiospermum* (*Pseudallescheria boydii*) following trauma. *Eur J Clin Microbiol Infect Dis* 1999;18:387–9.
- Song MJ, Lee JH, Lee NY. Fatal *Scedosporium prolificans* infection in a paediatric patient with acute lymphoblastic leukaemia. *Mycoses* 2011;54:81–3.
- Sparrow SA, Hallam LA, Wild BE, Baker DL. *Scedosporium inflatum*: first case report of disseminated infection and review of the literature. *Pediatr Hematol Oncol* 1992;9:293–5.
- Steinbach WJ, Schell WA, Miller JL, Perfect JR. *Scedosporium prolificans* osteomyelitis in an immunocompetent child treated with voriconazole and caspofungin, as well as locally applied polyhexamethylene biguanide. *J Clin Microbiol* 2003;41:3981–5.
- Stripeli F, Pasparakis D, Velegraki A, Lebessi E, Arsenis G, Kafetzis D, et al. *Scedosporium apiospermum* skeletal infection in an immunocompetent child. *Med Mycol* 2009;47:441–4.
- Studahl M, Backteman T, Stalhammar F, Chryssanthou E, Petrini B. Bone and joint infection after traumatic implantation of *Scedosporium prolificans* treated with voriconazole and surgery. *Acta Paediatr* 2003;92:980–2.
- Sydnor MK, Kaushik S, Knight Jr. TE, Bridges CL, McCarty JM. Mycotic osteomyelitis due to *Scedosporium Apiospermum*: MR imaging-pathologic correlation. *Skeletal Radiol* 2003;32:656–60.
- Tapia M, Richard C, Baro J, Salesa R, Figols J, Zurbano F, et al. *Scedosporium inflatum* infection in immunocompromised haematological patients. *Br J Haematol* 1994;87:212–4.
- Tortorano AM, Richardson M, Roilides E, van Diepeningen A, Caira M, Munoz P, et al. European Society of Clinical Microbiology and Infectious Diseases Fungal Infection Study Group, European Confederation of Medical Mycology. ESCMID and ECMM joint guidelines on diagnosis and management of hyalohyphomycosis: *Fusarium* spp., *Scedosporium* spp. and others. *Clin Microbiol Infect* 2014;20 Suppl 3:27–46.
- Vazquez-Tsuji O, Campos Rivera T, Rondan Zarate A, Mirabal Garcia M. Endobronchitis by *Scedosporium apiospermum* in a child with cystic fibrosis. *Rev Iberoam Micol* 2006;23:245–8.
- Whyte M, Irving H, O'Regan P, Nissen M, Siebert D, Labrom R. Disseminated *Scedosporium prolificans* infection and survival of a child with acute lymphoblastic leukemia. *Pediatr Infect Dis J* 2005;24:375–7.
- Wilichowski E, Christen HJ, Schiffmann H, Schulz-Schaeffer W, Behrens-Baumann W. Fatal *Pseudallescheria boydii* panencephalitis in a child after near-drowning. *Pediatr Infect Dis J* 1996;15:365–70.
- Wood GM, McCormack JG, Muir DB, Ellis DH, Ridley MF, Pritchard R, et al. Clinical features of human infection with *Scedosporium inflatum*. *Clin Infect Dis* 1992;14:1027–33.
- Zarkovic A, Guest S. *Scedosporium apiospermum* traumatic endophthalmitis successfully treated with voriconazole. *Int Ophthalmol* 2007;27:391–4.