



Case report

Severe COVID-19 infection in a patient with multiple sclerosis treated with fingolimod

Christian Foerch^{a,1,*}, Lucie Friedauer^{a,1}, Boris Bauer^b, Timo Wolf^c, Elisabeth H. Adam^d^a Department of Neurology, University Hospital, Goethe University, Schleusenweg 2-16, Frankfurt am Main 60528, Germany^b Radiologie Sachsenhausen GmbH, Frankfurt am Main, Germany^c Department of Internal Medicine, University Hospital, Goethe University, Frankfurt am Main, Germany^d Department of Anesthesiology, Intensive Care and Pain Therapy, University Hospital, Goethe University, Frankfurt am Main, Germany

ARTICLE INFO

Keywords:

Critical care
Multiple sclerosis
Fingolimod
Viral infection
COVID-19

ABSTRACT

Background: Fingolimod is used for immune therapy in patients with multiple sclerosis. Long-term treatment is associated with a small increase in the risk of herpes virus reactivation and respiratory tract infections. Patients with coronavirus disease 2019 (COVID-19) under Fingolimod treatment have not been described.

Methods and results: We report a 57-year old female patient with a relapsing remitting multiple sclerosis under fingolimod treatment who experienced a severe COVID-19 infection in March 2020 (Extended Disability Status Scale: 2.0). Having peripheral lymphopenia typical for fingolimod treatment (total lymphocytes 0.39/nL [reference range 1.22-3.56]), the patient developed bilateral interstitial pneumonia with multiple ground-glass opacities on chest CT. Fingolimod medication was stopped. On the intensive care unit, non-invasive ventilation was used to provide oxygen and ventilation support regularly. Over the following two days, oxygenation improved, and the patient was transferred to a normal ward five days after admission.

Conclusion: The implications fingolimod has on COVID-19 are complex. As an S1P analogue, fingolimod might enhance lung endothelial cell integrity. In addition, in case of a so-called cytokine storm, immunomodulation might be beneficial to reduce mortality. Future studies are needed to explore the risks and therapeutic effects of fingolimod in COVID-19 patients.

1. Case report

Fingolimod, a sphingosine 1 phosphate (S1P) analogue, is used for immune therapy in patients with multiple sclerosis. Fingolimod binds to S1P receptors on lymphocytes, leading to receptor internalization and retention of lymphocytes in the lymphoid organs. In consequence, lymphopenia is observed in the T-cell compartment of the peripheral blood. Under fingolimod treatment, a small increase in the risk of herpes virus reactivation and respiratory tract infections has been described (Arvin et al., 2015, Kappos et al., 2010).

The severe acute respiratory syndrome coronavirus 2 (SARS CoV-2) causes coronavirus disease 2019 (COVID-19) (Guan et al., 2020). While most of the patients develop mild symptoms including fever and coughing, severe cases with bilateral interstitial pneumonia and multi organ failure occur. We report the case of a patient potentially at risk for a severe course of COVID-19 due to advanced age, history of multiple sclerosis and ongoing therapy with fingolimod. Informed consent

was obtained from the patient.

1.1. History of multiple sclerosis

In 2010 (at the age of 47) the female patient developed four distinct episodes of transient neurological dysfunctions, including blurred vision and painful bulbar movements of the left and the right eye, respectively, as well as hypaesthesia of the right arm and both legs. MRI showed cerebral and thoracic demyelinating lesions, and lumbar puncture revealed slight pleocytosis and positive oligoclonal bandings. A diagnosis of relapsing-remitting multiple sclerosis was established at that time. A sensory relapse followed in 2011. Immunomodulatory therapy with fingolimod was initiated in 2011 and continued until today. Hereunder no further relapses occurred, and no chronic deterioration of neurological symptoms was observed. However, in 2018, cervical MRI revealed a new inflammatory lesion. The patient was under regular clinical and laboratory monitoring (October 2019:

* Corresponding author.

E-mail address: foerch@em.uni-frankfurt.de (C. Foerch).¹ These authors contributed equally to the manuscript

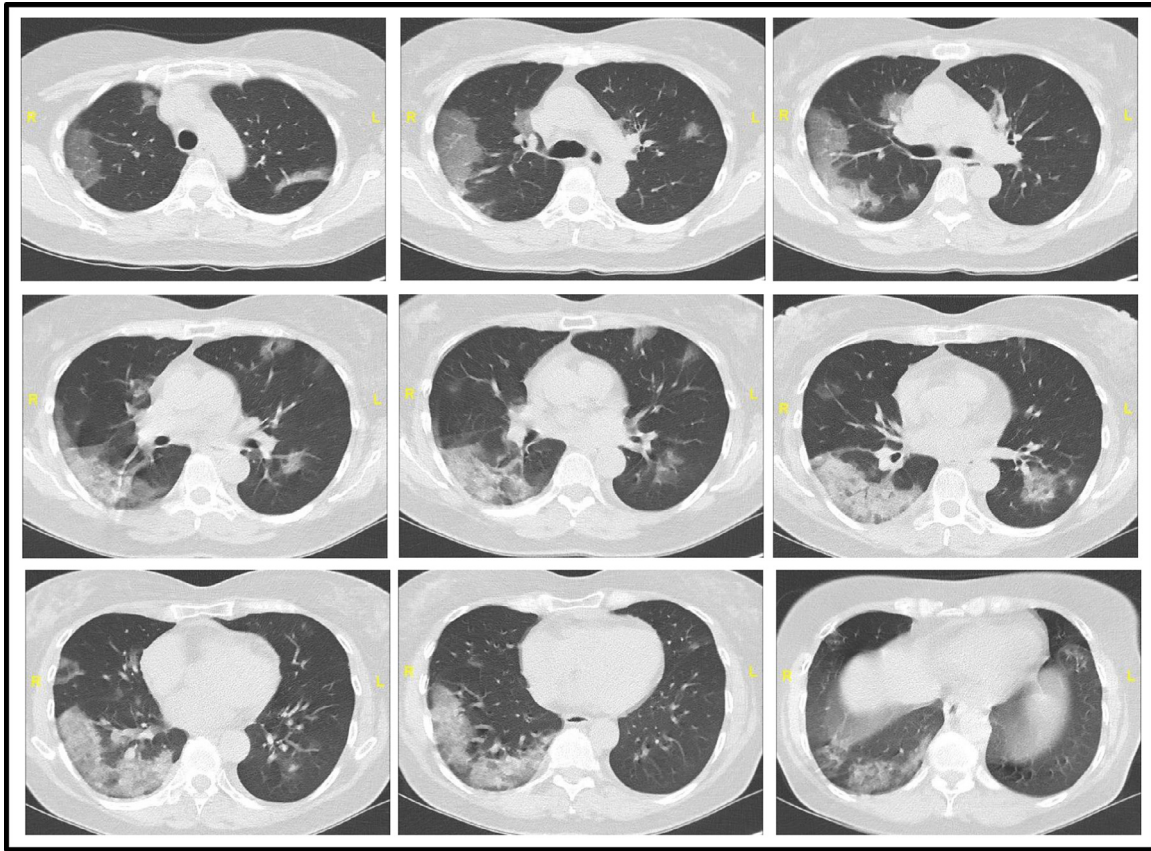


Fig. 1. Chest CT images. Chest CT imaging showed bilateral, multiple ground-glass opacities with a peripheral lung and subpleural distribution in the upper and lower lobes.

Extended Disability Status Scale: 2.0; total lymphocytes 0.73/nL [1.22-3.56]). At no point in time any evidence for the activation of a latent virus disease had been detected.

1.2. COVID-19 infection

By end of March 2020, the patient presented to a primary care hospital reporting dyspnea, fever and dry cough that started to occur 7 days ago. Peripheral oxygen saturation (SpO₂) was 87% at a respiratory rate of 30/min. Chest CT scan showed bilateral multiple ground-glass opacities with a peripheral lung and subpleural distribution in the upper and lower lobes (Figure 1). The patient required supplemental oxygen therapy of 5L/min via oxygen mask yielding in SpO₂ of 93%. She was transferred to the intensive care unit (ICU) of our University hospital. On admission (day 0), physical examination revealed fever (39.5°C) and a respiratory rate of 28/min. Laboratory tests showed CRP elevation (2.7mg/dL [reference range <0.5]) and peripheral lymphopenia typical for fingolimod treatment (total lymphocytes 0.39/nL [1.22-3.56], T-lymphocytes [CD3+] 0.31/nL [0.7-1.2], T-helper cells [CD4+] 0.032/nL [0.3-1.4], T-suppressor cells [CD8+] normal). Neutrophil and platelet counts were within normal ranges, but liver function testing revealed a mild elevation of AST (62U/L [<35]) and GGT (65U/L [<40]; ALT and total bilirubin normal). Coagulation parameters were normal apart from D-dimer elevation (1137ng/mL [<500]). Arterial blood gas analysis showed paO₂ of 83mmHg, pCO₂ of 38mmHg and pH of 7.45. Oropharyngeal swab specimens were positive for SARS CoV-2 (diagnosed using quantitative reverse transcriptase-polymerase chain reaction targeting the RdRp-gene [CT value 21.61]). No bacterial (co)infection or influenza were detected. Fingolimod medication was stopped. Non-invasive ventilation was used to provide oxygen and ventilation support regularly. Over the following

two days, oxygenation improved. On day four the patient had a normal respiratory rate, and nasal oxygen supply could be reduced to 2L with SpO₂ of 96%. Chest X-ray showed regressive peripheral consolidations in the lungs. No other complications occurred. On day five, we transferred the patient to a normal ward.

2. Discussion

Our patient had a severe COVID-19 infection with bilateral interstitial pneumonia demanding non-invasive ventilation and ICU care (Guan et al., 2020). In addition, the patient combined several risk factors potentially associated with a worse outcome in COVID-19, including age, chronic concomitant disorder and immunomodulatory therapy. Nevertheless, the disease course stabilized rapidly without occurrence of further organ manifestation. The implications fingolimod has on COVID-19 are complex. As an immunomodulatory drug, it retains naïve T cells and central memory T cells within the lymph nodes, thereby preventing autoimmune inflammation in the brain (Pinschewer et al., 2011). However, for defending infectious disease antigens, effector memory T cells are pivotal which are less affected by fingolimod treatment (Pinschewer et al., 2011). Thus, despite severe lymphopenia, innate and adaptive immune responses to SARS CoV-2 presumably were preserved in our patient. Pathological key-features of COVID-19 in the lung include pulmonary edema and diffuse alveolar damage with cellular fibromyxoid exudates (Xu et al., 2020). Interestingly, S1P is a potent angiogenic factor that enhances lung endothelial cell integrity. It stabilizes vascular permeability and alveolar flooding in preclinical animal models of acute lung injury (Natarajan et al., 2013). Moreover, increased levels of cytokines were measured in COVID-19 infected patients with severe courses of disease (Huang et al., 2020). In case of a so-called cytokine storm, immunomodulation is a therapeutic

option. Taken together, fingolimod may be of value to control severe respiratory disease, and a clinical trial has been proposed in COVID-19 patients (<https>).

CRedit authorship contribution statement

Christian Foerch: Writing - original draft, Conceptualization. **Lucie Friedauer:** Conceptualization, Writing - original draft. **Boris Bauer:** Data curation, Formal analysis. **Timo Wolf:** Data curation. **Elisabeth H. Adam:** Conceptualization, Writing - original draft.

Declaration of Competing Interest

CF reports speaker honoraria and honoraria for participating in advisory boards from Novartis, Teva, Merck, Sanofi-Genzyme, and Roche. CF received research support from Sanofi-Genzyme

LF has no conflicts of interest to disclose

BB has no conflicts of interest to disclose

TW has no conflicts of interest to disclose

EA has no conflicts of interest to disclose

No funding was received for this study.

References

- Arvin, A.M., Wolinsky, J.S., Kappos, L., et al., 2015. Varicella-zoster virus infections in patients treated with fingolimod: risk assessment and consensus recommendations for management. *JAMA Neurol.* 72, 31–39.
- Kappos, L., Radue, E.W., O'Connor, P., et al., 2010. A placebo-controlled trial of oral fingolimod in relapsing multiple sclerosis. *N. Engl. J. Med.* 362, 387–401.
- Guan, W.J., Ni, Z.Y., Hu, Y., et al., 2020. Clinical Characteristics of Coronavirus Disease 2019 in China. *N. Engl. J. Med.*
- Pinschewer, D.D., Brinkmann, V., Merkler, D., 2011. Impact of sphingosine 1-phosphate modulation on immune outcomes. *Neurology* 76, S15–S19.
- Xu, Z., Shi, L., Wang, Y., et al., 2020. Pathological findings of COVID-19 associated with acute respiratory distress syndrome. *Lancet Respir. Med.* 8, 420–422.
- Natarajan, V., Dudek, S.M., Jacobson, J.R., et al., 2013. Sphingosine-1-phosphate, FTY720, and sphingosine-1-phosphate receptors in the pathobiology of acute lung injury. *Am. J. Respir. Cell Mol. Biol.* 49, 6–17.
- Huang, C., Wang, Y., Li, X., et al., 2020. Clinical features of patients infected with 2019 novel coronavirus in Wuhan, China. *Lancet* 395, 497–506. <https://clinicaltrials.gov/ct2/show/NCT04280588>.