

Craniofacial examination

Clinical craniofacial examination plays an essential role in assessing the damage caused by a traumatic event. When performing the examination a structured approach is recommended to assure best practice.

Begin by assessing the function of the cranial nerves:

a. Pupillary light reflex: Equally dilated pupils, direct and consensual response.

[Pathology \(G\)](#)

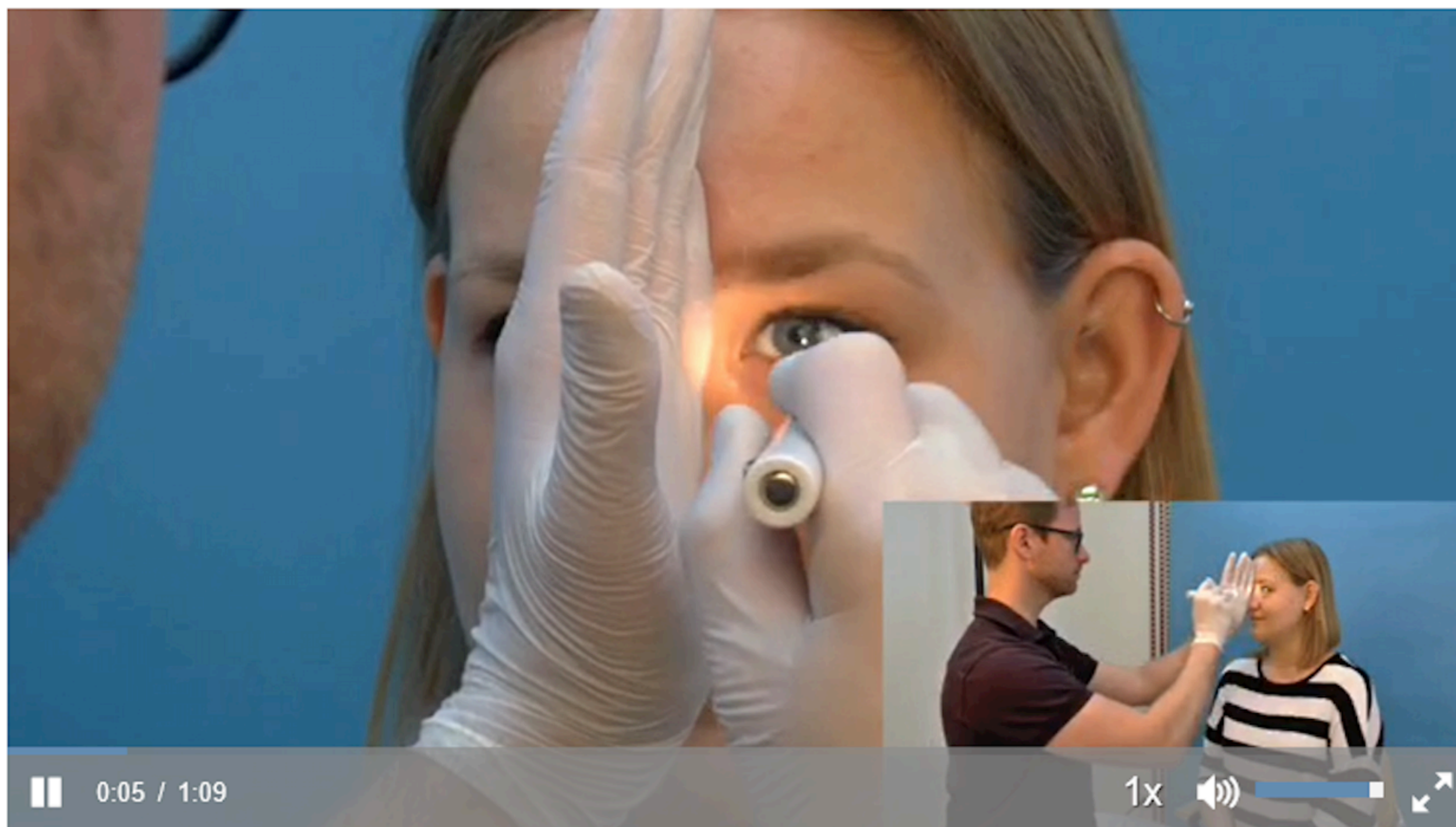b. Clarity of Vision (G):

The ability of the patient to count fingers and recognize colors should be assessed.

[Pathology\(G\)](#)



c. Ocular motility:

Disturbances of ocular motility following



0:05 / 1:09

1x



Demonstration of a structured craniofacial examination