



Consensus on definition and severity grading of lymphatic complications after kidney transplantation

A. Mehrabi¹ , Y. Kulu¹, M. Sabagh¹, E. Khajeh¹, S. Mohammadi¹, O. Ghamarnejad¹, M. Golriz¹, C. Morath², W. O. Bechstein³ , G. A. Berlakovich¹⁸, N. Demartines²⁰, M. Duran⁴, L. Fischer⁵, L. Gürke²¹, J. Klempnauer⁶, A. Königsrainer⁷, H. Lang⁸, U. P. Neumann⁹, A. Pascher¹⁰, A. Paul¹¹, P. Pisarski¹², J. Pratschke¹³, S. Schneeberger¹⁹, U. Settmacher¹⁴, R. Viebahn¹⁵, M. Wirth¹⁶, B. Wullich¹⁷, M. Zeier² and M. W. Büchler¹

¹Department of General, Visceral and Transplantation Surgery, Heidelberg University, and ²Division of Nephrology, Heidelberg University Hospital, Heidelberg, ³Department of General and Visceral Surgery, Frankfurt University Hospital, Goethe University, Frankfurt am Main, ⁴Department of Vascular and Endovascular Surgery, Düsseldorf University Hospital, Heinrich-Heine-University, Düsseldorf, ⁵Department of Visceral and Transplantation Surgery, Hamburg-Eppendorf University Hospital, Hamburg, ⁶Department of General, Visceral, and Transplantation Surgery, Hannover Medical University, Hannover, ⁷Department of General, Visceral and Transplantation Surgery, Eberhard-Karls-University Hospital, Tübingen, ⁸Department of General, Visceral and Transplantation Surgery, Johannes Gutenberg Medical University, Mainz, ⁹Department of General, Visceral and Transplantation Surgery, RWTH University Hospital, Aachen, ¹⁰Department of General, Visceral and Transplantation Surgery, Münster University Hospital, Münster, ¹¹Department of General, Visceral and Transplantation Surgery, Essen University Hospital, Essen, ¹²Department of General, Visceral and Surgery, Freiburg University Hospital, Freiburg, ¹³Department of Surgery, Charité University Hospital, Berlin, ¹⁴Department of General, Visceral and Vascular Surgery, Jena University Hospital, Jena, ¹⁵Department of Surgery, Knappschaftskrankenhaus University Hospital of Bochum, Ruhr University of Bochum, Bochum, ¹⁶Department of Urology, Carl Gustav Carus University Hospital, Dresden, and ¹⁷Department of Urology and Pediatric Urology, University Hospital Erlangen, Erlangen, Germany, ¹⁸Division of Transplantation, Department of Surgery, Vienna Medical University, Vienna, and ¹⁹Department of Visceral, Transplantation and Thoracic Surgery, Innsbruck Medical University, Innsbruck, Austria, and ²⁰Department of Visceral Surgery, CHUV University Hospital, Lausanne, and ²¹Department of Vascular and Transplantation Surgery, Basel University Hospital, Basel, Switzerland

Correspondence to: Professor A. Mehrabi, Department of General, Visceral and Transplantation Surgery, University of Heidelberg, Im Neuenheimer Feld 110, 69120 Heidelberg, Germany (e-mail: arianeb.mehrabi@med.uni-heidelberg.de)

Background: The incidence of lymphatic complications after kidney transplantation varies considerably in the literature. This is partly because a universally accepted definition has not been established. This study aimed to propose an acceptable definition and severity grading system for lymphatic complications based on their management strategy.

Methods: Relevant literature published in MEDLINE and Web of Science was searched systematically. A consensus for definition and a severity grading was then sought between 20 high-volume transplant centres.

Results: Lymphorrhoea/lymphocele was defined in 32 of 87 included studies. Sixty-three articles explained how lymphatic complications were managed, but none graded their severity. The proposed definition of lymphorrhoea was leakage of more than 50 ml fluid (not urine, blood or pus) per day from the drain, or the drain site after removal of the drain, for more than 1 week after kidney transplantation. The proposed definition of lymphocele was a fluid collection of any size near to the transplanted kidney, after urinoma, haematoma and abscess have been excluded. Grade A lymphatic complications have a minor and/or non-invasive impact on the clinical management of the patient; grade B complications require non-surgical intervention; and grade C complications require invasive surgical intervention.

Conclusion: A clear definition and severity grading for lymphatic complications after kidney transplantation was agreed. The proposed definitions should allow better comparisons between studies.

Paper accepted 14 February 2020

Published online 30 March 2020 in Wiley Online Library (www.bjs.co.uk). DOI: 10.1002/bjs.11587

Introduction

Lymphatic complications after kidney transplantation, such as lymphorrhoea and lymphocele, can be challenging.

Lymphocele is associated with morbidities such as abdominal discomfort, impaired wound healing, thrombosis and organ failure¹. Lymphorrhoea/lymphoceles are usually

diagnosed in retroperitoneal kidney grafts. Lymphocele rarely develop in intraperitoneal kidney grafts². The reported incidence of lymphatic complications, including lymphorrhoea and lymphocele, ranges between 0.6 and 51 per cent^{2–8}; the peak incidence of lymphocele is during the sixth postoperative week (range 2 weeks to 6 months)⁹. This big difference in reported rates can be attributed to the lack of a standard definition of lymphatic complications after kidney transplantation, although postoperative diagnosis and follow-up protocols are available^{10,11}.

Varying definitions of lymphatic complications^{3,12–14} mean that results from different studies cannot be compared. In the past decade, international study groups have introduced classifications of different postoperative complications in hepatopancreatobiliary surgery, such as bile leakage and pancreatic fistula^{15–19}. A standardized definition and grading system for lymphatic complications after kidney transplantation would allow multicentre clinical trials of their management and treatment.

The aim of this study was to review the literature for definitions of lymphatic complications, and for information about their incidence, clinical manifestation, diagnosis and management. The results of this literature review were used to propose a definition and practical severity grading system, based on management strategy, that could then be reviewed by a European consensus team from high-volume transplantation centres.

Methods

Literature search

The literature was reviewed systematically to identify articles that reported lymphatic complications after kidney transplantation, in accordance with PRISMA guidelines²⁰. Two databases (MEDLINE and Web of Science) were searched systematically to identify relevant articles published between January 1985 and December 2018. Search terms included (kidney OR renal) AND (transplantation) AND (lymphocele OR lymph leakage OR lymphorrhoea OR lymph fistula OR lymphorrhagia). Reference lists of the retrieved articles were also searched for additional relevant publications.

Relevant studies and the definitions were identified and extracted. The abstracts were screened and the full texts of potentially relevant studies were obtained. The identified articles were double-checked independently by two authors, and any disagreements during selection, extraction and assessment resolved with other authors. All titles and abstracts were selected based on the predefined PICO (population, interest, context) eligibility criteria for qualitative studies. All studies reporting kidney transplantation in

human subjects that reported lymphorrhoea/lymphocele, and including at least 150 procedures, were included in the present review. Any study design was included, except case reports, narrative or systematic reviews, study protocols, experimental studies, conference abstracts, letters and common overviews. Studies on lymphorrhoea/lymphocele after other urological, vascular or gynaecological procedures were also excluded. All articles were also screened to ascertain whether standard definitions of lymphorrhoea and lymphocele had already been settled by the authors.

Data extraction

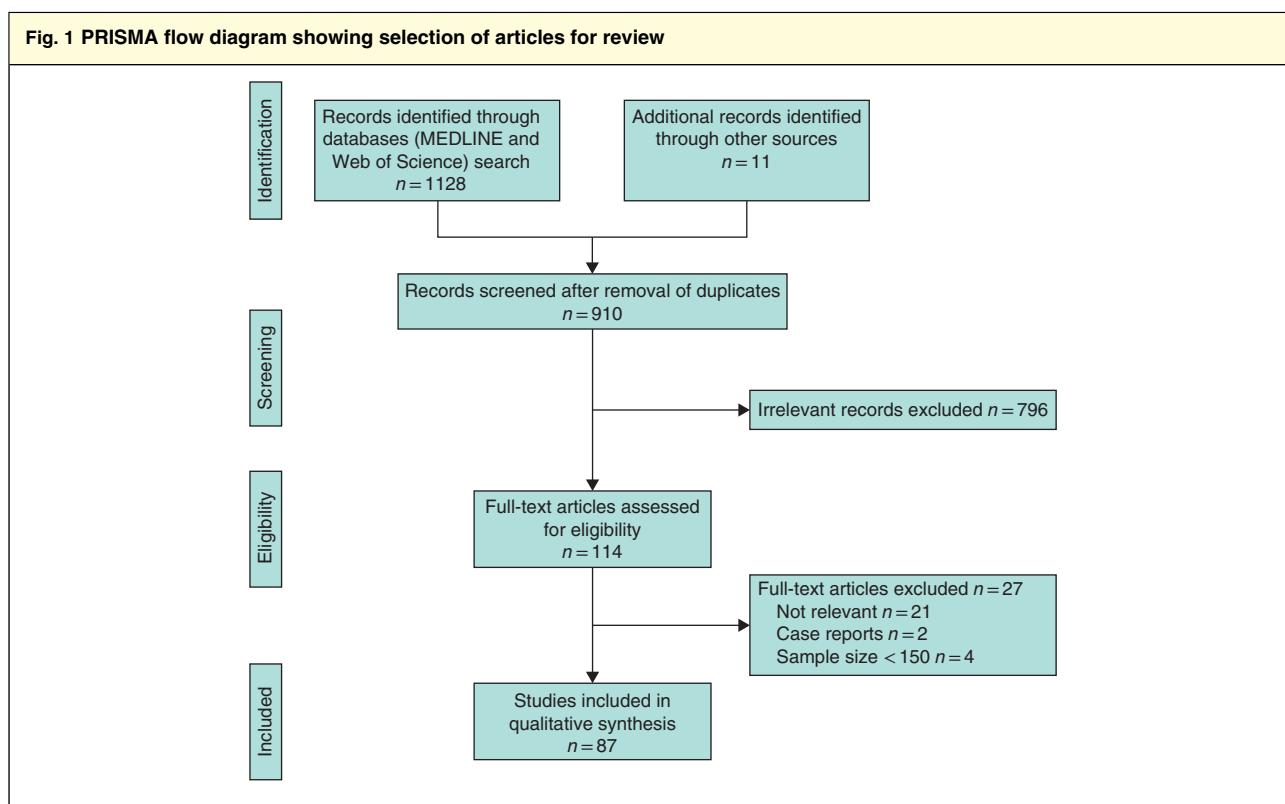
Definitions of lymphorrhoea and lymphocele were extracted. The parameters used to define lymphorrhoea and lymphocele included: fluid collection, lymph content, histology, location, size and timing. The sample size, incidence of lymphatic complications, and volume or size cut-off of asymptomatic and symptomatic lymphoceles were recorded. In addition, the symptoms of patients with symptomatic lymphoceles, and information regarding the diagnosis (ultrasound imaging, CT, etc.) and treatment of lymphorrhoea/lymphocele (aspiration, external drainage, sclerotherapy and surgery) were recorded.

Assessment of methodological quality

The quality of studies was assessed independently by two authors using the methodological index for non-randomized studies (MINORS)²¹. Disagreements were resolved by consensus. MINORS includes a total of 12 items; the first eight are related to non-comparative studies and a further four items are applicable only to comparative studies. The items are categorized and scored as 0 (not reported), 1 (reported but inadequate) or 2 (reported and adequate). In assessment of non-comparative studies, the highest possible score is 16; studies with fewer than 8 points were deemed to be of low quality, studies with 8–12 points of intermediate quality and those with more than 12 points of high quality. In assessment of comparative studies, the highest possible score is 24; studies with fewer than 12 points were considered to be of low quality, those with 12–18 points of intermediate quality, and those with more than 18 points of high quality.

Final agreement

The extracted data were used to create a comprehensive definition of lymphorrhoea and lymphocele. In addition, a grading system that defined the severity of lymphorrhoea/lymphocele based on the required management



strategies was suggested. Next, members of European high-volume transplantation centres (performing more than 100 kidney transplants per year) in Germany, Austria and Switzerland were invited to join a consensus team. The proposed definitions and severity grading system were reviewed by the consensus team, and a revised version was recirculated for further comments or final approval. After e-mail discussions, the definitions and grading system were approved by all members of the consensus team. As recommended by some consensus team members, ten clinical case examples with various clinical scenarios are presented to clarify uncertainties regarding application of the severity grading system.

Results

The literature search yielded 910 articles after removal of duplicates (*Fig. 1*). Eighty-seven articles^{4,5,9,11–14,22–101} met the inclusion criteria and were included in the report. Seventy-six articles reported on lymphoceles only, four articles on lymphorrhoea, and seven articles on lymphocele and lymphorrhoea. Forty-eight studies had a sample size of 150–500 procedures, 27 studies a sample size of 500–1000 and 12 studies included more than 1000 kidney transplants.

Qualitative analysis

Sixteen studies were of intermediate quality and the remaining 71 of poor quality (*Table S1*, supporting information). The quality of the included studies was poor because of retrospective design, lack of control group and inadequate follow-up.

Common terminology used in the literature

‘Post-renal/kidney transplantation lymphocele’, ‘lymphocele after renal/kidney transplantation’ and ‘lymph/lymphatic leakage/lymphorrhoea/lymph fistula following renal/kidney transplantation’ were the terms most commonly used to describe lymphatic complications after kidney transplantation. To standardize the terminology of these surgical complications, the consensus team proposes the terms ‘post-kidney transplantation lymphorrhoea’ and ‘post-kidney transplantation lymphocele’.

Components used to define lymphatic complications after kidney transplantation

The proposed definitions from published papers are listed in *Table 1*. The systematic review confirmed that

Table 1 Definitions of lymphorrhoea/lymphocele after kidney transplantation from published studies

Reference	No. of kidney transplants	Definition
Lymphorrhoea		
Inoue <i>et al.</i> ²⁴	244	Persistent lymphatic fluid leakage defined by removal of drain tube delayed for more than 15 postoperative days when the strategy was to remove the drain when the outflow was less than 50 ml
He <i>et al.</i> ²³	679	> 50 ml constant daily fluid leakage from drain
Król <i>et al.</i> ²⁶	369	Prolonged outflow of lymph through drain placed routinely in region of iliac fossa/transplanted kidney during transplant procedure
Guleria <i>et al.</i> ²²	356	High volume of lymphatic fluid output (> 60 ml) via perigraft suction drain in immediate postoperative period
Lymphocele		
Heer <i>et al.</i> ⁴²	250	Any fluid collection >50 ml around transplanted kidney
Singh <i>et al.</i> ⁴³	1720	Collection of lymph contained by a pseudomembrane
Dipalma <i>et al.</i> ⁴⁴	160	Presence of perigraft fluid collection with diameter > 5 cm and not covered by an epithelial membrane that was diagnosed more than 1 week after transplantation
Sim <i>et al.</i> ⁴⁵	154	Lymphatic collection around renal graft and urinary bladder
de Lima <i>et al.</i> ¹²	991	Pseudocystic entity with lymph content covered with a hard fibrous capsule
Choudhrie <i>et al.</i> ⁴⁶	744	Post-transplant lymphoceles are perigraft lymphatic fluid collections occurring after preparation of renal bed for graft
Lee <i>et al.</i> ⁴⁷	1363	Symptomatic lymphocele defined as a perigraft fluid collection accompanied by symptoms or an asymptomatic rise in serum creatinine
Ziętek <i>et al.</i> ²⁹	202	Lymphatic collection around a transplanted kidney
Nelson <i>et al.</i> ⁴⁸	685	Accumulation of lymphatic fluid around a kidney transplant thought to be due to disrupted lymphatic channels of implanted kidney or iliac vessels
Zagdoun <i>et al.</i> ¹³	269	Accumulation of lymph of variable size surrounded by pseudomembranes and located around graft
Veeramani <i>et al.</i> ⁴⁹	1709	Presence of perirenal fluid with diameter > 5 cm, diagnosed after first postoperative week
Król <i>et al.</i> ²⁶	369	Lymph collection that forms after surgery following injury of lymph nodes and vessels
Knight <i>et al.</i> ³⁹	263	Subfascial perirenal fluid collection confirmed by either ultrasound imaging or CT
Samhan and Al-Mousawi ⁵⁰	528	Fluid collection between renal graft and urinary bladder
Smyth <i>et al.</i> ⁵¹	1289	Perigraft fluid collection following preparation of renal bed or graft, not caused by urinary leakage or haemorrhage
Hamza <i>et al.</i> ¹⁴	620	Accumulation of lymph surrounded by pseudomembranes (layers of tissue with reaction of surrounding tissue) around graft, usually in lower or upper medial region, and often located suprapubically
Hernández <i>et al.</i> ⁵²	870	Collection designated as lymphocele if cell counts from direct aspirates proved lymphatic content
Tasar <i>et al.</i> ²⁷	300	Fluid-filled cysts lacking an epithelial lining that occur after surgical severance and inadequate closure of one or more lymphatic vessels
Zargar-Shoshtari <i>et al.</i> ⁴⁰	2147	Fluid collection between kidney allograft and bladder
Dubeaux <i>et al.</i> ³⁸	450	Fluid collections most frequently found following kidney transplantation
Bailey <i>et al.</i> ⁴	685	Collections of lymph in a non-epithelialized cavity
Guleria <i>et al.</i> ²²	356	Fluid collection, composed of lymph, which lies between inferior pole of kidney and bladder
Valente <i>et al.</i> ⁵³	236	Fluid collection designated as lymphocele if cell counts from direct aspirates proved lymphatic content
Langer and Kahan ⁴¹	490	Lymphatic collections lacking epithelial lining
Pourmand <i>et al.</i> ⁵⁴	394	Cystic collections develop when lymph is not completely absorbed by peritoneum
Sansalone <i>et al.</i> ³²	280	Fluid collection >3 cm in diameter demonstrated after needle aspiration
Lipay <i>et al.</i> ⁵⁵	170	Perirenal fluid collection >100 ml
Montalvo <i>et al.</i> ³³	543	Collection of lymph in a non-epithelialized cavity lined with fibromembranous tissue
Gruessner <i>et al.</i> ³⁰	1148	On histopathological examination, lymphoceles are lymphatic fluid collections without an epithelial lining
Fortenbery <i>et al.</i> ⁵⁶	305	Fluid collection with electrolyte and creatinine levels similar to those of the patient's plasma

no accepted definition exists for lymphorrhoea and lymphocele. Lymphorrhoea/lymphocele was not defined in more than 60 per cent of included articles. Thirty-two articles defined lymphorrhoea or lymphocele. The main indicators were: fluid collection in 20 articles (67 per cent), lymph content in 18, histology of the membrane in ten, location of lymphocele in 16, size of lymphocele in seven and timing of diagnosis in two articles (7 per cent). The reported rates of lymphocele ranged from 0.6 to 33.9 per cent (*Table S2*, supporting information).

Symptoms of lymphatic complications after kidney transplantation

Fifty-five of 87 articles (63 per cent) reported the incidence of symptomatic lymphoceles, and 20 (23 per cent) reported symptomatic and asymptomatic lymphoceles separately. They included general, visceral, vascular and renal symptoms (*Table S3*, supporting information). General symptoms were reported in 18 articles (21 per cent): infection in 10 per cent, fever in 9 per cent, liquid leakage in 7 per cent and wound dehiscence in 2 per cent of articles. Visceral symptoms were reported in 30 articles (34 per cent): abdominal pain in 24 per cent, mass in 10 per cent and abdominal swelling in 9 per cent of articles. Vascular complications were documented in 36 articles (41 per cent): leg oedema in 36 per cent, vein compression in 7 per cent, deep vein thrombosis in 6 per cent and arterial hypertension in 1 per cent of articles. Renal symptoms were reported in 43 articles (49 per cent): increased creatinine level in 22 per cent, graft dysfunction in 18 per cent, obstruction in 18 per cent and hydronephrosis in 15 per cent of articles.

Radiological assessment

The method of radiological assessment was documented in 65 articles (75 per cent) (*Table S4*, supporting information). Seventy-one per cent of studies used ultrasound imaging; CT was used in 31 per cent, and other radiological assessments in 18 per cent.

Management

Sixty-three articles (72 per cent) reported how lymphatic complications after kidney transplantation were managed. Aspiration of lymphoceles was used in 27 studies (31 per cent), external drainage in 35 (40 per cent) and sclerotherapy (such as ethanol, povidone-iodine or tetracycline) in 19 (22 per cent) (*Table S4*, supporting information). In 52 articles (60 per cent), management of lymphoceles was surgical: 50 per cent equal numbers of laparoscopic and open

procedures, 12 per cent only laparoscopic and 2 per cent only open surgery; 36 per cent of papers did not specify the surgical method. The use of sclerotherapy for lymphorrhoea was reported in two articles^{22,23}.

Agreed definition of lymphatic complications after kidney transplantation

Fluid content, fluid volume and duration of leakage were included in the published definitions. Leakage was usually analysed biochemically to rule out urine, blood or pus when more than 30–50 ml of fluid leaked per day. However, some authors analysed the leakage only after 30–50 ml of fluid continued to leak daily after postoperative days 7–10. The consensus team proposed the following definition of lymphorrhoea after kidney transplantation: leakage of more than 50 ml fluid (not urine, blood or pus) per day from the drain, or the drain site after removal of the drain, for more than 1 week after kidney transplantation.

Most published definitions of lymphocele included content of the fluid, histology of the surrounding membrane, location of the lymphocele and size of accumulated fluid. Terms frequently used to describe the surrounding membrane of a lymphocele included pseudocyst, cavity surrounded by pseudomembrane, or non-epithelialized cavity. There was no cut-off size that defined a fluid collection as a lymphocele. Fluid that accumulates after a kidney transplant may have different contents. It is generally agreed that the term lymphocele is used only when urinoma, haematoma and abscess have been ruled out. The consensus team defined lymphocele as: fluid collection of any size near to the transplanted kidney, after urinoma, haematoma and abscess have been excluded. This definition applies to both asymptomatic and symptomatic lymphoceles.

Proposed grading of severity of lymphatic complications after kidney transplantation

The severity of lymphorrhoea/lymphocele has not been graded consistently in the literature (*Table S3*, supporting information). One study²⁴ reported persistent lymphatic fluid leakage as removal of the drain delayed for more than 15 postoperative days. Focusing on lymphocele, most authors (20 articles) categorized lymphoceles as asymptomatic or symptomatic, according to the clinical symptoms. Presser and colleagues²⁵ classified lymphoceles into three groups according to treatment: open surgery, laparoscopic surgery and fibrin glue treatment. Only symptomatic lymphoceles were reported in 35 studies; lymphoceles were classified by size in three studies, and lymphoceles were not classified either by symptoms or size in 25 studies. The consensus team recommended a

Table 2 Proposed severity grading of lymphatic complications after kidney transplantation

	Grade A	Grade B	Grade C
Treatment	None/diagnostic or therapeutic aspiration (puncture)	Non-surgical intervention (percutaneous external drainage, sclerotherapy, double-J stent, radiation)	Surgical treatment (laparoscopic/open)
Persistence	No	No/yes	Yes
Loculation	Non-loculated	Non-loculated	Non-loculated/loculated
Infection	No	No/yes	No/yes
Rise in serum creatinine levels	No	Usually no	No/yes
Previous failed non-surgical intervention	No	No/yes	Usually yes
Previous failed surgical intervention	No	No	No/yes

simple grading system to classify lymphatic complications based on the severity and invasiveness of the management strategy: grades A, B and C, where grade A requires the least invasive and grade C the most invasive management strategy (Table 2).

Grade A lymphatic complications

Grade A complications need no treatment or are treated with aspiration. They have a minor and/or non-invasive impact on clinical management. Grade A lymphorrhoea may prolong the hospital stay. Drain removal may need to be postponed for more than 7 days because of increasing or constant drain outflow. Fluid may continue to leak after drain removal. Grade A lymphorrhoea should cease spontaneously. Grade A lymphoceles are usually diagnosed incidentally during routine ultrasound examination. Grade A lymphoceles do not progress and usually resolve after aspiration.

Grade B lymphatic complications

Grade B complications need non-surgical intervention. Leakage in grade B lymphorrhoea does not resolve spontaneously and requires further intervention, such as medical therapy (for example somatostatin), sclerosing agents or radiotherapy. Infected or complicated lymphorrhoea that needs antibiotic treatment is also classified as grade B. Patients with a grade B lymphocele usually present with clinically relevant symptoms, which are characterized as general, visceral, renal and/or vascular (Table S3, supporting information). Creatinine levels may rise in patients with grade B lymphocele. Grade B lymphoceles are managed non-surgically with percutaneous drainage with or without sclerotherapy, sclerotherapy alone, or radiation. Lymphoceles that are treated by repeated non-surgical intervention, and those that necessitate decompression of the ureter by insertion of a double-J stent, are also classified as grade B.

Grade C lymphatic complications

Grade C complications require invasive surgical intervention (open or laparoscopic). They include: persistent lymphorrhoea that needs surgical treatment; lymphoceles that are loculated or inappropriately located for non-surgical intervention; recur after drainage and/or sclerotherapy and need to be managed surgically; were not treated successfully by, or recurred after, surgical intervention; and are managed surgically during an operation for other co-morbidities or conditions (for example, incisional/umbilical hernia, fascial dehiscence, acute appendicitis). When non-surgical treatment of a grade A/B lymphocele leads to a complication that has to be treated surgically (such as bleeding or intestinal perforation) it should be also graded as C.

Examples

A new grading system needs to be explained using clinical examples to facilitate its use in routine clinical practice. To clarify the application of the proposed severity grading system, ten clinical examples are described in Table S5 (supporting information).

Discussion

Lymphatic complications, including lymphorrhoea and lymphocele, are common after kidney transplantation. Despite significant improvements in prevention, diagnosis and management, standard definitions and a severity grading system have not yet been established^{5,10,11,13,102}. The aim of this report was to suggest standard definitions and a severity grading system for lymphatic complications based on management strategy, to facilitate comparison of results across studies. The goal was to propose neither clinical guidelines (treatment action plan), nor a management strategy.

Intraoperative drainage is commonly used after kidney transplantation^{2,26,103}. Although drainage decreases the incidence of lymphocele^{10,26}, it can lead to lymphorrhoea. Lymph leakage can occur if a drain is inserted, or if a drain is not used. As a result, the peak incidence of lymphorrhoea and lymphocele is heterogeneous, and may be up to 6 months after kidney transplantation.

The proposed definitions and severity grading system are based on fluid content, fluid volume, duration of leakage and management, but not size. Lymphocele size can affect the development of symptoms, but these depend on the location of the lymphocele and size of the patient. Some small lymphoceles can disturb graft function; in contrast, some large ones exert no pressure on the graft and are asymptomatic. Therefore, size is not a reliable parameter for grading the severity of lymphoceles after transplantation. Most fluid collections are asymptomatic²⁷, and in almost all instances asymptomatic collections require no treatment^{5,9,13,25,28,29}. A rise in serum creatinine levels may not be associated with clinical symptoms. Atray and colleagues³ reported raised creatinine levels in 60 per cent of patients with a lymphocele but without any symptoms. These patients normally required invasive diagnostic and therapeutic procedures³, so the lymphatic complications would be graded as B or C according to the proposed system, even though the patients were asymptomatic.

Lymphatic complications after kidney transplantation have not been graded before, except into asymptomatic and symptomatic categories^{11,26,34,36}. Lymphoceles are not usually managed according to their size³⁷, although Hamza and co-workers¹⁴ treated all lymphoceles greater than 80 ml, irrespective of the symptoms, and Dubeaux *et al.*³⁸ operated on asymptomatic lymphoceles based on their size. Ulrich and colleagues¹¹ drained symptomatic lymphoceles between 3 and 5 cm, and operated on those with a diameter greater than 5 cm. Location and accessibility are also important factors. If the lymphocele is located deep within the pelvic cavity adjacent to the iliac vessels⁵ or inferomedially³⁷, aspiration may be difficult or impossible⁴⁰, and surgery is the only possibility. Septation of the lymphocele also influences the therapeutic approach. Zargar-Shoshtari and co-workers⁴⁰ demonstrated that aspiration was possible for non-loculated lymphoceles, whereas loculated ones should be treated surgically^{37,40,41}.

The severity of lymphatic complications should be graded according to required clinical management rather than size, symptoms, location or loculation. This is in accordance with suggested grading systems for other surgical complications^{17,18,104}. No treatment is required for grade A lymphorrhoea, but lymphatic leak or

hospitalization may be prolonged. After aspiration, grade A lymphoceles do not persist or recur. In contrast, grade B lymphatic complications affect the clinical course if drain insertion, drain replacement, sclerotherapy or radiotherapy is required. Surgically managed patients are exposed to anaesthetic and procedure-related complications; therefore, these should be classified as grade C.

Although the definitions and severity grading system for lymphatic complications after kidney transplantation presented here should minimize the discrepancy in reporting between centres, the lack of standards in radiological assessment should be noted as a potential limitation. The lymphocele rate may vary between centres because of differences in diagnostic tools and radiological assessments, and may be underdiagnosed or overdiagnosed as a result.

The proposed definitions and severity grading of lymphatic complications after kidney transplantation are the result of a consensus between large-volume European centres. The severity grading approach is based on management strategy, and does not consider size, symptoms or location, while treatment selection mainly depends on the patient's clinical condition, the surgeon's preference and skills and centers' policies. The proposed definition and grading system does not aim to suggest a treatment action plan, or a management strategy, but represents the effect of chosen treatment strategy, regardless of why it was selected. The aim was to standardize reported results and to allow comparison between studies. The proposed definitions and grading system should be validated in future studies.

Acknowledgements

A.M. and Y.K. contributed equally to this work. A. Mehrabi, W. O. Bechstein, G. A. Berlakovich, N. Demartines, M. Duran, L. Fischer, L. Gürke, J. Klempnauer, A. Königsrainer, H. Lang, U. P. Neumann, A. Pascher, A. Paul, P. Pisarski, J. Pratschke, S. Schneeberger, U. Settmacher, R. Viebahn, M. Wirth, B. Wullich and M. Zeier are members of the European consensus team. No preregistration exists for the studies reported in this article.

Disclosure: The authors declare no conflict of interest.

References

- 1 Ranghino A, Segoloni GP, Lasaponara F, Biancone L. Lymphatic disorders after renal transplantation: new insights for an old complication. *Clin Kidney J* 2015; **8**: 615–622.
- 2 Golriz M, Klauss M, Zeier M, Mehrabi A. Prevention and management of lymphocele formation following kidney transplantation. *Transplant Rev (Orlando)* 2016; **31**: 100–105.

- 3 Atray NK, Moore F, Zaman F, Caldito G, Abreo K, Maley W *et al.* Post transplant lymphocele: a single centre experience. *Clin Transplant* 2004; **18**(Suppl 12): 46–49.
- 4 Bailey SH, Mone MC, Holman JM, Nelson EW. Laparoscopic treatment of post renal transplant lymphoceles. *Surg Endosc* 2003; **17**: 1896–1899.
- 5 Goel M, Flechner SM, Zhou L, Mastroianni B, Savas K, Derweesh I *et al.* The influence of various maintenance immunosuppressive drugs on lymphocele formation and treatment after kidney transplantation. *J Urol* 2004; **171**: 1788–1792.
- 6 Amante AJ, Kahan BD. Technical complications of renal transplantation. *Surg Clin North Am* 1994; **74**: 1117–1131.
- 7 Mehrabi A, Golriz M, Khajeh E, Ghamarnejad O, Kulu Y, Wiesel M *et al.* Surgical outcomes after pediatric kidney transplantation at the University of Heidelberg. *J Pediatr Urol* 2019; **15**: 221.e1–221.e8.
- 8 Lucewicz A, Wong G, Lam VWT, Hawthorne WJ, Allen R, Craig JC *et al.* Management of primary symptomatic lymphocele after kidney transplantation: a systematic review. *Transplantation* 2011; **92**: 663–673.
- 9 Pollak R, Veremis SA, Maddux MS, Mozes MF. The natural history of and therapy for perirenal fluid collections following renal transplantation. *J Urol* 1988; **140**: 716–720.
- 10 Syversveen T, Midtvedt K, Brabrand K, Øyen O, Foss A, Scholz T. Prophylactic peritoneal fenestration to prevent morbidity after kidney transplantation: a randomized study. *Transplantation* 2011; **92**: 196–202.
- 11 Ulrich F, Niedzwiecki S, Fikatas P, Nebrig M, Schmidt SC, Kohler S *et al.* Symptomatic lymphoceles after kidney transplantation – multivariate analysis of risk factors and outcome after laparoscopic fenestration. *Clin Transplant* 2010; **24**: 273–280.
- 12 de Lima ML, Cotrim CAC, Moro JC, Miyaoka R, D’Ancona CAL. Laparoscopic treatment of lymphoceles after renal transplantation. *Int Braz J Urol* 2012; **38**: 215–221.
- 13 Zagdoun E, Ficheux M, Lobbedez T, Chatelet V, Thuillier-Lecouf A, Bensadoun H *et al.* Complicated lymphoceles after kidney transplantation. *Transplant Proc* 2010; **42**: 4322–4325.
- 14 Hamza A, Fischer K, Koch E, Wicht A, Zacharias M, Loertzer H *et al.* Diagnostics and therapy of lymphoceles after kidney transplantation. *Transplant Proc* 2006; **38**: 701–706.
- 15 Rahbari NN, Garden OJ, Padbury R, Brooke-Smith M, Crawford M, Adam R *et al.* Posthepatectomy liver failure: a definition and grading by the International Study Group of Liver Surgery (ISGLS). *Surgery* 2011; **149**: 713–724.
- 16 Bassi C, Dervenis C, Butturini G, Fingerhut A, Yeo C, Izbicki J *et al.*; International Study Group on Pancreatic Fistula Definition. Postoperative pancreatic fistula: an international study group (ISGPF) definition. *Surgery* 2005; **138**: 8–13.
- 17 Wente MN, Veit JA, Bassi C, Dervenis C, Fingerhut A, Gouma DJ *et al.* Postpancreatectomy hemorrhage (PPH): an International Study Group of Pancreatic Surgery (ISGPS) definition. *Surgery* 2007; **142**: 20–25.
- 18 Rahbari NN, Weitz J, Hohenberger W, Heald RJ, Moran B, Ulrich A *et al.* Definition and grading of anastomotic leakage following anterior resection of the rectum: a proposal by the International Study Group of Rectal Cancer. *Surgery* 2010; **147**: 339–351.
- 19 Koch M, Garden OJ, Padbury R, Rahbari NN, Adam R, Capussotti L *et al.* Bile leakage after hepatobiliary and pancreatic surgery: a definition and grading of severity by the International Study Group of Liver Surgery. *Surgery* 2011; **149**: 680–688.
- 20 Moher D, Liberati A, Tetzlaff J, Altman DG; PRISMA Group. Preferred reporting items for systematic reviews and meta-analyses: the PRISMA statement. *PLoS Med* 2009; **6**: e1000097.
- 21 Slim K, Nini E, Forestier D, Kwiatkowski F, Panis Y, Chipponi J. Methodological index for non-randomized studies (minors): development and validation of a new instrument. *ANZ J Surg* 2003; **73**: 712–716.
- 22 Guleria S, Mehta SN, Mandal S, Aggarwal S, Gupta S, Bhowmik D *et al.* Povidone–iodine in the treatment of lymphatic fistulae in renal transplant recipients. *Transplant Proc* 2003; **35**: 327–328.
- 23 He S, Song T, Xie L, Fu L, Huang Z, Lin T. Stilamin in the treatment of lymphatic leaks after living-related renal transplantation. *Transplant Proc* 2013; **45**: 3302–3304.
- 24 Inoue T, Saito M, Narita S, Numakura K, Tsuruta H, Maeno A *et al.* Evaluation of persistent lymphatic fluid leakage using a strategy of placing a drain after kidney transplantation: a statistical analysis to assess its origin. *Transplant Proc* 2017; **49**: 1786–1790.
- 25 Presser N, Kerr H, Gao T, Begala M, Paschal S, Shoskes DA *et al.* Fibrin glue injections: a minimally invasive and cost-effective treatment for post-renal transplant lymphoceles and lymph fistulas. *Am J Transplant* 2016; **16**: 694–699.
- 26 Król R, Kolonko A, Chudek J, Ziaja J, Pawlicki J, Mały A *et al.* Did volume of lymphocele after kidney transplantation determine the choice of treatment modality? *Transplant Proc* 2007; **39**: 2740–2743.
- 27 Tasar M, Gulec B, Saglam M, Yavuz I, Bozlar U, Ugurel S. Posttransplant symptomatic lymphocele treatment with percutaneous drainage and ethanol sclerosis: long-term follow-up. *Clin Imaging* 2005; **29**: 109–116.
- 28 Ishitani MB, DeAngelis GA, Siström CL, Rodgers BM, Pruett TL. Laparoscopic ultrasound-guided drainage of lymphoceles following renal transplantation. *J Laparoendosc Surg* 1994; **4**: 61–64.
- 29 Ziętek Z, Iwan-Ziętek I, Sulikowski T, Sienko J, Nowacki M, Zukowski M *et al.* The outcomes of treatment and the etiology of lymphoceles with a focus on hemostasis in kidney recipients: a preliminary report. *Transplant Proc* 2011; **43**: 3008–3012.
- 30 Gruessner RW, Fasola C, Benedetti E, Foshager MC, Gruessner AC, Matas AJ *et al.* Laparoscopic drainage of

- lymphoceles after kidney transplantation: indications and limitations. *Surgery* 1995; **117**: 288–295.
- 31 Längle F, Schurawitzki H, Mühlbacher F, Steininger R, Watschinger B, Derfler K *et al.* Treatment of lymphoceles following renal transplantation. *Transplant Proc* 1990; **22**: 1420–1422.
 - 32 Sansalone CV, Aseni P, Minetti E, Di Benedetto F, Rossetti O, Manoochehri F *et al.* Is lymphocele in renal transplantation an avoidable complication? *Am J Surg* 2000; **179**: 182–185.
 - 33 Montalvo BM, Yrizarry JM, Casillas VJ, Burke GW III, Allouch M, Amendola MA *et al.* Percutaneous sclerotherapy of lymphoceles related to renal transplantation. *J Vasc Interv Radiol* 1996; **7**: 117–123.
 - 34 Shokeir AA, el-Diasty TA, Ghoneim MA. Percutaneous treatment of lymphocele in renal transplant recipients. *J Endourol* 1993; **7**: 481–485.
 - 35 Cadrobbi R, Zaninotto G, Rigotti P, Baldan N, Sarzo G, Ancona E. Laparoscopic treatment of lymphocele after kidney transplantation. *Surg Endosc* 1999; **13**: 985–990.
 - 36 Huilgol AK, Sundar S, Karunakaran SG, Sudhakar S, Sreenivasa Prasad MA, Ravindran T. Lymphoceles and their management in renal transplantation. *Transplant Proc* 2003; **35**: 323.
 - 37 Berardinelli L, Raiteri M, Pasciucchio A, Carini M. The use of a polymeric sealant for prevention of posttransplantation lymphocele. *Transplant Proc* 2011; **43**: 1072–1073.
 - 38 Dubeaux VT, Oliveira RM, Moura VJ, Pereira JMS, Henriques FP. Assessment of lymphocele incidence following 450 renal transplantations. *Int Braz J Urol* 2004; **30**: 18–21.
 - 39 Knight RJ, Villa M, Laskey R, Benavides C, Schoenberg L, Welsh M *et al.* Risk factors for impaired wound healing in sirolimus-treated renal transplant recipients. *Clin Transplant* 2007; **21**: 460–465.
 - 40 Zargar-Shoshtari MA, Soleimani M, Salimi H, Mehravaran K. Symptomatic lymphocele after kidney transplantation: a single-center experience. *Urol J* 2008; **5**: 34–36.
 - 41 Langer RM, Kahan BD. Incidence, therapy, and consequences of lymphocele after sirolimus–cyclosporine–prednisone immunosuppression in renal transplant recipients. *Transplantation* 2002; **74**: 804–808.
 - 42 Heer MK, Clark D, Trevillian PR, Sprott P, Palazzi K, Hibberd AD. Functional significance and risk factors for lymphocele formation after renal transplantation. *ANZ J Surg* 2018; **88**: 597–602.
 - 43 Singh AG, Jai SJ, Ganpule AP, VijayKumar M, Sabnis RB, Desai MR. Critical appraisal of consecutive 36 cases of post renal transplant lymphocele: a proposed algorithm. *World J Urol* 2017; **35**: 1443–1450.
 - 44 Divalpa T, Fernández-Ruiz M, Praga M, Polanco N, González E, Gutiérrez-Solis E *et al.* Pre-transplant dialysis modality does not influence short- or long-term outcome in kidney transplant recipients: analysis of paired kidneys from the same deceased donor. *Clin Transplant* 2016; **30**: 1097–1107.
 - 45 Sim A, Ng LG, Cheng C. Occurrence of a lymphocele following renal transplantation. *Singapore Med J* 2013; **54**: 259–262.
 - 46 Choudhrie AV, Kumar S, Gnanaraj L, Devasia A, Chacko N, Kekre NS. Symptomatic lymphoceles post renal transplant. *Saudi J Kidney Dis Transpl* 2012; **23**: 1162–1168.
 - 47 Lee HS, Joo DJ, Huh KH, Kim MS, Kim SI, Kim YS *et al.* Laparoscopic fenestration versus percutaneous catheter drainage for lymphocele treatment after kidney transplantation. *Transplant Proc* 2013; **45**: 1667–1670.
 - 48 Nelson EW, Gross ME, Mone MC, Hansen HJ, Sheng X, Cannon KM *et al.* Does ultrasonic energy for surgical dissection reduce the incidence of renal transplant lymphocele? *Transplant Proc* 2011; **43**: 3755–3759.
 - 49 Veeramani M, Mishra S, Kurien A, Ganpule A, Sabnis R, Desai M. Does rejection have a role in lymphocele formation post renal transplantation? A single centre experience. *Indian J Urol* 2010; **26**: 193–195.
 - 50 Samhan M, Al-Mousawi M. Lymphocele following renal transplantation. *Saudi J Kidney Dis Transpl* 2006; **17**: 34–37.
 - 51 Smyth GP, Beitz G, Eng MP, Gibbons N, Hickey DP, Little DM. Long-term outcome of cadaveric renal transplant after treatment of symptomatic lymphocele. *J Urol* 2006; **176**: 1069–1072.
 - 52 Hernández D, Rufino M, Armas S, González A, Gutiérrez P, Barbero P *et al.* Retrospective analysis of surgical complications following cadaveric kidney transplantation in the modern transplant era. *Nephrol Dial Transplant* 2006; **21**: 2908–2915.
 - 53 Valente JF, Hricik D, Weigel K, Seaman D, Knauss T, Siegel CT *et al.* Comparison of sirolimus vs. mycophenolate mofetil on surgical complications and wound healing in adult kidney transplantation. *Am J Transplant* 2003; **3**: 1128–1134.
 - 54 Pourmand G, Mehra AR, Taheri M. Evaluation of endourological interventions used to treat urological complications in 394 kidney recipients. *Transplant Proc* 2000; **32**: 524–525.
 - 55 Lipay MA, Noronha IDL, Vidonho Júnior A, Romão Júnior JE, Campagnari JC, Srougi M. Lymphocele: a possible relationship with acute cellular rejection in kidney transplantation. *Sao Paulo Med J* 1999; **117**: 238–242.
 - 56 Fortenbery EJ, Blue PW, Van Nostrand D, Anderson JH. Lymphocele: the spectrum of scintigraphic findings in lymphoceles associated with renal transplant. *J Nucl Med* 1990; **31**: 1627–1631.
 - 57 Burghuber CK, Kandioler D, Strobl S, Mittlböck M, Böhmig GA, Soliman T *et al.* Standardized intraoperative application of an absorbable polysaccharide hemostatic powder to reduce the incidence of lymphocele after kidney transplantation – a prospective trial. *Transpl Int* 2018; **32**: 59–65.

- 58 Ahmed RR, Halabi E, Fathi T, Al-Mousawi M. Postoperative surgical complications of live unrelated renal transplants for patients of end stage renal disease needing renal replacement therapy. *J Coll Physicians Surg Pak* 2018; **28**: 941–944.
- 59 Ueno P, Felipe C, Ferreira A, Cristelli M, Viana L, Mansur J *et al.* Wound healing complications in kidney transplant recipients receiving everolimus. *Transplantation* 2017; **101**: 844–850.
- 60 Bzoma B, Kostro J, Dębska-Ślizień A, Hellmann AR, Zadrożny D, Śledziński Z *et al.* Treatment of the lymphocele after kidney transplantation: a single-center experience. *Transplant Proc* 2016; **48**: 1637–1640.
- 61 Koch M, Kantas A, Ramcke K, Drabik AI, Nashan B. Surgical complications after kidney transplantation: different impacts of immunosuppression, graft function, patient variables, and surgical performance. *Clin Transplant* 2015; **29**: 252–260.
- 62 Lempinen M, Stenman J, Kyllönen L, Salmela K. Surgical complications following 1670 consecutive adult renal transplantations: a single center study. *Scand J Surg* 2015; **104**: 254–259.
- 63 Baston C, Harza M, Preda A, Gener I, Manea I, Voinea S *et al.* Comparative urologic complications of ureteroneocystostomy in kidney transplantation: transvesical Leadbetter–Politano *versus* extravesical Lich–Gregoir technique. *Transplant Proc* 2014; **46**: 176–179.
- 64 Behzadi AH, Kamali K, Zargar M, Abbasi MA, Piran P, Bastani B. Obesity and urologic complications after renal transplantation. *Saudi J Kidney Dis Transpl* 2014; **25**: 303–308.
- 65 Slagt IKB, Ijzermans JNM, Visser LJ, Weimar W, Roodnat JJ, Terkivatan T. Independent risk factors for urological complications after deceased donor kidney transplantation. *PLoS One* 2014; **9**: e91211.
- 66 Bozkurt B, Koçak H, Dumlu EG, Mesci A, Bahadır V, Tokaç M *et al.* Favorable outcome of renal grafts with multiple arteries: a series of 198 patients. *Transplant Proc* 2013; **45**: 901–903.
- 67 Barba J, Algarra R, Romero L, Tienza A, Velis JM, Robles JE *et al.* Recipient and donor risk factors for surgical complications following kidney transplantation. *Scand J Urol* 2013; **47**: 63–71.
- 68 Pillot P, Bardonnaud N, Lillaz J, Delorme G, Chabannes E, Bernardini S *et al.* Risk factors for surgical complications after renal transplantation and impact on patient and graft survival. *Transplant Proc* 2012; **44**: 2803–2808.
- 69 Skauby M, Horneland R, Leivestad T, Scholz T, Oyen O. A significantly decreased rate of lymphoceles/lymph leakage after kidney transplantation is probably caused by reduction of the initial steroid dosing. *Transplantation* 2012; **94**: 901.
- 70 Furrriel F, Parada B, Campos L, Moreira P, Castelo D, Dias V *et al.* Pretransplantation overweight and obesity: does it really affect kidney transplantation outcomes? *Transplant Proc* 2011; **43**: 95–99.
- 71 Røine E, Bjørk IT, Oyen O. Targeting risk factors for impaired wound healing and wound complications after kidney transplantation. *Transplant Proc* 2010; **42**: 2542–2546.
- 72 Ekberg H, Bernasconi C, Nöldeke J, Yussim A, Mjörnstedt L, Erken U *et al.* Cyclosporine, tacrolimus and sirolimus retain their distinct toxicity profiles despite low doses in the Symphony study. *Nephrol Dial Transplant* 2010; **25**: 2004–2010.
- 73 Abad JB, Mayans AR, Eizaguirre ET, Vargas LR, Costa DR, García JER *et al.* Surgical complications in kidney transplantation and their influence on graft survival. *Actas Urol Esp* 2010; **34**: 266–273.
- 74 Iwan-Zietek I, Zietek Z, Sulikowski T, Nowacki M, Zair L, Romanowski M *et al.* Minimally invasive methods for the treatment of lymphocele after kidney transplantation. *Transplant Proc* 2009; **41**: 3073–3076.
- 75 Saidi RF, Wertheim JA, Kennealey P, Ko DSC, Elias N, Yeh H *et al.* Donor kidney recovery methods and the incidence of lymphatic complications in kidney transplant recipients. *Int J Organ Transplant Med* 2010; **1**: 40–43.
- 76 Dinçkan A, Tekin A, Turkyilmaz S, Kocak H, Gurkan A, Erdogan O *et al.* Early and late urological complications corrected surgically following renal transplantation. *Transpl Int* 2007; **20**: 702–707.
- 77 Tondolo V, Citterio F, Massa A, Salerno MP, Romagnoli J, Nanni G *et al.* Lymphocele after renal transplantation: the influence of the immunosuppressive therapy. *Transplant Proc* 2006; **38**: 1051–1052.
- 78 Shum CF, Lau KO, Sy JL, Cheng WS. Urological complications in renal transplantation. *Singapore Med J* 2006; **47**: 388–391.
- 79 Burgos FJ, Pascual J, Quicios C, Marcen R, Fernández A, López Fando L *et al.* Post-kidney transplant surgical complications under new immunosuppressive regimens. *Transplant Proc* 2006; **38**: 2445–2447.
- 80 Mazzucchi E, Souza AA, Nahas WC, Antonopoulos IM, Piovesan AC, Arap S. Surgical complications after renal transplantation in grafts with multiple arteries. *Int Braz J Urol* 2005; **31**: 125–130.
- 81 Shaheen FA, Basri N, Mohammed Z, Abdullah K, Haider R, Awad A *et al.* Experience of renal transplantation at the King Fahd Hospital, Jeddah, Saudi Arabia. *Saudi J Kidney Dis Transpl* 2005; **16**: 562–572.
- 82 Koçak T, Nane I, Ander H, Ziyilan O, Oktar T, Ozsoy C. Urological and surgical complications in 362 consecutive living related donor kidney transplantations. *Urol Int* 2004; **72**: 252–256.
- 83 Chandrasekaran D, Meyyappan RM, Rajaraman T. Instillation of povidone iodine to treat and prevent lymphocele after renal transplantation. *BJU Int* 2003; **91**: 296.
- 84 Fuller TF, Kang SM, Hirose R, Feng S, Stock PG, Freise CE. Management of lymphoceles after renal transplantation: laparoscopic *versus* open drainage. *J Urol* 2003; **169**: 2022–2025.

- 85 Chin AI, Ragavendra N, Hilborne L, Gritsch HA. Fibrin sealant sclerotherapy for treatment of lymphoceles following renal transplantation. *J Urol* 2003; **170**: 380–383.
- 86 Garay JM, Alberú J, Angulo-Suárez M, Bezauri-Rivas P, Herrera MF. Laparoscopic drainage of lymphocele after kidney transplant. *J Laparoendosc Adv Surg Tech A* 2003; **13**: 127–129.
- 87 Øyen O, Siwach V, Line PD, Pfeffer P, Lien B, Bentdal O *et al.* Improvement of post-transplant lymphocele treatment in the laparoscopic era. *Transpl Int* 2002; **15**: 406–410.
- 88 Gupta RS, Niranjani J, Srivastava A, Kumar A. Lymphoceles following renal transplantation: comparison of open surgical and laparoscopic deroofting. *Indian J Urol* 2001; **18**: 36.
- 89 Chen CH, Shu KH, Yang CR, Cheng CH, Wu MJ, Lian JD. Long-term results with pediatric kidney transplants in adult recipients. *J Formos Med Assoc* 1999; **98**: 807–813.
- 90 D'Alessandro AM, Pirsch JD, Knechtle SJ, Odorico JS, Van der Werf WJ, Collins BH *et al.* Living unrelated renal donation: the University of Wisconsin experience. *Surgery* 1998; **124**: 604–611.
- 91 Bischof G, Rockenschaub S, Berlakovich G, Längle F, Mühlbacher F, Függer R *et al.* Management of lymphoceles after kidney transplantation. A critical review. *Transpl Int* 1998; **11**: 277–280.
- 92 Melvin W, Bumgardner G, Davies E, Elkhammas E, Henry M, Ferguson R. The laparoscopic management of post-transplant lymphocele. *Surg Endosc* 1997; **11**: 245–248.
- 93 Ghasemian S, Guleria A, Khawand N, Light J. Diagnosis and management of the urologic complications of renal transplantation. *Clin Transplant* 1996; **10**: 218–223.
- 94 Rivera M, Marcen R, Burgos J, Arranz M, Rodriguez R, Teruel J *et al.* Treatment of posttransplant lymphocele with povidone iodine sclerosis: long-term follow-up. *Nephron* 1996; **74**: 324–327.
- 95 Reyes-Acevedo R, Bezaury-Rivas P, Alberu J, Bordes-Aznar J, Vazquez-Lamadrid J, Rojas G *et al.* Posttransplant perirenal collections: clinical significance. *Transplant Proc* 1996; **28**: 3312–3313.
- 96 Lange V, Schardey H, Meyer G, Illner W-D, Petersen P, Land W. Laparoscopic deroofting of post-transplant lymphoceles. *Transpl Int* 1994; **7**: 140–143.
- 97 Shaver TR, Swanson SJ III, Fernandez-Bueno C, Kocandrl V. The optimal treatment of lymphoceles following renal transplantation. *Transpl Int* 1993; **6**: 108–110.
- 98 Stephanian E, Matas AJ, Gores P, Sutherland DER, Najarian JS. Retransplantation as a risk factor for lymphocele formation. *Transplantation* 1992; **53**: 676–678.
- 99 Boedker A, Roikjaer O, Rasmussen F, Loekkegaard H. Lymphocele following renal transplantation: a clinical study. *Transplant Proc* 1990; **22**: 154.
- 100 Burgos F, Teruel J, Mayayo T, Lovaco F, Berenguer A, Orte L *et al.* Diagnosis and management of lymphoceles after renal transplantation. *Br J Urol* 1988; **61**: 289–293.
- 101 Greenberg BM, Perloff LJ, Grossman RA, Naji A, Barker CF. Treatment of lymphocele in renal allograft recipients. *Arch Surg* 1985; **120**: 501–504.
- 102 Mihaljevic AL, Heger P, Dezfouli SA, Golriz M, Mehrabi A. Prophylaxis of lymphocele formation after kidney transplantation via peritoneal fenestration: a systematic review. *Transpl Int* 2017; **30**: 543–545.
- 103 Derweesh IH, Ismail HR, Goldfarb DA, Araki M, Zhou L, Modlin C *et al.* Intraoperative placing of drains decreases the incidence of lymphocele and deep vein thrombosis after renal transplantation. *BJU Int* 2008; **101**: 1415–1419.
- 104 Dindo D, Demartines N, Clavien PA. Classification of surgical complications: a new proposal with evaluation in a cohort of 6336 patients and results of a survey. *Ann Surg* 2004; **240**: 205–213.

Supporting information

Additional supporting information can be found online in the Supporting Information section at the end of the article.