



Differences in mastoid and middle-ear cavity opacification in CT between intensive care patients and patients with acute mastoiditis requiring surgical treatment

Simon Bernatz^{a,*}, Scherwin Mahmoudi^a, Simon S. Martin^a, Iris Burck^a, Thomas J. Vogl^a, Jörg Ackermann^b, Timo Stöver^c, Sven Balster^c, Maximilian Gröger^c

^a Department of Diagnostic and Interventional Radiology, University Hospital Frankfurt, Goethe University Frankfurt am Main, Theodor-Stern-Kai 7, 60590 Frankfurt am Main, Germany

^b Department of Molecular Bioinformatics, Institute of Computer Science, Johann Wolfgang Goethe-University, Robert-Mayer-Str. 11-15, 60325 Frankfurt am Main, Germany

^c Department of Otorhinolaryngology, University Hospital Frankfurt, Goethe University Frankfurt am Main, Theodor-Stern-Kai 7, 60590 Frankfurt am Main, Germany

HIGHLIGHTS

- Asymmetric mastoid and middle-ear cavity opacifications are common in acute mastoiditis.
- Visually erosive, hypersclerotic or paramastoidal complicative changes were only rarely seen.
- Quantitative imaging data inherits the potential to augment subjective descriptors of acute mastoiditis.

ARTICLE INFO

Keywords:

Mastoiditis
Intensive care units
Exudates and transudates
Feasibility studies
Cohort studies

ABSTRACT

Purpose: To stratify differences in visual semantic and quantitative imaging features in intensive care patients with nonspecific mastoid effusions versus patients with acute mastoiditis (AM) requiring surgical treatment.

Methods: We included 48 patients (male, 28; female, 20; mean age, 59.5 ± 18.1 years) with mastoid opacification (AM, $n = 24$; control, $n = 24$) who underwent clinically indicated cerebral CT between 12/2007 and 07/2018 in this retrospective study. Semantic features described the extend and asymmetry of mastoid and middle-ear cavity opacification and complications like erosive changes. Minimum, maximum and mean Hounsfield unit (HU) values were obtained as quantitative features. We analyzed the features employing univariate testing.

Results: Compared to intensive care patients, AM patients revealed asymmetric mastoid or middle-ear cavity opacification (likelihood-ratio (LR) < 0.001). Applying a dedicated threshold of the extent of opacification, AM patients reached significance levels of LR = 0.042 and 0.002 for mastoid and middle-ear cavity opacification. AM cases showed higher maximum and mean HU values ($p = 0.009$, $p = 0.024$).

Conclusions: We revealed that the extent and asymmetry of mastoid and middle-ear cavity opacification differs significantly between AM patients and intensive care patients. Multicenter research is needed to expand our cohort and possibly pave the way to build a non-invasive predictive model for AM in the future.

1. Introduction

Though the incidence of acute mastoiditis (AM) has declined in the antibiotic era, antibiotic treatment is no absolute safeguard [1,2]. Early

diagnosis and effective management are critical [3,4]. AM inherits the risk of major complications like subperiosteal abscess or intracranial complications (ICCs) like meningitis, empyema and brain abscess [3,5]. ICCs can lead to rapid clinical deterioration with longer hospitalization

Abbreviations: AM, acute mastoiditis; ICP, Intensive care patients; LR, likelihood-ratio; Pe, Pearson; YE, Years of experience.

* Corresponding author.

E-mail addresses: Simon.Bernatz@kgu.de (S. Bernatz), Scherwin.Mahmoudi@kgu.de (S. Mahmoudi), Simon.Martin@kgu.de (S.S. Martin), Iris.Burck@kgu.de (I. Burck), t.vogl@em.uni-frankfurt.de (T.J. Vogl), j.ackermann@bioinformatik.uni-frankfurt.de (J. Ackermann), Timo.Stoever@kgu.de (T. Stöver), Sven.Balster@kgu.de (S. Balster), Maximilian.Groeger@kgu.de (M. Gröger).

<https://doi.org/10.1016/j.ejro.2021.100365>

Received 1 May 2021; Received in revised form 15 June 2021; Accepted 17 June 2021

Available online 21 June 2021

2352-0477/© 2021 The Author(s).

Published by Elsevier Ltd.

This is an open access article under the CC BY-NC-ND license

(<http://creativecommons.org/licenses/by-nc-nd/4.0/>).

time and impact on mortality [3,6]. The incidence of ICCs is described to range from 5% to 29 % [6]. It is therefore of highest importance to identify patients with potential AM to enable rapid diagnostic workup and treatment [4]. Clinical management of AM patients ranges from antibiotic therapy to surgical intervention [5]. Even with potent antibiotic treatment, potentially fatal AM-related ICCs can occur [2,6,7]. Approximately 50 % of patients may have an atypical clinical presentation which might delay diagnosis [6]. Clinical presentation of patients with or without ICCs can be similar [6]. Consequently, adequate reporting and interpretation of cerebral CT (cCT) examinations are crucial [8]. Opacification of mastoid cells in clinically inapparent patients is commonly encountered in routine cCT imaging [8], especially in intensive care patients (ICP) [9]. Direct referral to ENT specialists based solely on mastoid opacification would be inappropriate [8]. Nevertheless, mastoid or middle-ear effusions might be a source of fever, contribute to delirium or progress to infectious disease [9]. Appropriate workup is therefore critical. Paralleling regional differences in bone maturation, the routes of infectious spread are thought to differ in patients of different ages [10]. Especially in adults, typical clinically visual signs like retroauricular swelling are only rarely seen, which might delay

clinical diagnosis [4,10]. This is especially critical as adults are prone to ICCs [4].

Although delayed diagnosis of AM might affect patient management from antibiotic to surgical therapy and carries the risk of potentially life-threatening complications, there are no guidelines to estimate the risk of AM based on CT image analysis alone [8]. The purpose of our study was to exploratively analyze qualitative and quantitative differences in mastoid and middle-ear cavity opacification in asymptomatic intensive care patients versus patients with AM. We hypothesize that these features may have higher sensitivity compared to classic descriptors of AM such as erosive changes. In the future, these features might aid in the early stratification of patients who are at high risk of suffering from clinically inapparent AM and who could benefit from a dedicated clinical ENT examination.

2. Material and methods

We obtained institutional review board approval of the Ethical Committee at the University Hospital Frankfurt (project-number: 41/19) and written informed consent was waived. The patient population

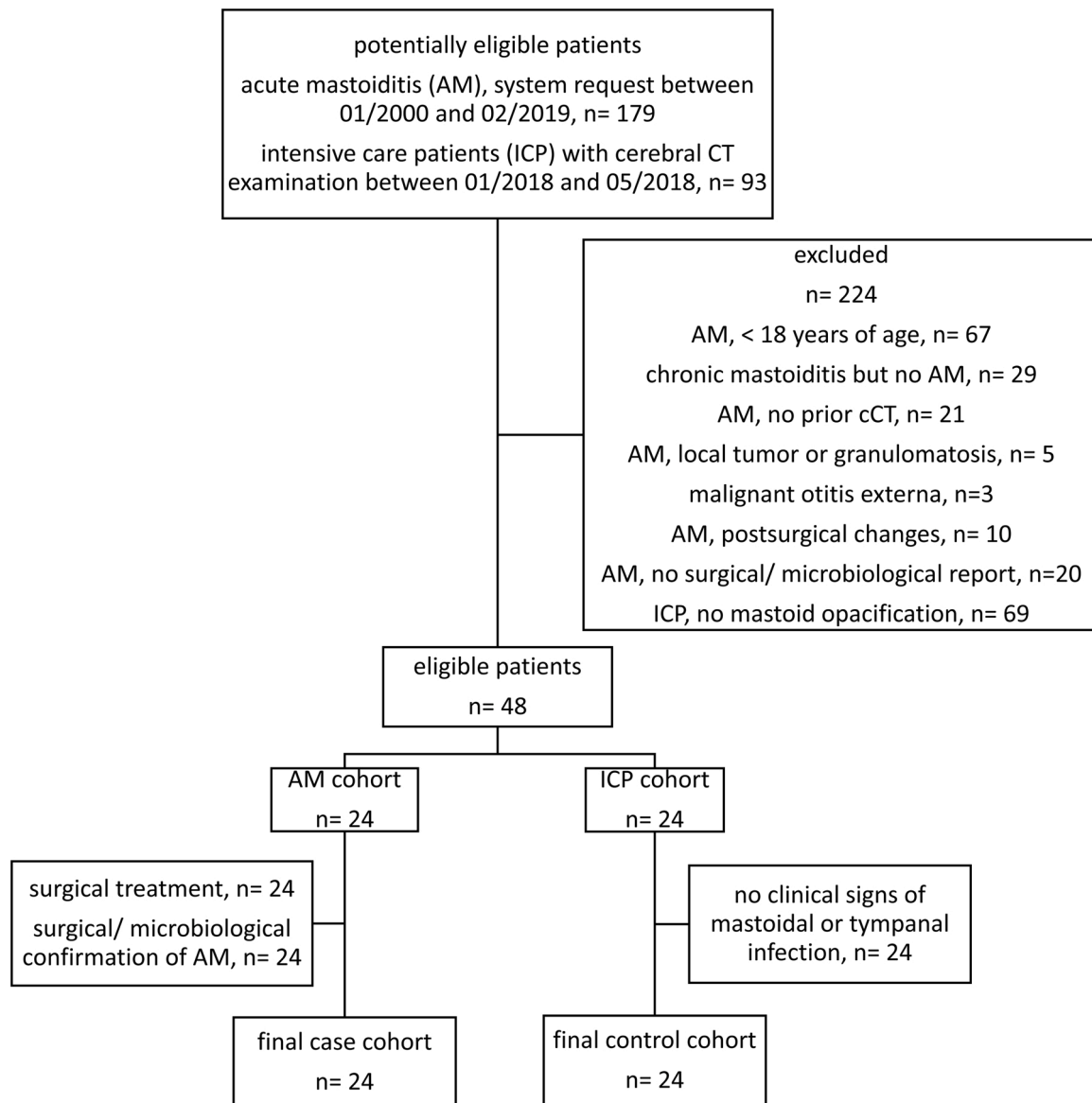


Fig. 1. Flowchart of patient inclusion into the study. In total, 272 patients were evaluated to include a final study cohort of 48 patients (n = 24, case; n = 24, control). AM, acute mastoiditis; cCT, cerebral computed tomography; ICP, intensive care patient.

was not reported previously.

2.1. Study design

In this retrospective study we enrolled 48 patients (male, 28; female, 20; mean age, 59.5 ± 18.1 years) as a case-control study. For the AM cohort (case), we performed a system request based on the criteria: (I) AM and (II) mastoidectomy (01/2000 to 02/2019) and obtained 179 consecutive patients. For the control cohort, we screened 93 consecutive ICPs with clinically indicated cCT between 01/2018 to 07/2018 for mastoid opacification. Case-inclusion criteria were (I) AM, (II) surgical mastoidectomy, (III) microbiological/ surgical/ histopathological confirmation and (IV) preoperative cCT <7d. Control-inclusion criteria were (I) ICP, (II) cCT with mastoid opacification, (III) no signs of AM in the written reports. Exclusion criteria were (I) no cCT prior (<7d) to surgery, (II) insufficient imaging quality, (III) local post-operative changes, (IV) <18 years of age. Quantitative imaging analysis was performed in unenhanced cCTs (n = 38; case, n = 14; control, n = 24). 48 patients met the criteria and were evaluated (examined between 12/2007 and 07/2018). Fig. 1 depicts the flow-chart of patient inclusion. We depict case-patient demographics and characteristics in Table 1 and of the control cohort in supplementary Table 1.

Table 1

Clinical and epidemiological characteristics of included patients with acute mastoiditis.

variable	study cohort
patients*	24 (100)
male	12 (50)
female	12 (50)
mean age at surgical intervention (years)**	54.3 (45.9; 62.8)
median CRP (mg/dL)**	7.6 (6.0; 16.0)
mean WBC (cells/nL)***	13.0 (6.0)
median duration of symptoms (days)**	5.0 (3.6; 13.9)
bacteriological results	
inconclusive	7
Strep. pneumoniae	11
Strep. pyogenes	2
Staph. intermedius	1
H. influenzae	1
Pseudomonas aeruginosa	1
Aspergillus flavus	1
clinical characteristics	
signs of postauricular inflammation	5 [3]
otoscopic evidence of acute or recent OM (bulging, redness or perforation of tympanic membrane)	17 [3]
otorrhoe	
hearing loss	6 [2]
facial paralysis	21 [2]
vestibular affection	4
bezold's abscess	1
swelling of ear canal	1
intracranial complications	5
meningitis	5
meningoencephalitis	2
sinus vein thrombosis	3
intracranial abscess	1
none	14

If not otherwise depicted, the numbers without parenthesis depict absolute numbers.

* Data in round parenthesis are relative values; ** Data in round parenthesis are +/- 95 % confidence interval; *** Data in round parenthesis are standard deviation; Data in square parenthesis are not available values, excluded in the analysis; note: due to mathematical rounding, the summed relative values may differ slightly from 100.

2.2. CT imaging acquisition and examination

Studying a rare disease, our sample size was derived to include all patients of a timespan of 19 years (01/2000–02/2019) who matched the inclusion and exclusion criteria with an equally sized control cohort: examined in domo (n = 35; case, n = 11; control, n = 24) and in external institutions (n = 13; case, n = 13; control, n = 0). In the case cohort, n = 10 examinations were contrast-enhanced only. The acquisition protocols operated the x-ray tubes at 120 kilovoltage and 228.98 ± 86.84 mean mAs. We obtained a mean volume CT dose index of 36.79 ± 13.19 mGy and a mean dose-length product of 536.56 ± 300.28 mGy x cm (for one external cCT CT dose index and dose-length product were not available). The images were reconstructed with a slice thickness of 1.35 ± 1.20 mm, axial plane.

2.3. Reference standard

Ground-truth for AM was defined on histopathological evaluation of surgically obtained material (n = 17) or based on the written surgical report (n = 7), if histopathology was inconclusive. The control cohort was stratified to not show any suspicion of mastoiditis or tympanitis in the written reports.

2.4. Quantitative and qualitative analysis, evaluation approach and statistics

We performed quantitative analysis for unenhanced cCT images. We used institutional workstations applying universal viewer (Centricity Universal Viewer, version 7, GE Healthcare). We manually drew an oval ROI in a representative axial plane of the mastoid at the level of the cochlear promontory (mean ROI-area = 1.41 ± 0.46 cm²). Measurements of Hounsfield Units (HU) and the respective measured area were obtained (minimum, maximum, mean, standard deviation (SD), area). We did not obtain high dimensional radiomic features as we considered the high heterogeneity of CT scanners and variant acquisition protocols/reconstruction algorithms to not be reliably used to extract higher dimensional radiomics [11]. ROI definition was performed by one investigator (SB, 2 years of experience (YE)) and reviewed by a second, independent reader (SM, 1.5 YE). Both were blinded to the written reports and patient characteristics. ROIs with disagreement were re-reviewed by a third blinded reader (IB, 8 YE, board-certified radiologist) to obtain final consensus agreement.

We further evaluated the imaging data following a dedicated scoring system of mastoid and middle-ear cavity opacification, its side-symmetry as well as erosive, hypersclerotic and edematous changes. Mastoid and middle-ear cavity opacification was scored as 0, no; 1, minimal; 2, moderate; 3, subtotal; 4, total. Side-symmetry of opacification was scored as 0, no opacification on both sides, 1, one side only; 2, both sides symmetrically; 3, both sides asymmetrically. Erosive changes were stratified to involve 1, mastoid air cells; 2, scull facing CNS; 3, scull facing scalp. Local signs of hypersclerosis were scored yes or no. To score for potentially clinically visible signs, we scored 1, subcutaneous retroauricular edema; 2 subcutaneous/ paramastoidal abscess. We performed univariate analysis. We analyzed the qualitative (likelihood-ratio (LR), Pearson test (Pe)) and quantitative (two-tailed Student's *t* test) features according to their *p*-value to differ in the AM cohort versus the control cohort. We conducted statistical analyses in Prism 6.0 (GraphPad software) and JMP 14 (SAS). We indicated the significance values: * *p* < 0.05; ** *p* < 0.01; *** *p* < 0.001.

3. Results

3.1. Study population

We analyzed a final study cohort of 48 patients (male, 28; female, 20; age, 59.5 ± 18.1 years) with mastoid opacification (AM, n = 24; control,

n = 24), acquired in clinical routine. AM patients had temporal bone exploration based on the results of the clinical examination as depicted in detail in the patient demographics (case cohort) in Table 1. The case cohort patients were slightly younger (mean age, case vs. control = 54.3 vs. 64.5 years; $p = 0.048$, two-tailed Student's *t* test). The cohorts did not differ regarding the patients' sex (LR = 0.24; $P_e = 0.24$). Details of the control cohort are shown in supplementary Table 1. For the ROI-based quantitative imaging feature analysis we excluded n = 10 patients of the AM-cohort as they did have enhanced cCT acquisition only. We depict a representative image of a case and a control patient in Fig. 2.

3.2. The extent of mastoid opacification was slightly increased in acute mastoiditis patients

The case-control cohorts did not show differences in the extend of mastoid opacification applying a 5 level Likert-scale approach (LR, $P_e = 0.076$, 0.1; Fig. 3A). We dichotomized the extend of mastoid opacification into mild/moderate (≤ 2) and subtotal/total (≥ 3) opacification which showed significant difference in the case-control cohorts (LR, $P_e = 0.042$, 0.046; Fig. 3B). The cohorts did not differ regarding visually apparent adjacent erosive or hypersclerotic changes or the presence of subcutaneous edema/ abscess (LR and $P_e > 0.02$ for all analyses, Suppl. Fig. 1A-C).

3.3. The extend of middle-ear cavity opacification revealed highly significant differences

Applying a 5 level Likert-scale approach to describe the extent of middle-ear cavity opacification we could show significant differences in the case-control cohorts (LR, $P_e = 0.022$, 0.039, Fig. 4A) and a simple yes/no scoring revealed even a higher level of significance (LR, $P_e = 0.013$, 0.016, Fig. 4B). The highest level of significance was reached applying a dichotomization of the extend of middle-ear cavity opacification into no/mild (≤ 1) and moderate/subtotal/total (≥ 2) (LR, $P_e = 0.002$, 0.004, Fig. 4C).

3.4. Side-asymmetry of opacification revealed a high impact

Side-asymmetric opacification of the mastoid and middle-ear cavity differed significantly in the AM and control cohort (LR, $P_e < 0.001$ for all, Fig. 5A,B). The computational quantitative analysis of the ROI-based

approach showed significantly higher HU in the acute mastoiditis cohort (maximum, mean; $p = 0.009$, $p = 0.024$, Fig. 5C-D). The minimum HU did not differ between the cohorts ($p = 0.1$, Suppl. Fig. 1D).

4. Discussion

Our study results revealed that a simple set of visually semantic and/or quantitative imaging features were significantly different in acute mastoiditis patients compared to asymptomatic intensive care patients with mastoid opacification. We found that descriptors of the extent and asymmetry of mastoid and middle-ear cavity opacification as well as maximum HU of ROI measurement showed the highest significance to differ in AM patients. Of note, classical descriptors like erosive changes of the cortical bone, septal coalescence or retroauricular edema were only rarely seen in our cohort. This might reflect the ability of our findings to improve the radiologic stratification of acute mastoiditis especially facing clinically atypical cases.

Middle-ear cavity or mastoid opacification can be an incidental finding in clinical routine cerebral imaging [9,12,13]. Especially critically ill patients from intensive care units are prone to mastoid opacification [9]. Supine position and nasogastric tubes are potential factors promoting the effusions [9]. AM is a rare but potentially life threatening infection of the mastoid [2,3,6]. Early diagnosis and treatment are essential to prevent complicative disease progression which may lead to cerebral abscess or sinus venous thrombosis [4,6]. As AM as well as ICCs can be clinically silent it is of highest importance to prompt suspicion in imaging studies [6,7]. Generally accepted imaging features are erosive changes of mastoid cells, subcutaneous edema or superiostal or intra-/extraaxial abscess formation [7,14,15]. Of note, in our cohort these signs were only rarely seen and may be interpreted to inherit a low sensitivity. Mastoid air cells can be heterogeneously configured and a bone pseudodehiscence might erroneously be reported as AM-associated bone erosion [16]. The reporting of bone erosion is known to be challenging [15–17]. Moreover, the extend of mastoid and paramastoid bone ossification is a dynamic process in an aging person [10]. Mild permeative changes may resemble a variant extent of ossification [10,16]. In adults, retroauricular swelling is only rarely seen which is in line with our data [4]. Though AM is considered a clinical diagnosis up to 50 % of patients may present clinically atypical [4]. Early stages of AM may be adequately addressed with non-invasive antibiotic treatment [2]. Adequate reporting and interpretation of respective features in cCT

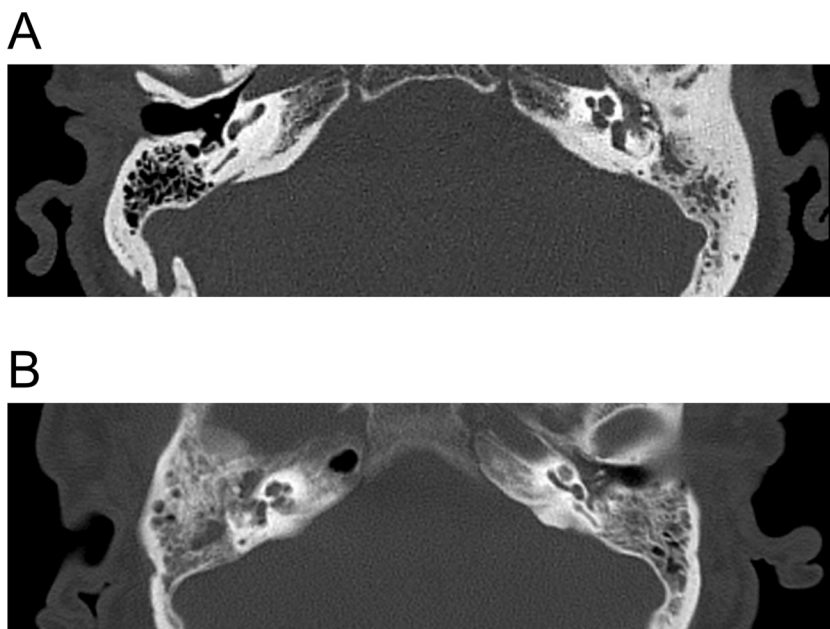


Fig. 2. Representative CT images of a case and a control cohort patient. Axial unenhanced CT images show middle-ear cavity and mastoid region applying a bone kernel. A, image of a 73 years of age male patient suffering from acute mastoiditis. Mastoid and middle-ear cavity opacifications were scored as total (score: 4) and asymmetrical. Increased sclerosis is seen but no erosive or adjacent soft-tissue changes. B, image of an 80 years of age male patient suffering from delayed wake-up after arterio-coronary bypass procedure. The patient suffered from respiratory insufficiency, pneumonia and was resuscitated after cardiac arrest. Mastoid opacification was scored as asymmetrical and subtotal (score: 3), middle-ear cavity opacification was scored as total (score: 4) and symmetrical. There were no sclerotic, erosive or adjacent soft-tissue changes. There were no clinical signs of acute mastoiditis and opacification was interpreted as unspecific. The region of interest measurement of Hounsfield Units revealed a maximum and mean value of 1944 and 917 in A and 830 and 365 in B, respectively.

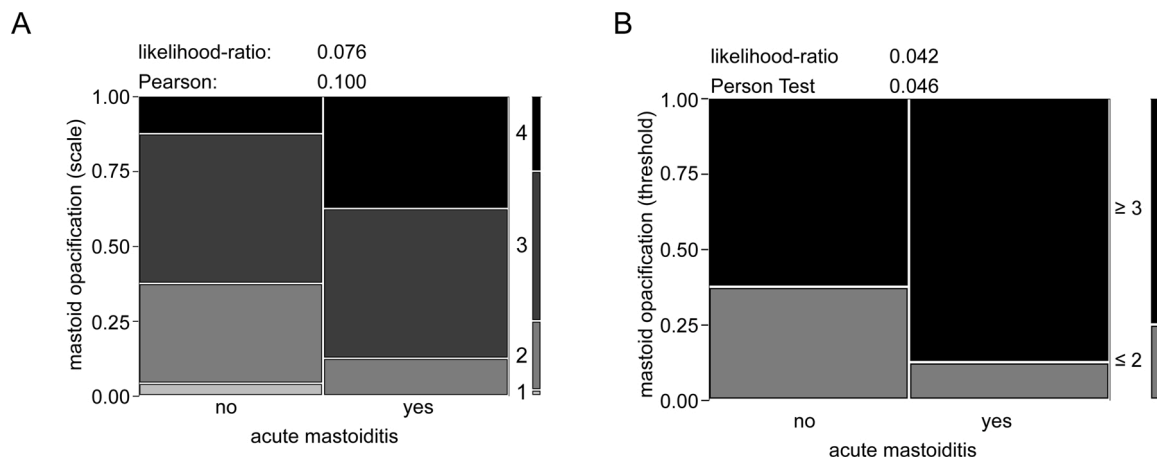


Fig. 3. In acute mastoiditis the extent of mastoid opacification is slightly increased. Contingency tables of a 5 level Likert-scale approach (A) vs. dichotomized approach into mild/moderate (≤ 2) and subtotal/total (≥ 3) opacification (B) are shown. The 5 level scale ranged from 0 to 5. As all included patients did have at least mild (level 1) mastoid opacification, level 0 is not depicted in the illustration.

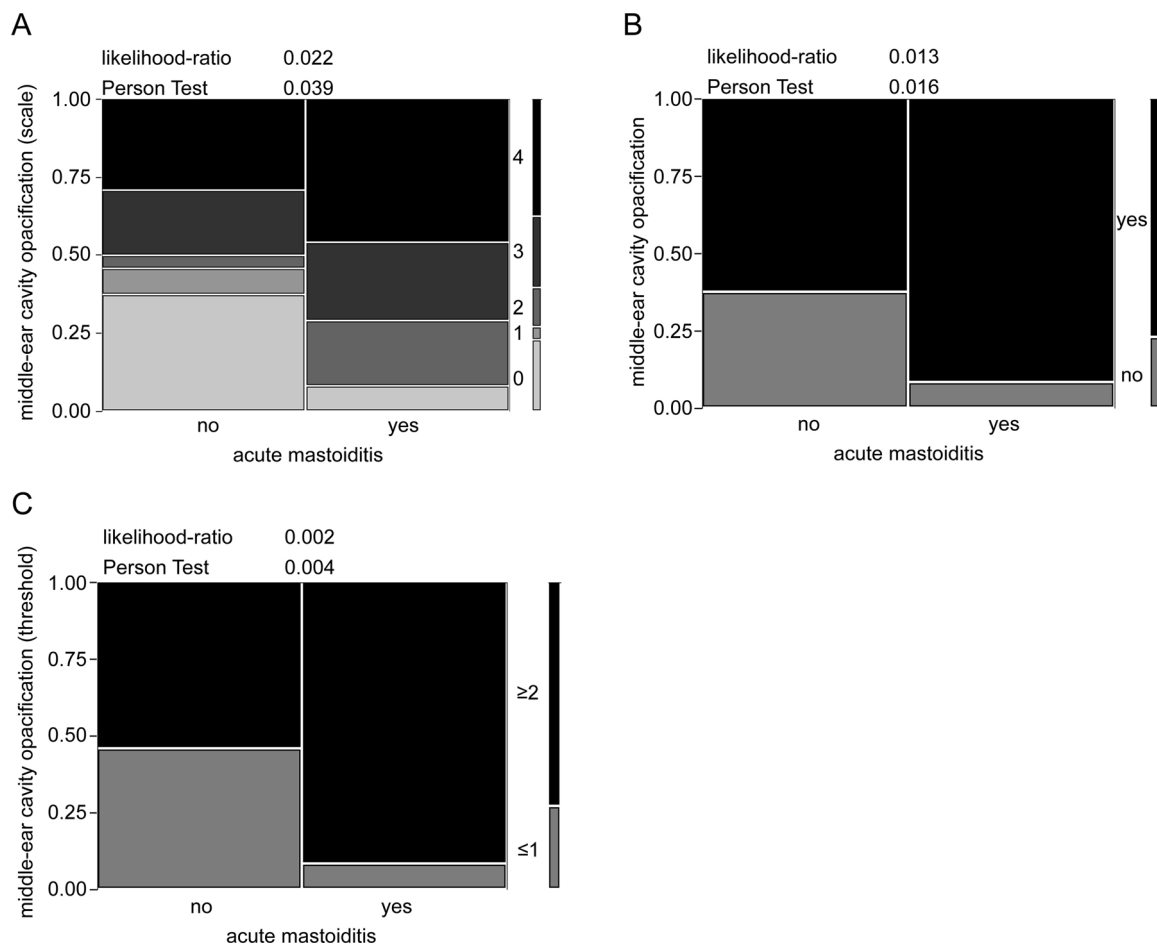


Fig. 4. In acute mastoiditis the extent of middle-ear cavity opacification is significantly increased. Contingency tables of a 5 level Likert-scale approach (A), nominal yes/no approach (B) and dichotomized approach into no/mild vs. moderate/subtotal/total (C) are shown.

examinations is therefore a critical step to adequately manage AM and to prevent complicative events [6].

Our study suffers from limitations that warrant discussion. We analyzed a monocentric cohort of 24 AM patients which might seem rather small. Nevertheless, the size of our cohort is in line with or exceeds prior studies [4,5,16]. Vassbotn et al. enrolled 57 patients in a 20 years retrospective study but only approximately 5 patients were older

than 10 years of age [5]. Saat et al. analyzed 32 patients of whom 23 were adults in their retrospective comparison of MRI versus CT examination to detect coalescent AM [16]. In a 19-year retrospective study from Palma et al. in total 62 adult patients were enrolled but only 18 were treated surgically [4]. We did include externally acquired CT examinations including variant vendors and acquisition protocols. Though this limitation might add data noise, it should not impact visually

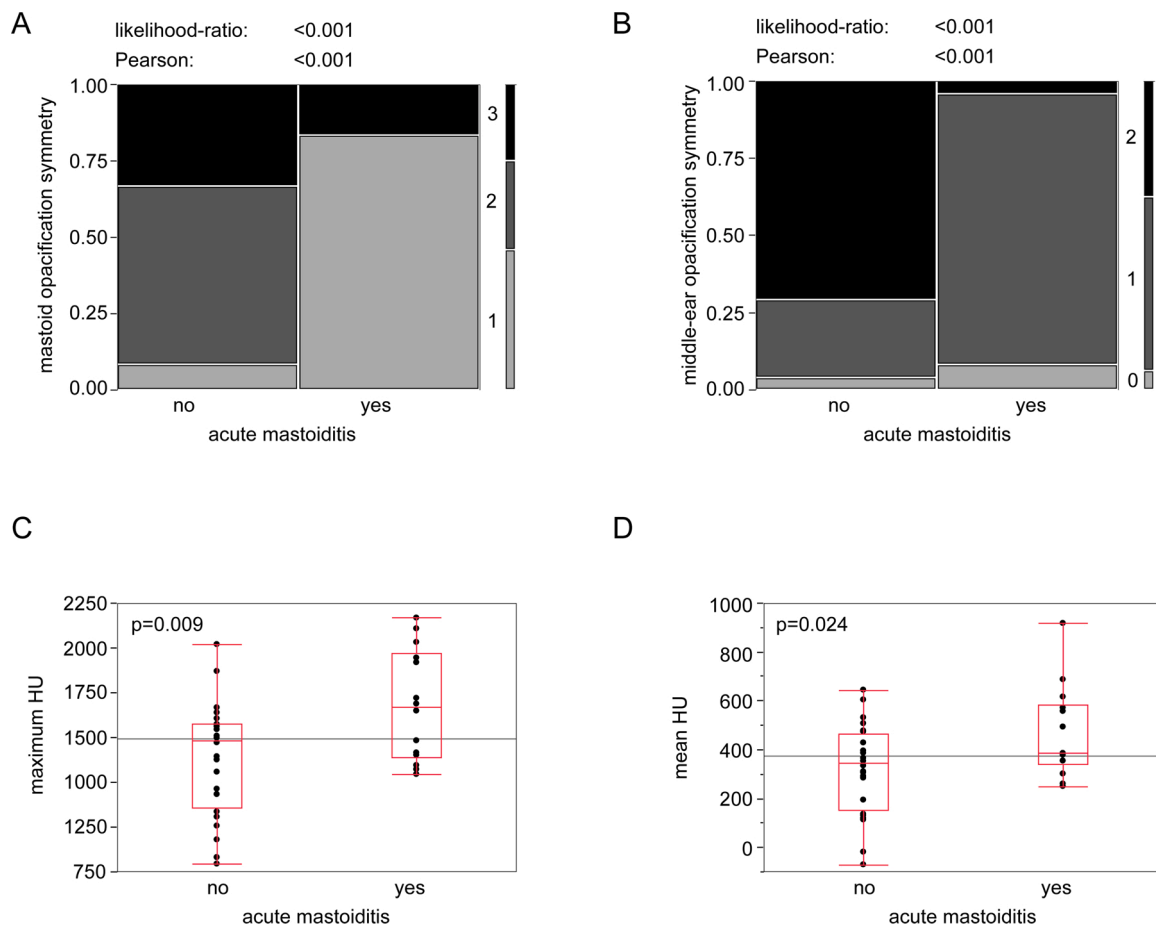


Fig. 5. Impact of opacification side-asymmetry and quantitative measurements. Contingency tables depict the side-symmetry of opacification for the mastoid (A) and middle-ear cavity (B) as 0, no opacification on both sides, 1, one side only; 2, both sides symmetrically; 3, both sides asymmetrically. Asymmetric opacification of the middle-ear cavity was not seen. In C and D box-whisker blots for the quantitative measurements of maximum (C) and mean (D) HU are shown. Statistical analysis in C and D was performed applying two-tailed Student's *t* test.

semantic feature description nor measurement of our ROI-based quantitative feature set. Our subgroup analysis with quantitative feature measurement was small, as we did only include unenhanced cCT examinations for this subanalysis. We did only include surgically treated patients to achieve a valid ground-truth of surgical or pathological report. We cannot rule out that non-invasively treated patients may present with variant cCT features and that our cohort might reflect case selection bias in this retrospective monocentric series. Our control cohort constituted of retrospectively enrolled consecutive patients of intensive care units. Thus, we are not accounting for additional potential causes of mastoid effusions, which might be more prone to being unilateral, like eustachian tube dysfunction or nasopharyngeal adenoid or mass. We cannot rule out selection bias. Nevertheless, these patients might be more prone to local infectious disease and benefit from ENT-examination as might be proposed following our analyses. The medical reports of the control cohort patients did not report AM or middle-ear infectious disease but patients were not specifically examined by an ENT specialist. Contrary to prior studies [15], in our cohort mastoid septa resorption, cortical bone erosion or typical clinical signs like retroauricular swelling or edema had a very low incidence. This might be the result of a selection bias that predominantly clinically atypical cases were subjected to cCT examinations which emphasizes the importance of adequate cCT reporting.

5. Conclusions

In conclusion, the results of our explorative study revealed that the

extent and asymmetry of mastoid and middle-ear cavity opacifications are significantly different in acute mastoiditis patients compared to intensive care patients. Furthermore, our results indicate that classically accepted signs like erosive changes may inherit a critically low sensitivity. Further research is necessary to validate our findings in a bigger cohort to potentially enable the formulation of a guideline to identify patients who might benefit from dedicated ENT examination.

Ethical approval details

We obtained institutional review board approval of the Ethical Committee at the University Hospital Frankfurt (project-number: 41/19) and written informed consent was waived for this retrospective study. The patient population was not reported previously.

Funding sources

This research did not receive any specific grant from funding agencies in the public, commercial, or not-for-profit sectors.

Declaration of Competing Interest

The authors declare that they have no known competing financial interests or personal relationships that could have appeared to influence the work reported in this paper.

Acknowledgements

None

Appendix A. Supplementary data

Supplementary material related to this article can be found, in the online version, at doi:<https://doi.org/10.1016/j.ejro.2021.100365>.

References

- [1] H.P. House, Otitis media. A comparative study of the results obtained in therapy before and after the introduction of the sulfonamide compounds, *Arch. Otolaryngol.* 43 (1946) 371–378, <https://doi.org/10.1001/archotol.1946.00680050387005>.
- [2] M. Luntz, A. Brodsky, S. Nusem, J. Kronenberg, G. Keren, L. Migirov, D. Cohen, S. Zohar, A. Shapira, D. Ophir, G. Fishman, G. Rosen, V. Kisilevsky, I. Magamse, S. Zaaroura, H.Z. Joachims, D. Goldenberg, Acute mastoiditis - the antibiotic era: a multicenter study, *Int. J. Pediatr. Otorhinolaryngol.* 57 (2001) 1–9, [https://doi.org/10.1016/S0165-5876\(00\)00425-0](https://doi.org/10.1016/S0165-5876(00)00425-0).
- [3] D. Gower, W.F. MCGuirt, Intracranial complications of acute and chronic infectious ear disease: a problem still with us, *Laryngoscope* 93 (1983) 1028–1033, <https://doi.org/10.1288/00005537-198308000-00010>.
- [4] S. Palma, R. Bovo, A. Benatti, C. Aimoni, M. Rosignoli, M. Libanore, A. Martini, Mastoiditis in adults: a 19-year retrospective study, *Eur. Arch. Oto-Rhino-Laryngol.* 271 (2014) 925–931, <https://doi.org/10.1007/s00405-013-2454-8>.
- [5] F.S. Vassbotn, O.G. Klausen, O. Lind, P. Moller, Acute mastoiditis in a Norwegian population: a 20 year retrospective study, *Int. J. Pediatr. Otorhinolaryngol.* 62 (2002) 237–242, [https://doi.org/10.1016/S0165-5876\(01\)00626-7](https://doi.org/10.1016/S0165-5876(01)00626-7).
- [6] M. Luntz, K. Bartal, A. Brodsky, R. Shihada, Acute mastoiditis: the role of imaging for identifying intracranial complications, *Laryngoscope.* 122 (2012) 2813–2817, <https://doi.org/10.1002/lary.22193>.
- [7] P.S. Mallur, S. Harirchian, A.K. Lalwani, Preoperative and postoperative intracranial complications of acute mastoiditis, *Ann. Otol. Rhinol. Laryngol.* 118 (2009) 118–123, <https://doi.org/10.1177/000348940911800207>.
- [8] S.L. Wilkinson, R.S. Sahota, J.D. Constable, F. Harper, O. Judd, Does incidental mastoid opacification on computerized tomography necessitate referral to ENT? *Laryngoscope* 127 (2017) 2860–2865, <https://doi.org/10.1002/lary.26594>.
- [9] P. Huyett, Y. Raz, B.E. Hirsch, A.A. McCall, Radiographic mastoid and middle ear effusions in intensive care unit subjects, *Respir. Care* 62 (2017) 350–356, <https://doi.org/10.4187/respcare.05172>.
- [10] K. Takahashi, Y. Morita, S. Ohshima, S. Izumi, Y. Kubota, A. Horii, Bone density development of the temporal bone assessed by computed tomography, *Otol. Neurotol.* 38 (2017) 1445–1449, <https://doi.org/10.1097/MAO.0000000000001566>.
- [11] R. Berenguer, M.R. Pastor-juan, J. Canales-vázquez, Radiomics of CT features may be nonreproducible and redundant : influence of CT acquisition parameters, *Radiology.* 288 (2018) 407–415, <https://doi.org/10.1148/radiol.2018172361>.
- [12] K. Blomgren, S. Robinson, T. Lönnqvist, H. Saxén, A. Pitkäranta, Clinical significance of incidental magnetic resonance image abnormalities in mastoid cavity and middle ear in children, *Int. J. Pediatr. Otorhinolaryngol.* 67 (2003) 757–760, [https://doi.org/10.1016/S0165-5876\(03\)00094-6](https://doi.org/10.1016/S0165-5876(03)00094-6).
- [13] D. Lee, B. Jun, J.-O. Park, S.-W. Yeo, Magnetic resonance imaging of the mastoid cavity and middle ear: prevalence and clinical significance of incidental abnormal findings in a nonotolaryngologic adult and pediatric population, *J. Otolaryngol.* 35 (2006) 13–18.
- [14] D.P. Minks, M. Porte, N. Jenkins, Acute mastoiditis - the role of radiology, *Clin. Radiol.* 68 (2013) 397–405, <https://doi.org/10.1016/j.crad.2012.07.019>.
- [15] P.J. Antonelli, J.A. Garside, A.A. Mancuso, S.T. Strickler, P.S. Kubilis, Computed tomography and the diagnosis of coalescent mastoiditis, *J. Otolaryngol. Head Neck Surg.* 120 (1999) 350–354, [https://doi.org/10.1016/S0194-5998\(99\)70274-3](https://doi.org/10.1016/S0194-5998(99)70274-3).
- [16] R. Saat, G. Kurdo, A. Laulajainen-Hongisto, A. Markkola, J. Jero, Detection of coalescent acute mastoiditis on MRI in comparison with CT, *Clin. Neuroradiol.* (2020), <https://doi.org/10.1007/s00062-020-00931-0>.
- [17] J. Stähelin-Massik, M. Podvinec, J. Jakscha, O.N. Rüst, J. Greisser, M. Moschopoulos, H.E. Gnehm, Mastoiditis in children: a prospective, observational study comparing clinical presentation, microbiology, computed tomography, surgical findings and histology, *Eur. J. Pediatr.* 167 (2008) 541–548, <https://doi.org/10.1007/s00431-007-0549-1>.