



# Complete Pathological Response After Neoadjuvant Short-Course Immunotherapy with Ipilimumab and Nivolumab in Locally Advanced MSI-H/dMMR Rectal Cancer

JÖRG TROJAN<sup>1</sup>, SEBASTIAN STINTZING<sup>2</sup>, OLIVER HAASE<sup>3</sup>, CHRISTINE KOCH<sup>4</sup>, PAUL ZIEGLER<sup>5</sup>, MELANIE DEMES<sup>6</sup>, IVAN JELAS<sup>7</sup>

<sup>1</sup>Department of Medicine I, Goethe-University, Frankfurt, Germany; <sup>2</sup>University Cancer Center, Goethe-University, Frankfurt, Germany;

<sup>3</sup>Dr. Senckenberg Institute of Pathology, Goethe-University, Frankfurt, Germany; <sup>4</sup>Department of Hematology, Oncology, and Cancer

Immunology, Campus Charité Mitte, Charité - Universitätsmedizin Berlin, Berlin, Germany; <sup>5</sup>Department of Surgery, Charité -

Universitätsmedizin, Berlin, Germany

Disclosures of potential conflicts of interest may be found at the end of this article.

## ABSTRACT

**Background.** Patients with colorectal carcinoma and high-grade microsatellite instability (MSI-H) or deficiency in mismatch repair (dMMR) exceptionally respond to immune checkpoint inhibitors (ICIs). ICIs are more active in treatment-naïve patients than in patients with refractory MSI-H/dMMR metastatic colorectal cancer and even more active in patients with locally advanced tumors.

**Material and Methods.** A 33-year-old male patient with Lynch syndrome was diagnosed with a locally advanced rectal cancer and refused standard neoadjuvant chemoradiation because of the potential harm of sexual dysfunction. MMR and microsatellite instability status were analyzed by

immunohistochemistry and fragment length polymerase chain reaction followed by capillary electrophoresis.

**Results.** After MSI-H/dMMR was confirmed, the patient was treated with ICIs (1 mg/kg ipilimumab at day 1 and 3 mg/kg nivolumab at day 1 and 15). A complete clinical response was documented at day 21 after start of treatment. The patient underwent a total mesorectal excision at day 30. In the extirpated tissue, a complete pathological response was confirmed.

**Conclusion.** In MSI-H/dMMR locally advanced rectal cancer short-course ICI treatment is highly effective and may be discussed in patients with dMMR locally advanced rectal cancer. *The Oncologist* 2021;26:1–5

## KEY POINTS

- Immune checkpoint inhibitors are more active in treatment-naïve patients than in patients with refractory high-grade microsatellite instability (MSI-H)/deficiency in mismatch repair (dMMR) colorectal cancer.
- Standard neoadjuvant chemoradiation is less effective in MSI-H/dMMR rectal cancer patients than in patients with proficient mismatch repair.
- A young patient with Lynch syndrome and MSI-H/dMMR locally advanced rectal cancer refused chemoradiation in order to preserve his fertility.
- After neoadjuvant treatment with one dose of ipilimumab and two doses of nivolumab a complete clinical and pathological response was documented.
- Clinical trials are needed to first establish neoadjuvant treatment with immune checkpoint inhibitors in patients with locally advanced MSI-H/dMMR rectal cancer and thereafter to evaluate organ-preservation strategies.

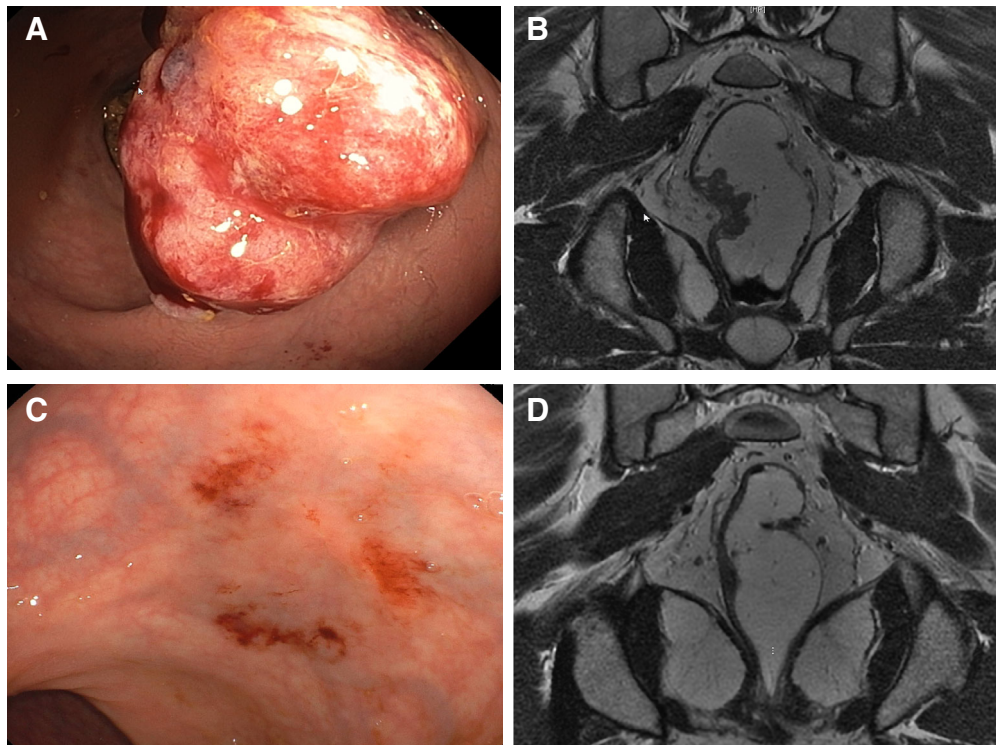
## INTRODUCTION

Colorectal cancer (CRC) with deficiency in mismatch repair (dMMR) results in a strong mutator phenotype known as high microsatellite instability (MSI-H) and high mutational burden [1]. The MSI-H/dMMR phenotype is present in approximately 15% of all CRCs and is a hallmark of Lynch

syndrome, but it is also distinctive in sporadic CRCs and in several other tumor types [1, 2]. The vast majority of sporadic MSI-H/dMMR CRCs are caused by methylation of the *MLH1* gene promoter, whereas more than two-thirds of patients with CRC and Lynch syndrome are associated with

Correspondence: Jorg Trojan, M.D., Department of Medicine, Goethe-University, Frankfurt, Germany. Telephone: 0049-69-6301-7860; e-mail: trojan@em.uni-frankfurt.de Received February 5, 2021; accepted for publication August 13, 2021. <http://dx.doi.org/10.1002/onco.13955>

This is an open access article under the terms of the Creative Commons Attribution-NonCommercial-NoDerivs License, which permits use and distribution in any medium, provided the original work is properly cited, the use is non-commercial and no modifications or adaptations are made.



**Figure 1.** Complete clinical response in a patient with locally advanced high-grade microsatellite instability/deficiency in mismatch repair rectal adenocarcinoma after short-course ipilimumab and nivolumab. **(A):** Endoscopic imaging, showing a bleeding rectal cancer 9 cm from the anal verge in a 33-year-old male patient with Lynch syndrome. **(B):** Magnetic resonance imaging (MRI) staging demonstrated a locally advanced rectal cancer (cT3 cN2 cM0). **(C):** Endoscopy and **(D)** MRI demonstrating a complete clinical response after short-course treatment with ipilimumab and nivolumab.

germline mutations in *MLH1* or *MSH2* [3]. The incidence of MSI-H/dMMR is 20% in stage II CRC, 11% in stage III, and 3%–4% in metastatic CRC (mCRC) [4].

Because MSI-H/dMMR is an actionable predictive biomarker for treatment with immune checkpoint inhibitors (ICIs), the detection by fragment length polymerase chain reaction (PCR) analysis and/or immunohistochemistry is recommended for many advanced tumor types [5]. Just recently, first-line therapy with the anti-programmed death receptor 1 (PD-1) antibody pembrolizumab was approved for first-line therapy in metastatic MSI-H/dMMR CRC. In the pivotal Keynote-177 study, a superior response rate of 43.8% in MSI-H/dMMR mCRC was demonstrated with first-line pembrolizumab compared with 33.1% with standard chemotherapy [6]. Currently, the standard treatment for locally advanced rectal cancer irrespective of molecular subtypes is total neoadjuvant treatment (TNT) consisting of (chemo)radiation followed by chemotherapy or vice versa before delayed surgery [7]. Currently, several randomized TNT-based trials are ongoing to establish a potentially nonoperative management of patients with locally advanced rectal cancer (e.g., the Organ Preservation in Rectal Adenocarcinoma trial) [8].

#### PATIENT STORY

We report a 33-year-old male patient with a family history of cancer who was referred for colonoscopy because of intermittent rectal bleeding. His grandmother was diagnosed with

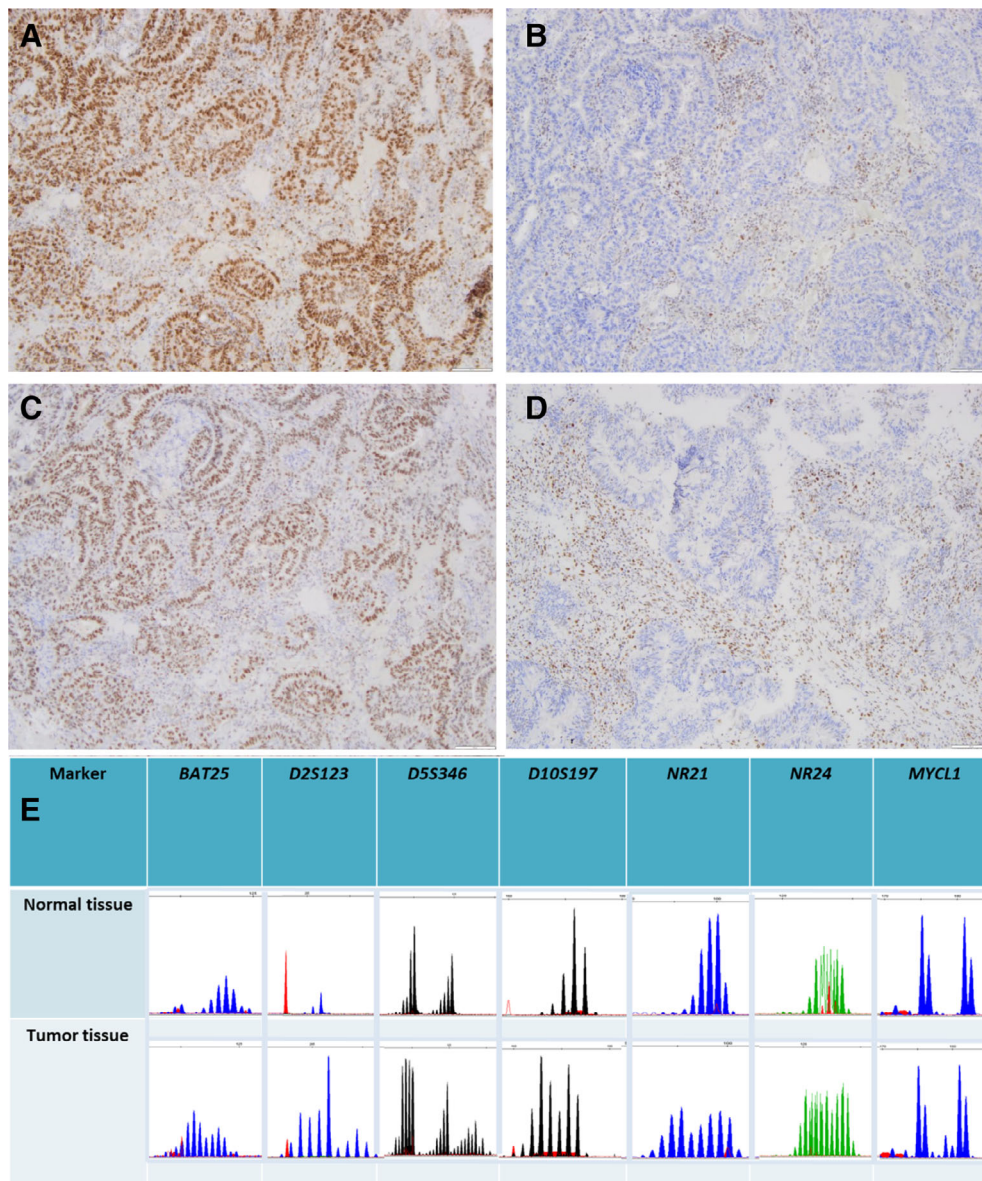
CRC, his aunt with urothelial cancer, and his father with prostate cancer. Endoscopy established the diagnosis of a bleeding rectal cancer 7 cm from the anocutaneous line (Fig. 1A). Histopathology confirmed the diagnosis of a moderately differentiated adenocarcinoma with prominent inflammatory cell infiltrates. Magnetic resonance imaging (MRI) of the pelvis and abdomen showed a locally advanced rectal cancer invading the serosa with enlarged regional lymph nodes and extramural vascular invasion (EMVI) but without distant metastases (Fig. 1B). Therefore, the tumor was classified as Union for International Cancer Control stage III (cT3 cN2 presence of extramural venous invasion (cEMVI+) cM0) and neoadjuvant chemoradiation was recommended. For a second-opinion the patient was referred to our institutions.

The case was presented and discussed in a multidisciplinary tumor board and total neoadjuvant treatment according to the lately published RAPIDO trial was offered to the patient [9]. Because of the patient's young age, dMMR testing was recommended.

#### MOLECULAR TUMOR BOARD

##### Immunohistochemistry and Genotyping

After written informed consent the tumor biopsies were further analyzed by immunohistochemical staining of the MMR proteins MLH1 (clone BS29), MSH2 (clone G219–1129), MSH6 (clone SP93), and PMS2 (clone EP51) using the OMNIS (Agilent) automated advanced staining technique.



**Figure 2.** Immunohistochemistry and microsatellite polymerase chain reaction (PCR) analysis. **(A–D):** Immunohistochemistry of the proteins MLH1 (A), MSH2 (B), PMS2 (C), and MSH6 (D). MLH1 and PMS2 are expressed, whereas MSH2 and MSH6 are lacking. **(E):** Multiplex PCR-microsatellite analysis (*BAT25*, *D2S123*, *D5S346*, *D10S197*, *NR21*, *NR24* and *MYCL1*) showed instability in all markers (high-grade microsatellite instability [MSI-H]). Accordingly, the tumor was classified as MSI-H/ deficiency in mismatch repair rectal cancer.

Slides were assessed by an experienced pathologist. A loss of expression of MSH2 and MSH6 was seen, whereas MLH1 and PMS2 were regularly expressed (Fig. 2A–D). Subsequently, paraffin-embedded tissue sections were macrodissected from tumor and individual normal tissue for DNA-based fragment analysis. Microsatellite analysis was conducted using a fluorescent multiplex PCR-based method followed by capillary electrophoresis (Genetic Analyzer, ABI 3130xl). According to recommendations of distinct guidelines seven microsatellite loci (*BAT25*, *D2S123*, *D5S346*, *D10S197*, *NR21*, *NR24* and *MYCL1*) were used for microsatellite instability testing. Seven out of seven tested microsatellite markers showed instability (MSI-H) fitting to the immunohistochemical results of dMMR. Therefore, the tumor was classified as locally advanced MSI-H/dMMR rectal cancer.

After genetic counseling genomic DNA was extracted from whole blood and the entire coding exons and intron-exon junctions of *MSH2* and *MSH6* were amplified by PCR and directly sequenced. Large deletions and duplications of *MSH2* and *MSH6* were ruled out by multiplex ligation-dependent probe amplification (MRC Holland). The suspected diagnosis of Lynch syndrome was molecularly confirmed by detection of a heterozygous, pathogenic *MSH2* germline mutation [NM\_000251.2(*MSH2*):c.187del (p.Gly62\_Val63insTer)].

#### Potential Strategies to Target the Pathway and Implications for Clinical Practice

Major bowel, urogenital, and sexual dysfunctions are experienced in a large proportion of surviving patients after

sphincter-preserving surgery (SPS). Disturbance of bowel function, also known as low anterior resection syndrome, has been reported in 30%–80% of patients and commonly occurs within one month after SPS [10]. Furthermore, ejaculatory problems and impotence in men and vaginal dryness and dyspareunia in women, occurs in more than 50% of these patients. Specifically radiotherapy seems to affect the development of sexual dysfunction without affecting urinary function [11].

In the adjuvant setting, patients with high-risk stage II CRC do not benefit from 5-fluorouracil-based adjuvant chemotherapy [12]. In the metastatic setting, MSI-H/dMMR CRCs are less responsive to conventional chemotherapy, as shown in the pivotal Keynote-177 study [6]. Moreover, first-line combination treatment with the ICIs ipilimumab (anti-CTLA4 antibody) and nivolumab (anti-PD-1 antibody) in the CheckMate-142 study resulted in an even higher response rate of 69% compared with 43.8% with first-line monotherapy with pembrolizumab [6, 13]. These data therefore support that ICIs are more active in treatment-naïve than in patients with refractory MSI-H/dMMR mCRC [6, 13–15]. Moreover, the combination of short-course ipilimumab (1 mg/kg intravenous [IV] day 1) and nivolumab (3 mg/kg IV day 1 and 15) before resection is highly effective in locally advanced colon cancer. In the recently published NICHE trial, a complete pathological response (pCR) of 60% was demonstrated in 20 MSI-H/dMMR patients [16]. For locally advanced MSI-H/dMMR rectal cancer, response data with chemoradiation are more conflicting. Based on the US National Cancer Database registry a MSI-H/dMMR phenotype is a negative predictive marker for pCR after standard chemoradiation (5.9% vs. 8.9% in microsatellite stable [MSS]/proficient in mismatch repair [pMMR] tumors) [17]. In contrast, the response rate with upfront chemoradiation seems not to be influenced by MSI-H/dMMR phenotype in a retrospective cohort study from Memorial Sloan Kettering Cancer Center (pCR 13% vs. 17% in MSS/pMMR tumors) [18]. Of note, upfront chemotherapy in this series resulted in disease progression in 6 out of 21 (29%) patients with MSI-H/dMMR rectal cancer. With a lack of prospective randomized data, neoadjuvant chemoradiation followed by resection still remains the standard treatment in stage II and III MSI-H/dMMR rectal cancer, although TNT consisting of short-course radiotherapy followed by chemotherapy before delayed surgery is a new option [8, 9].

To date, only data from five further patients with MSI-H/dMMR rectal cancer treated with ICIs in the neoadjuvant setting have been published [19, 20]. Two patients with Lynch syndrome received six cycles of nivolumab (3 mg/kg IV every 2 weeks), resulting in a complete response [19]. In the second case series, three patients from the U.S. were reported [20]. One of those patients with relevant comorbidities was not a candidate for neoadjuvant chemoradiation and was therefore treated with pembrolizumab (200 mg IV every 3 weeks). After 11 cycles, a complete clinical response was documented. Another patient, who was not responding to neoadjuvant chemoradiation, was thereafter treated with three cycles of ipilimumab (1 mg/kg IV) and nivolumab (3 mg/kg IV) every 3 weeks, resulting in a complete clinical response. A patient with Lynch syndrome, who was likely stage IV at the time of

first diagnosis, was treated with seven cycles of FOLFOX with concurrent pembrolizumab and also achieved a pCR [19]. The discussion in the multidisciplinary molecular tumor board was guided by the exceptional high pCR rate in the NICHE trial [11] and the above mentioned five patients with MSI-H/dMMR rectal cancer [19, 20]. We therefore suggested a neoadjuvant treatment according to the NICHE trial.

#### PATIENT UPDATE

After informed consent and written off-label approval of the health care provider, the patient was treated according to the NICHE trial with ipilimumab (1 mg/kg IV day 1) and nivolumab (3 mg/kg IV day 1 and 15) [9]. No significant adverse events were observed, and at day 21 after the start of treatment, endoscopy (Fig. 1C) with extensive biopsies and MRI (Fig. 1D) demonstrated a complete clinical response with minimal residual thickening of the rectal wall and small perirectal lymph nodes. The patient underwent robotic-assisted total mesorectal excision at day 30. Intraoperatively, the tissue did not show any of the typical changes after neoadjuvant chemoradiation and the operating conditions were very good. Histopathologically, a complete response was confirmed and the final tumor stage was pT0 pN0 (0/16). He was discharged 7 days later without any sexual or urogenital dysfunction. Postoperative wound healing was unremarkable and no acute toxicity related to the neoadjuvant ICI treatment was reported.

The presented patient indicates that short-course ICI treatment is highly effective and might carry a much lower harm of postoperative dysfunctions than standard TNT. Furthermore, in the presented patients as well as the other ICI-treated patients with published data [19, 20], there is a striking concordance between clinical and pathological complete response. This challenges the need for rectal surgery for selected patients with locally advanced MSI-H/dMMR rectal cancer achieving a complete clinical response after ICI treatment, particularly for those patients with lower rectal cancer and sphincter involvement. Nevertheless, further evidence by clinical trials is needed to first establish neoadjuvant treatment with ICIs in patients with locally advanced MSI-H/dMMR rectal cancer and thereafter to evaluate organ-preservation strategies. Currently, a National Cancer Institute sponsored phase II study is assessing pCR as primary endpoint in such patients following treatment with neoadjuvant nivolumab plus ipilimumab combined with short-course radiation (ClinicalTrials.gov Identifier: NCT04751370).

#### ACKNOWLEDGMENTS

This study did not receive any specific grant from funding agencies in the public, commercial, or not-for-profit sectors.

Open access funding enabled and organized by Projekt DEAL.

#### AUTHOR CONTRIBUTIONS

**Conception/Design:** Jörg Trojan, Sebastian Stintzing, Ivan Jelas

**Provision of study material or patients:** Jörg Trojan, Sebastian Stintzing, Oliver Haase, Christine Koch, Paul Ziegler, Melanie Demes, Ivan Jelas

**Collection and/or assembly of data:** Jörg Trojan, Sebastian Stintzing, Oliver Haase, Christine Koch, Paul Ziegler, Melanie Demes, Ivan Jelas  
**Data analysis and interpretation:** Jörg Trojan, Sebastian Stintzing, Oliver Haase, Christine Koch, Paul Ziegler, Melanie Demes, Ivan Jelas  
**Manuscript writing:** Jörg Trojan, Sebastian Stintzing, Oliver Haase, Christine Koch, Paul Ziegler, Melanie Demes, Ivan Jelas  
**Final approval of manuscript:** Jörg Trojan, Sebastian Stintzing, Oliver Haase, Christine Koch, Paul Ziegler, Melanie Demes, Ivan Jelas

## DISCLOSURES

**Jörg Trojan:** Amgen, AstraZeneca, Bayer Healthcare, Bristol Myers-Squibb, Eisai, Ipsen, Merck Serono, Merck Sharp & Dome, Lilly Imclone, Roche Servier (C/A), Ipsen, Roche (RF); **Sebastian**

**Stintzing:** AMGEN, Bayer, Bristol-Myers Squibb, ESAI, Eli Lilly & Co, Merck KGaA, Merck Sharpe & Dohme, Pierre-Fabre, Roche, Sanofi, Servier, Taiho, Takeda (C/A), Merck KGaA, Pierre-Fabre, Servier, Roche (H), Amgen, Bayer, Bristol-Myers Squibb, ESAI, Eli Lilly & Co, Merck KGaA, Merck Sharpe & Dohme, Pierre-Fabre, Roche, Sanofi, Servier, Taiho, Takeda (RF); **Christine Koch:** Merck Sharp & Dohme, Eisai, Ipsen, Novartis, Roche, Servier (C/A), Ipsen, Medac (Other-travel grants); **Melanie Demes:** Amgen, AstraZeneca, Bayer, Biocartis, Diaceutics, Roche, Sophia Genetics (C/A). **Ivan Jelas:** Bristol-Myers Squibb, Merck Serono, Roche; **Paul Ziegler:** Amgen. The other authors indicated no financial relationships.

(C/A) Consulting/advisory relationship; (RF) Research funding; (E) Employment; (ET) Expert testimony; (H) Honoraria received; (OI) Ownership interests; (IP) Intellectual property rights/inventor/patent holder; (SAB) Scientific advisory board

## REFERENCES

1. Sinicrope FA. Lynch syndrome-associated colorectal cancer. *N Engl J Med* 2018;379:764–773.
2. Hause RJ, Pritchard CC, Shendure J et al. Classification and characterization of microsatellite instability across 18 cancer types. *Nat Med* 2016;22:1342–1350.
3. Weisenberger DJ, Siegmund KD, Campan M et al. CpG island methylator phenotype underlies sporadic microsatellite instability and is tightly associated with BRAF mutation in colorectal cancer. *Nat Genet* 2006;38:787–793.
4. Koopman M, Kortman GA, Mekenkamp L et al. Deficient mismatch repair system in patients with sporadic advanced colorectal cancer. *Br J Cancer* 2009;100:266–273.
5. Luchini C, Bibeau F, Ligtenberg MJL et al. ESMO recommendations on microsatellite instability testing for immunotherapy in cancer, and its relationship with PD-1/PD-L1 expression and tumour mutational burden: A systematic review-based approach. *Ann Oncol* 2019;30:1232–1243.
6. André T, Shiu KK, Kim TW et al. Pembrolizumab in microsatellite-Instability-high advanced colorectal cancer. *N Engl J Med* 2020;383:2207–2218.
7. Kasi A, Abbasi S, Handa S et al. Total neoadjuvant therapy vs standard therapy in locally advanced rectal cancer: A systematic review and meta-analysis. *JAMA Netw Open* 2020;3:e2030097.
8. Garcia-Aguilar J, Patil S, Kim JK et al. Preliminary results of the Organ Preservation of Rectal Adenocarcinoma (OPRA) trial. *J Clin Oncol* 2020;38(15\_suppl):4008.
9. Bahadoer RR, Dijkstra EA, van Etten B, et al. Short-course radiotherapy followed by chemotherapy before total mesorectal excision (TME) versus preoperative chemoradiotherapy, TME, and optional adjuvant chemotherapy in locally advanced rectal cancer (RAPIDO): A randomised, open-label, phase 3 trial. *Lancet Oncol* 2021;22:29–42.
10. Keane C, Wells C, O’Grady G et al. Defining low anterior resection syndrome: A systematic review of the literature. *Colorectal Dis* 2017;19:713–722.
11. Lange MM, van de Velde CJ. Urinary and sexual dysfunction after rectal cancer treatment. *Nat Rev Urol* 2011;8:51–57.
12. Boland CR, Goel A. Microsatellite instability in colorectal cancer. *Gastroenterology* 2010;138:2073–2087.
13. Lenz HJ, Lonardi S, Zagonel V et al. Nivolumab (NIVO) + low-dose ipilimumab (IPI) as first-line (1L) therapy in microsatellite instability-high/mismatch repair-deficient (MSI-H/dMMR) metastatic colorectal cancer (mCRC): Two-year clinical update. *J Clin Oncology* 2020;38:4040.
14. Overman MJ, Lonardi S, Wong KYM et al. Durable clinical benefit with nivolumab plus ipilimumab in dna mismatch repair-deficient/microsatellite instability-high metastatic colorectal cancer. *J Clin Oncol* 2018;36:773–779.
15. Morse MA, Hochster H, Benson A. Perspectives on treatment of metastatic colorectal cancer with immune checkpoint inhibitor therapy. *The Oncologist* 2020;25:33–45.
16. Chalabi M, Fanchi LF, Dijkstra KK et al. Neoadjuvant immunotherapy leads to pathological responses in MMR-proficient and MMR-deficient early-stage colon cancers. *Nat Med* 2020;26:566–576.
17. Hasan S, Renz P, Wegner RE et al. Microsatellite instability (MSI) as an independent predictor of pathologic complete response (PCR) in locally advanced rectal cancer: A National Cancer Database (NCDB) analysis. *Ann Surg* 2020;271:716–723.
18. Cercek A, Dos Santos Fernandes G, Roxburgh CS et al. Mismatch repair-deficient rectal cancer and resistance to neoadjuvant chemotherapy. *Clin Cancer Res* 2020;26:3271–3279.
19. Zhang J, Cai J, Deng Y et al. Complete response in patients with locally advanced rectal cancer after neoadjuvant treatment with nivolumab. *Oncoimmunology* 2019;8:e1663108.
20. Demisse R, Damle N, Kim E et al. Neoadjuvant immunotherapy-based systemic treatment in MMR-deficient or MSI-high rectal cancer: Case series. *J Natl Compr Canc Netw* 2020;18:798–804.