

Percutaneous dual-outflow extracorporeal membrane oxygenation support in secondary right ventricular failure



Florian Hecker, MD,^a Harald Keller, ECCP,^a Mariuca Vasa-Nicotera, MD,^b Sonja Iken, MD,^c and Tomas Holubec, MD, PhD,^a Frankfurt, Germany

From the Departments of ^aCardiovascular Surgery; ^bMedicine, Cardiology; and ^cMedicine, Anesthesiology, University Hospital Frankfurt and Goethe University Frankfurt, Frankfurt, Germany.

Disclosures: The authors reported no conflicts of interest.

The *Journal* policy requires editors and reviewers to disclose conflicts of interest and to decline handling or reviewing manuscripts for which they may have a conflict of interest. The editors and reviewers of this article have no conflicts of interest.

Received for publication May 7, 2020; accepted for publication Feb 16, 2022; available ahead of print Feb 21, 2022.

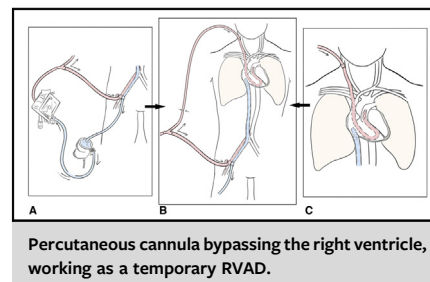
Address for reprints: Tomas Holubec, MD, PhD, Department of Cardiovascular Surgery, University Hospital Frankfurt and Goethe University Frankfurt, Theodor-Stern-Kai 7, 60596 Frankfurt am Main, Germany (E-mail: tomasholubec@email.cz).

JTCVS Techniques 2022;13:125-7

2666-2507

Copyright © 2022 The Author(s). Published by Elsevier Inc. on behalf of The American Association for Thoracic Surgery. This is an open access article under the CC BY-NC-ND license (<http://creativecommons.org/licenses/by-nc-nd/4.0/>).

<https://doi.org/10.1016/j.xjtc.2022.02.020>



CENTRAL MESSAGE

Percutaneous mechanical circulatory support of the right ventricle is a safe and feasible therapy in drug-refractory acute on chronic right ventricular failure due to severe pulmonary hypertension.

▶ Video clip is available online.

Drug-refractory right ventricular failure (RVF) is mostly caused by pressure and volume overload of the right ventricle (RV) due to its limited muscular pump function. Pulmonary artery hypertension (PAH) is an important contributing factor leading to the progression of secondary RVF (s-RVF).¹ Acute on chronic s-RVF is reported to have a high mortality rate; that is, 40%.² Mechanical circulatory support of the RV may be the only therapeutic strategy for this rapidly progressive syndrome. It has been reported to be successful with various percutaneous cannulation techniques in cases of RVF due to myocardial infarction after left ventricular assist device implantation and prior lung transplantation.^{3,4}

Herein, we describe our experience with a percutaneously implanted RV assist device (RVAD) combined with a regular venoarterial extracorporeal membrane oxygenation (ECMO) setup in a patient with acute s-RVF due to PAH under ongoing resuscitation. Informed consent for the publication of the study data was obtained from patient and no ethic committee/institutional review board approval is needed for this report according to the German law.

CASE REPORT

A 65-year-old man was admitted to the hospital presenting with acute coronary syndrome. The first intervention

was done 23 years ago, followed by multiple reinterventions due to recurring in-stent restenosis in all 3 coronary vessels. The coronary angiography showed a critical in-stent restenosis of the left anterior descending and an ostial stenosis of the ramus intermedius artery. Echocardiography revealed preserved left ventricle function with reduced RV function. The tricuspid annular plane systolic excursion was at 14 mm without dilatation of the tricuspid valve annulus (28 mm) but signs of RV dilatation. The approximated systolic pulmonary artery pressure (PAP) over the tricuspid valve was 100 mm Hg plus central venous pressure. The patient received a right heart catheterization, which confirmed the elevated PAP of 90 mm Hg with a regular pulmonary capillary wedge pressure and, following supplementary computed tomography-angiography, was diagnosed with a precapillary idiopathic type I PAH. Due to his critical coronary state with unstable angina and being inappropriate for an interventional therapy approach, the patient was scheduled for urgent minimally invasive direct coronary artery bypass surgery.

Despite maximal PAH, specific preventive measures during induction of anesthesia, the patient became hemodynamically unstable requiring cardiopulmonary resuscitation. Return of spontaneous circulation was achieved shortly using high doses of inotropic agents. Surgery was postponed, and

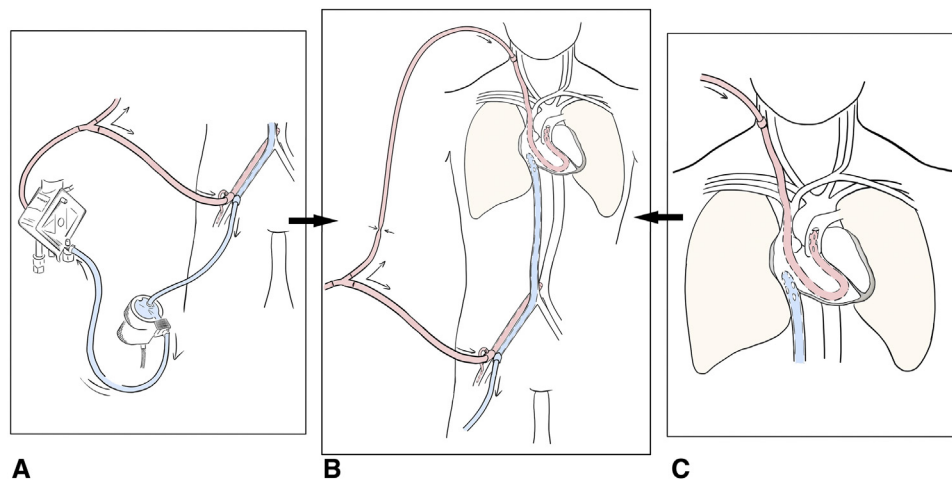


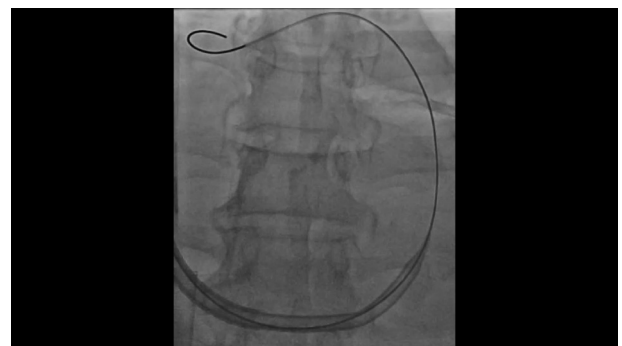
FIGURE 1. A, Detailed part of the venoarterial extracorporeal membrane oxygenation (ECMO) delivering systemic perfusion via outflow cannula in femoral artery and systemic venous drainage for initial systemic stabilization. B, Total percutaneous dual-outflow ECMO setup delivering oxygenated blood via right femoral artery and pulmonary artery and drains systemic venous blood via femoral vein. C, Detailed part of the 21Fr outflow cannula from the internal jugular vein to the pulmonary trunk. Blood flow is symbolized with arrows, the pinching arrows describe the pulmonary outflow in-line flow reducer.

due to circulatory instability despite maximal inotropic support, mechanical circulatory support was indicated. Under ongoing mechanical resuscitation, venoarterial-venous, PA ECMO support was established (Figure 1, B). An inflow cannula was percutaneously inserted via the right femoral vein (Getinge HLS 23Fr, 55 cm) into the right atrium and an outflow cannula was inserted into the right femoral artery (Getinge HLS 17Fr, 23 cm) for initial stabilization (Figure 1, A). Thereafter, a soft guidewire was placed percutaneously via the right internal jugular vein through the tricuspid and pulmonary valves, with its tip into the right PA under fluoroscopic control in the catheterization lab. The soft guidewire was then exchanged via a pigtail catheter for an extrastiff wire (Lunderquist; Cook Medical), which was guided to the PA trunk. Finally, a prewarmed 21Fr cannula with a multihole tip (Biomedicus 21Fr, 50 cm; Medtronic) was percutaneously inserted over the stiff wire and connected to the outflow line of the ECMO system with a monitored in-line flow-reducer (Figure 1, C, and Video 1). Thus, while bypassing the acute failing RV, this cannula acted as a temporary RVAD.

The femoral arterial outflow cannula was explanted by using a percutaneous closure device after 48 hours due to the recovery of the left ventricle. The remaining temporary RVAD with oxygenator was successfully explanted at day 8 after implantation. Tricuspid and pulmonary valve were without any possible RV cannula associated alterations. Thereafter the patient recovered well, was awake and extubated, and could be discharged for further medical therapy on day 21. After 1-year follow-up, the patient is doing well under medication with sildenafil 20 mg 3 times daily. His coronary artery disease is being address with medical therapy and no further intervention was done.

DISCUSSION

Functional improvement of the RV after normalization of loading conditions under the support of temporary RVAD systems has been described but has been rarely used in cases of isolated acute on chronic s-RVF due to exacerbation of PAH, and remains controversial.^{4,5} Despite an extremely high PAP in our patient, we saw no signs of pulmonary edema or hemorrhage. Instead of totally bypassing the pulmonary circulation, we chose the dual-outflow concept for a more dynamic and, especially, a faster systemic weaning process. Alternatively, we could have used the Impella RP system (Abiomed) or the LivaNova ProtekDuo cannula (LivaNova) for RV support. Neither system was in routine use at our center. Furthermore, the ProtekDuo cannula would have had less effective drainage capacity to support pulmonary and systemic perfusion parameters and would have prolonged the initial systemic stabilization by venoarterial ECMO.



VIDEO 1. Percutaneous deployment of the 21Fr outflow cannula from the internal jugular vein to the pulmonary trunk along an extrastiff guidewire and the final result after removing the cannula's inner sheath under fluoroscopic vision. Video available at: [https://www.jtcvs.org/article/S2666-2507\(22\)00126-2/fulltext](https://www.jtcvs.org/article/S2666-2507(22)00126-2/fulltext).

This case demonstrates our first and successful treatment of a patient with acute on chronic RVF due to severe primary PAH with implantation of a percutaneous RVAD system combined with a regular venoarterial ECMO circuit in a clinical situation of ongoing resuscitation. The approach may be a feasible and safe treatment for patients with these critical clinical conditions, but requires further clinical experience.

The authors thank Ms Ishewski, ECCP for the professional drawings.

References

1. Dandel M, Hetzer R. Temporary assist device support for the right ventricle: pre-implant and post-implant challenges. *Heart Fail Rev.* 2018;23:157-71.
2. Cassidy S, Ramani GV. Right heart failure in pulmonary hypertension. *Cardiol Clin.* 2020;38:243-55.
3. Savale L, Weatherald J, Jaïs X, Vuillard C, Boucly A, Jevnikar M, et al. Acute decompensated pulmonary hypertension. *Eur Respir Rev.* 2017;26:170092.
4. Lorusso R, Raffa GM, Heuts S, Lo Coco V, Meani P, Natour E, et al. Pulmonary artery cannulation to enhance extracorporeal membrane oxygenation management in acute cardiac failure. *Interact Cardiovasc Thorac Surg.* 2020;30:215-22.
5. Verbelen T, Burkhoff D, Kasama K, Delcroix M, Rega F, Meyns B. Systolic and diastolic unloading by mechanical support of the acute vs the chronic pressure overloaded right ventricle. *J Heart Lung Transplant.* 2017;36:457-65.