



# Injury patterns of the spine following blunt trauma: A per-segment analysis of spinal structures and their detection rates in CT and MRI<sup>☆</sup>

Leon David Gruenewald<sup>a,\*</sup>, Vitali Koch<sup>a</sup>, Katrin Eichler<sup>a</sup>, Jasmin Bauer<sup>a</sup>,  
Tatjana Gruber-Rouh<sup>a</sup>, Christian Booz<sup>a</sup>, Ibrahim Yel<sup>a</sup>, Scherwin Mahmoudi<sup>a</sup>,  
Thomas J. Vogl<sup>a</sup>, André El Saman<sup>b</sup>

<sup>a</sup> Department of Diagnostic and Interventional Radiology, University Hospital Frankfurt, Theodor-Stern-Kai 7, 60590 Frankfurt am Main, Germany

<sup>b</sup> Department of Trauma, Hand and Reconstructive Surgery, University Hospital Frankfurt, Theodor-Stern-Kai 7, 60590 Frankfurt am Main, Germany

## ARTICLE INFO

### Keywords:

Spinal injuries  
Magnetic resonance imaging  
Computed tomography imaging  
Wounds  
Nonpenetrating  
Vertebral body

## ABSTRACT

**Rationale and objectives:** To provide a detailed analysis of injury patterns of the spine following blunt trauma and establish the role of supplementary MRI by evaluating discrepancies in the detection rates of damaged structures in CT and MRI.

**Method:** 216 patients with blunt trauma to the spine who underwent CT followed by supplementary MRI were included in this study. Two board-certified radiologists blinded to clinical symptoms and injury mechanisms independently interpreted all acquired CT and MRI images. The interpretation was performed using a dedicated catalogue of typical findings associated with spinal trauma and assessed for spinal stability using the AO classification systems.

**Results:** Lesions to structures associated with spinal instability were present in 31.0% in the cervical spine, 12.3% in the thoracic spine, and 29.9% in the lumbar spine. In all spinal segments, MRI provided additional information regarding potentially unstable injuries. Novel information derived from supplementary MRI changed clinical management in 3.6% of patients with injury to the cervical spine. No change in clinical management resulted from novel information on the thoracolumbar spine. Patients with injuries to the vertebral body, intervertebral disc, or spinous process were significantly more likely to benefit from supplementary MRI.

**Conclusion:** In patients that sustained blunt spinal trauma, supplementary MRI of the cervical spine should routinely be performed to detect injuries that require surgical treatment, whereas CT is the superior imaging modality for the detection of unstable injuries in the thoracolumbar spine.

## 1. Introduction

Injuries of the spine are a common finding in polytraumatized patients. According to the National Trauma Data Bank 2010, 13% of

<sup>☆</sup> This research received no specific grant from funding agencies in the public, commercial, or not-for-profit sectors.

\* Corresponding author. Department of Diagnostic and Interventional Radiology, Division of Experimental Imaging, University Hospital Frankfurt, Theodor-Stern-Kai 7, 60590 Frankfurt am Main, Germany.

E-mail address: [leondavid.gruenewald@kgu.de](mailto:leondavid.gruenewald@kgu.de) (L.D. Gruenewald).

<https://doi.org/10.1016/j.heliyon.2023.e17396>

Received 3 May 2023; Received in revised form 13 June 2023; Accepted 15 June 2023

Available online 21 June 2023

2405-8440/© 2023 The Authors. Published by Elsevier Ltd. This is an open access article under the CC BY-NC-ND license (<http://creativecommons.org/licenses/by-nc-nd/4.0/>).

adult patients that sustained a blunt trauma were diagnosed with one or more fractures of the spine, and 7% of these patients sustained spinal cord injury (SCI) [1]. In the United States alone, approximately 85,000 cases of spinal column fractures and 10,000 cases of spinal cord injury occur annually [2].

In acute trauma management, detecting spinal injuries is particularly important due to the risk of spinal cord injury (SCI). In most cases, SCI is caused by bony fractures from direct trauma to the spine, which are easily picked up on CT. In some instances, however, disruption of vertebral discs or ligamentous injury alone will cause spinal injuries and possibly lead to permanent neurological deficits [3,4].

CT imaging is currently the standard of care in polytraumatized patients with spine involvement due to its superiority in detecting bony injuries and the speed of examinations [5–7]. Material differentiation in dual-energy CT (DECT) allows for a certain degree of visualization of soft tissue and marrow edema and provides novel information for different musculoskeletal applications compared to conventional single-energy CT [8–13]. However, this technology is not broadly available and in conventional CT, the assessment of the ligamentous structures, intervertebral discs, and the spinal cord is not sufficiently possible, resulting in missed unstable injuries and subsequent SCI [14–16]. This has led to an ongoing debate about whether additional MRI of the spine can provide clinically relevant additional information that changes the management of spine injuries, with many studies reporting conflicting results [17–19]. Recent studies that assessed different imaging modalities to clear the cervical spine, for example, reported detection rates of new injuries by supplementary MRI between 3.3% and 54%, with an average of 15% [18,20,21]. Similar variability between studies is observed regarding the detection rates of injuries classified as unstable, rooted in varying criteria for spinal instability and discrepancies in study design.

For the cervical spine, Malhotra et al. reported an incidence as low as 0.3% for the occurrence of unstable injuries, indicating a subordinate role of routinely performed supplementary MRI. These findings align with current recommendations by professional societies, which suggest a CT-only approach for the initial assessment, supplemented by MRI only when neurological deficits are present or to assist preoperative planning. The same diagnostic approach is generally suggested for injuries to the thoracolumbar spine, with almost identical reasoning [18,22–24].

The purpose of this study was to provide a detailed analysis of injury patterns of all spinal segments and structures following blunt trauma to the spine and, with this information, to establish the proportion of potentially unstable injuries. Furthermore, we aimed to evaluate discrepancies in detection rates of individual lesions in CT and MRI to determine how often supplementary MRI will provide additional information and change clinical management. Last, we wanted to establish if specific lesions detected in CT are more likely to provide additional findings in MRI.

## 2. Materials and methods

### 2.1. Institutional review board approval

This is a retrospective study. Approval was granted by the institutional review board (Ethics Committee of the University Hospital Frankfurt am Main), which waived the requirement to obtain written informed consent.

### 2.2. Patient selection and study design

This is a retrospective, single center study performed at the main trauma center for a city with a population >750,000. Patients who had undergone CT of the spine followed by MRI of the same spinal segments between January 2014 and December 2020 were considered for inclusion in this study. Inclusion criteria were an age >18 years, sustained blunt trauma to the spine and a maximum time interval between CT and MR of 10 days. Exclusion criteria were spine examinations due to non-traumatic reasons (i.e., suspected spondylitis or spondylodiscitis, degenerative spine disease, or malignancy) and surgical spine procedures performed before MRI examinations. Of 800 patients considered for study inclusion, we excluded 267 patients that underwent surgical procedures of the spine before an MRI was performed, and 317 patients that received imaging due to non-traumatic reasons such as inflammatory spinal conditions or suspected malignancy. Therefore, a total of 216 patients (152 male and 64 female) with a mean age of 42.8 years (range, 4–85 years) were included in this study (Fig. 1).

### 2.3. CT and MR imaging

CT imaging was conducted using a second-generation 128-slice dual-source CT (Somatom Definition Flash, Siemens Healthcare, Erlangen, Germany). Image series (axial, coronal, and sagittal: section thickness 1 mm, increment 0.75 mm) were reconstructed with a dedicated bone kernel. The CT protocols used in the setting of acute trauma in our institution include unenhanced head and cervical spine images and split-bolus contrast enhanced imaging of the lung, abdomen and thoracolumbar spine, adapted as needed.

MR imaging was conducted with a 1.5-T Magnetom Avanto, 1.5-T Magnetom Espree, or 3-T Magnetom Trio system (all from Siemens Healthcare) using similar protocols with a body spine-array coil and fast spin-echo imaging. As per institutional guidelines, T1-weighted, T2-weighted, and T2 turbo inversion recovery magnitude (TIRM) images were obtained in the sagittal plane, and T1- and T2-weighted images were obtained in the axial plane, patient supine. For sagittal imaging, a FOV of 32 cm, matrix of 512 × 256, and slice thickness of 4 mm were used, and for axial images a FOV of 22 cm, matrix of 320 × 320 and slice thickness of 3 mm were used.

The image series were automatically transferred to the picture archiving and communication system (PACS; General Electric Company).

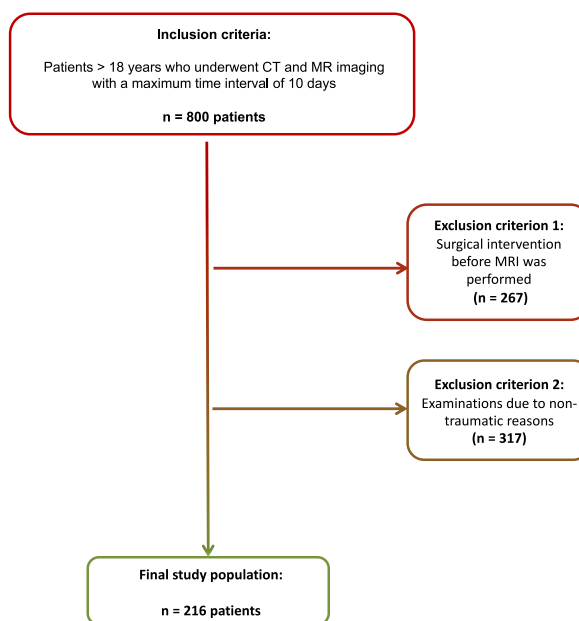


Fig. 1. Note. – STARD flow diagram of patient selection.

#### 2.4. Unstable spine injuries

Injuries to the upper cervical spine were classified as potentially unstable with a classifier of B or above in the AO Spine classification of upper cervical injuries, including atypical Jefferson fractures with or without disruption of the transverse ligament, (sub-)luxation of C1/C2 > 7 mm or transverse ligament avulsion of the C1 tubercle [25,26].

Injuries to the subaxial cervical spine were classified as potentially unstable with a classifier of A3 and above in the AO Spine classification of subaxial injuries, including injuries with involvement of the posterior vertebral wall with or without retropulsion of vertebral fragments, tension band injuries (including injuries to the posterior ligamentous complex [PLC]) and translational injuries, including facet joint (sub-)luxation [25,26].

Injuries to the thoracolumbar spine were classified as potentially unstable with a classifier of A4 and above in the AO Spine classification of thoracolumbar injuries, including injuries with involvement of both endplates and the posterior wall, distraction injuries, and translation injuries [27].

Furthermore, injuries to the spinal cord and traumatic spinal canal compression were classified as unstable in all segments.

#### 2.5. Image interpretation

Two radiologists with 14 and 37 years of experience in musculoskeletal imaging (K.E. and T.V.) analyzed all acquired CT and MRI images independent of the initial clinical symptoms and injury mechanisms using a dedicated catalogue of typical findings in the setting of spinal trauma. In case of disagreement, a third radiologist with 17 years of experience in musculoskeletal imaging (T.G.) was consulted. Reported is the majority decision. Case shuffling was used for CT and MRI analysis to prevent observer recall bias. Analysis was performed for each injured spinal segment, as suggested in the AO classification systems [25–27].

#### 2.6. Statistical analysis

Statistical analysis was performed with dedicated commercial software (Prism 9 for macOS, version 9.0.0, GraphPad Software LLC, San Diego; MedCalc for Windows, Version 13, MedCalc, Mariakerke, Belgium). Differences in baseline characteristics were analyzed by unpaired t-tests for continuous variables and Fisher's exact test for categorical values. All imaging data were compiled in cross-tables. Differences in CT and MRI detection rates were analyzed using McNemar's test. Cohens Kappa was calculated for the agreement of CT and MR imaging between readers and the intraclass correlation coefficient (ICC) was calculated in a 2-way mixed-effects model for absolute agreement to obtain the agreement between CT and MR imaging. A p-value less than 0.05 was considered statistically significant.

### 3. Results

#### 3.1. Study population and injury mechanisms

216 patients (152 male and 64 female) with a mean age of 42.8 years (range, 4–85 years) were included in this study. The mechanisms of injury included traffic accidents ( $n = 109$ , 50.5%) and falls ( $n = 94$ , 43.5%). In 13 cases (6.0%), the mechanism of injury could not be determined. Neurological symptoms were present in 68 of 216 patients (31.5%). Of these, 12 patients showed signs of acute SCI, and 16 were obtunded. Detailed patient characteristics are depicted in [Table 1](#).

#### 3.2. Image acquisition

All patients underwent CT followed by MRI of the same spine segment. 190 of 216 (88.0%) patients received CT imaging immediately after trauma; however, the examination of some patients was delayed for up to 3 days. The average time interval between trauma and the initial CT examination was 0.08 days (range, 0–3 days). MRI of the same spine segment was performed on average 1.62 (range: 1 to 10) days after the initial CT examination.

Imaging of the cervical spine was the most frequently performed examination, with 117 cases, followed by imaging of the lumbar spine ( $n = 53$ ) and the thoracic spine ( $n = 32$ ). In 43 cases, more than one region was examined, and imaging of the whole spine was performed in 27 patients. Cohens kappa demonstrated very good agreement between both readers for CT imaging with a value of 0.84 and good agreement for MR imaging with a value of 0.72.

#### 3.3. Medical indications for requested imaging modalities

Due to hospital policy, the mechanism of trauma was the most common medical indication why CT imaging was requested, followed by neurological deficits ( $n = 41$ , 19%) and severe or persistent pain ( $n = 34$ , 15.7%). MRI imaging was obtained primarily to confirm suspected ligamentous injury and injury to soft tissue structures ( $n = 92$ , 43.6%), followed by previous imaging modalities being indicative of injury ( $n = 67$ , 31.0%) as well as the evaluation of neurological deficits ( $n = 66$ , 30.6%).

#### 3.4. Sustained injuries

The most common injuries sustained by patients in our study cohort were fractures of the vertebral bodies, predominantly affecting the thoracic and lumbar spine (up to 23.2%), followed by lesions of the intervertebral disc (up to 13.6%) and large pre- and paravertebral hematomas (up to 11.8%).

In the sub-cohort of patients with neurological symptoms, injuries predominantly affected the spinal cord of the cervical spine (up to 20.8%), followed by large pre- and paravertebral hematomas of cervical spine segments (up to 15.1%) and damage to interspinous ligaments (up to 11.3%). A heatmap depicting the injury patterns in the study cohort and the sub-cohort of patients with neurological deficits is given in [Tables 2 and 3](#).

#### 3.5. Differences in imaging modalities

As expected, MRI detection rates for injuries to the spinal cord, spinal ligaments, intervertebral discs, and paravertebral hematomas were superior compared to CT. In line with current literature, CT examinations provided higher detection rates for osseous injuries to the anterior and posterior edges of the vertebral bodies and the vertebral joints and processes. An overview over the detection rates for

**Table 1**

Note. – Detailed patient characteristics. The average age of the study population was  $42.8 \pm 20.0$  years. Mechanisms of injury included traffic accidents ( $n = 109$ ) and falls ( $n = 94$ ). In 13 cases, the mechanism of injury could not be determined. Neurological symptoms were present in 68 of the 216 patients.

Variables – mean $\pm$ SD or n (%)	Total (n = 216)	Neurological Symptoms (n = 68)
Age (years)	42.8 $\pm$ 20.0	41.2 $\pm$ 18.2
Sex (n)		
Male	152 (70.4%)	46 (67.6%)
Female	64 (29.6%)	22 (32.4%)
Mechanism of injury (n)		
Traffic Accidents	109 (50.5%)	27 (39.7%)
• Car/Motorcycle	44 (20.4%)	14 (20.6%)
• Bicycle/Pedestrian	36 (16.7%)	7 (10.3%)
• Undetermined	29 (13.4%)	6 (8.8%)
Fall/Jump	94 (43.5%)	37 (54.4%)
• Heights > 2 m	66 (30.6%)	23 (33.8%)
• Level Ground	18 (8.3%)	9 (13.2%)
• Undetermined	10 (4.6%)	5 (7.3%)
Not Determined	13 (6.0%)	4 (5.9%)

**Table 2**

Note. – Heat map of image findings in CT and MRI in all patients. The evaluation was performed separately for each vertebra. We observed a clustering of lesions affecting the vertebral bodies of the thoracic and lumbar spine and the cervical spine’s ligamentous structures and spinal cord.

Segment	Vertebral Body [CT]	Vertebral Body [MRI]	Bone bruise [MRI]	Intervertebral Disc [MRI]	Interspinous ligament [MRI]	Spinal Cord [MRI]	Hematoma [MRI]
C1 (Arch)	13 (9.2%)	14 (9.7%)	0 (0.0%)	n.a.	3 (2.1%)	2 (1.4%)	6 (4.2%)
C2 (Dens & Arch)	5 (3.5%)	6 (4.2%)	2 (1.4%)	1 (0.7%)	6 (4.2%)	3 (2.1%)	11 (7.6%)
C3	6 (4.2%)	6 (4.2%)	4 (2.8%)	7 (4.9%)	11 (7.6%)	13 (9.0%)	14 (9.7%)
C4	3 (2.1%)	4 (2.8%)	6 (4.2%)	2 (1.4%)	13 (9.0%)	14 (9.7%)	14 (9.7%)
C5	5 (3.5%)	8 (5.6%)	8 (5.6%)	6 (4.2%)	15 (10.4%)	14 (9.7%)	17 (11.8%)
C6	7 (4.9%)	9 (6.3%)	7 (4.9%)	11 (7.6%)	13 (9.0%)	15 (10.4%)	16 (11.1%)
C7	8 (5.5%)	16 (11.0%)	10 (6.9%)	0 (0.0%)	13 (9.0%)	7 (4.8%)	11 (7.6%)
Th1	5 (4.9%)	8 (7.8%)	8 (7.8%)	1 (1.0%)	5 (4.9%)	2 (1.9%)	5 (4.9%)
Th2	15 (15.6%)	16 (16.7%)	9 (9.4%)	2 (2.1%)	3 (3.1%)	0 (0.0%)	3 (3.1%)
Th3	16 (17.4%)	20 (21.7%)	13 (14.1%)	1 (1.1%)	2 (2.2%)	0 (0.0%)	5 (5.4%)
Th4	14 (15.7%)	17 (19.1%)	11 (12.4%)	1 (1.1%)	5 (5.6%)	0 (0.0%)	6 (6.7%)
Th5	17 (20.0%)	17 (20.0%)	9 (10.6%)	3 (3.5%)	4 (4.7%)	2 (2.4%)	6 (7.1%)
Th6	13 (15.7%)	15 (18.1%)	8 (9.6%)	0 (0.0%)	2 (2.4%)	2 (2.4%)	4 (4.8%)
Th7	11 (13.6%)	10 (12.3%)	7 (8.6%)	4 (4.9%)	0 (0.0%)	1 (1.2%)	2 (2.5%)
Th8	9 (11.0%)	8 (9.8%)	5 (6.1%)	3 (3.7%)	1 (1.2%)	1 (1.2%)	1 (1.2%)
Th9	7 (8.5%)	9 (11.0%)	5 (6.1%)	3 (3.7%)	1 (1.2%)	0 (0.0%)	1 (1.2%)
Th10	5 (5.9%)	6 (7.1%)	4 (4.7%)	3 (3.5%)	3 (3.5%)	0 (0.0%)	0 (0.0%)
Th11	8 (8.8%)	9 (9.9%)	6 (6.6%)	10 (11.0%)	1 (1.1%)	0 (0.0%)	0 (0.0%)
Th12	15 (14.4%)	17 (16.3%)	17 (16.3%)	11 (10.6%)	1 (1.0%)	0 (0.0%)	1 (1.0%)
L1	19 (23.2%)	16 (19.8%)	10 (12.3%)	11 (13.6%)	2 (2.5%)	0 (0.0%)	1 (1.2%)
L2	16 (20.0%)	16 (20.3%)	16 (20.3%)	5 (6.3%)	2 (2.5%)	0 (0.0%)	0 (0.0%)
L3	6 (7.5%)	6 (7.6%)	5 (6.3%)	5 (6.3%)	2 (2.5%)	0 (0.0%)	0 (0.0%)
L4	6 (7.6%)	6 (7.6%)	5 (6.3%)	1 (1.3%)	1 (1.3%)	1 (1.3%)	0 (0.0%)
L5	2 (2.5%)	3 (3.8%)	2 (2.5%)	0 (0.0%)	1 (1.3%)	0 (0.0%)	1 (1.3%)

**Table 3**

Note. – Heat map of image findings in CT and MRI in patients with neurological deficits. The evaluation was performed separately for each vertebra. In contrast to [Table 2](#), the clustering of lesions affecting the thoracolumbar spine has widely disappeared, but the clustering affecting the ligamentous structures and spinal cord of the cervical spine showed a sharp increase.

Segment	Vertebral Body [CT]	Vertebral Body [MRI]	Bone bruise [MRI]	Intervertebral Disc [MRI]	Interspinous ligament [MRI]	Spinal Cord [MRI]	Hematoma [MRI]
C1 (Arch)	2 (3.8%)	1 (1.9%)	0 (0.0%)	n.a.	1 (1.9%)	0 (0.0%)	1 (1.9%)
C2 (Dens & Arch)	1 (1.9%)	2 (3.8%)	0 (0.0%)	0 (0.0%)	0 (0.0%)	2 (3.8%)	2 (3.8%)
C3	2 (3.8%)	1 (1.9%)	0 (0.0%)	0 (0.0%)	2 (3.8%)	7 (13.2%)	5 (9.4%)
C4	0 (0.0%)	0 (0.0%)	0 (0.0%)	1 (1.9%)	6 (11.3%)	11 (20.8%)	7 (13.2%)
C5	3 (5.7%)	3 (5.7%)	1 (1.9%)	3 (5.7%)	5 (9.4%)	11 (20.8%)	8 (15.1%)
C6	2 (3.8%)	2 (3.8%)	2 (3.8%)	2 (3.8%)	2 (3.8%)	8 (15.1%)	8 (15.1%)
C7	0 (0.0%)	1 (1.9%)	1 (1.9%)	0 (0.0%)	1 (1.9%)	4 (7.5%)	4 (7.5%)
Th1	0 (0.0%)	1 (3.1%)	1 (3.1%)	0 (0.0%)	0 (0.0%)	1 (3.1%)	3 (9.4%)
Th2	1 (3.4%)	2 (6.9%)	1 (3.4%)	0 (0.0%)	1 (3.4%)	0 (0.0%)	1 (3.4%)
Th3	3 (10.3%)	3 (10.3%)	1 (3.4%)	1 (3.4%)	1 (3.4%)	0 (0.0%)	2 (6.9%)
Th4	2 (7.1%)	2 (7.1%)	0 (0.0%)	0 (0.0%)	0 (0.0%)	0 (0.0%)	0 (0.0%)
Th5	2 (7.4%)	1 (3.7%)	2 (7.4%)	0 (0.0%)	1 (3.7%)	1 (3.7%)	1 (3.7%)
Th6	1 (3.7%)	1 (3.7%)	2 (7.4%)	0 (0.0%)	0 (0.0%)	1 (3.7%)	0 (0.0%)
Th7	2 (7.4%)	1 (3.7%)	1 (3.7%)	1 (3.7%)	0 (0.0%)	1 (3.7%)	0 (0.0%)
Th8	2 (7.4%)	3 (11.1%)	1 (3.7%)	1 (3.7%)	0 (0.0%)	1 (3.7%)	0 (0.0%)
Th9	2 (7.4%)	2 (7.4%)	0 (0.0%)	0 (0.0%)	1 (3.7%)	0 (0.0%)	0 (0.0%)
Th10	1 (3.7%)	1 (3.7%)	0 (0.0%)	0 (0.0%)	0 (0.0%)	0 (0.0%)	0 (0.0%)
Th11	0 (0.0%)	1 (3.7%)	1 (3.7%)	0 (0.0%)	0 (0.0%)	0 (0.0%)	0 (0.0%)
Th12	2 (6.7%)	2 (6.7%)	1 (3.3%)	3 (10.0%)	0 (0.0%)	0 (0.0%)	0 (0.0%)
L1	2 (8.7%)	2 (8.7%)	1 (4.3%)	1 (4.3%)	0 (0.0%)	0 (0.0%)	0 (0.0%)
L2	1 (4.3%)	1 (4.3%)	0 (0.0%)	0 (0.0%)	0 (0.0%)	0 (0.0%)	0 (0.0%)
L3	0 (0.0%)	0 (0.0%)	1 (4.3%)	0 (0.0%)	0 (0.0%)	0 (0.0%)	0 (0.0%)
L4	0 (0.0%)	0 (0.0%)	0 (0.0%)	0 (0.0%)	0 (0.0%)	0 (0.0%)	0 (0.0%)
L5	1 (4.3%)	1 (4.3%)	0 (0.0%)	0 (0.0%)	0 (0.0%)	0 (0.0%)	0 (0.0%)

different spinal structures in all patients and in the subgroup of patients with neurological deficits is given in [Tables 4 and 5](#).

MRI revealed lesions in 29 of 216 patients (13.4%) without traumatic findings in the preceding CT scans. We observed no significant association with gender, age or trauma mechanism. Of these, 20 patients (69.0%,  $p < 0.005$ ) showed neurological deficits. MRI provided additional information that changed clinical management in six of 216 patients, four of which required surgical intervention due to cervical posterior tension band injuries. In two patients, MRI revealed myelopathy without compression of the myelon; subsequently, both patients received corticosteroids.

Moreover, MRI provided additional information in almost every patient and all spine segments, as described in the following chapters. Patients in which supplementary MRI revealed lesions associated with unstable injuries of the spine showed significantly higher rates of injuries to the intervertebral discs ( $p < 0.005$ ), the vertebral body ( $p < 0.005$ ), particularly the anterior and posterior walls of the vertebral body ( $p < 0.005$ ), and the spinous processes ( $p < 0.05$ ). In line, agreement between CT and MR imaging was only moderate with an ICC of 0.44. Detailed information is given in the [Supplementary Tables 1–3](#).

### 3.6. Unstable injuries to the cervical spine

Injuries associated with instability of the upper and subaxial cervical spine were present in 31.0% of all analyzed structures, predominantly affecting the interspinous ligaments (7.0%), vertebral bodies (6.3%), and spinal cord (6.7%). Of these, 69.0% (21.4% of all lesions) were only detected in MRI, and 5.8% were only visible in CT (1.8% of all lesions). Most injuries missed in CT imaging affected the interspinous ligaments (6.8%), the spinal cord (6.6%), and the intervertebral discs (1.7%).

Similar observations were made for the sub-cohort of patients with neurological deficits. In this group, injuries associated with unstable injuries of the cervical spine were present in 25.7% of all analyzed structures, predominantly affecting the spinal cord (11.6%), interspinous ligaments (4.6%), and intervertebral discs (1.9%). In this sub-cohort, 88.7% (22.8% of all lesions) were only picked up in MRI with almost identical distributions. None of the lesions were visible in CT scans only.

### 3.7. Unstable injuries to the thoracic spine

We found injuries to 12.3% of all structures associated with a potentially unstable thoracic spine, most commonly to the intervertebral disc (4.2% of injuries), followed by injuries to the posterior wall of the vertebral body (2.4%) and the interspinous ligaments (2.3%). Of these, 52.0% (6.4% of all lesions) were only detected in MRI, affecting predominantly interspinous ligaments (2.3%), intervertebral discs (1.5%), and the spinal cord (0.8%). In 13.0% (1.6% of all lesions), lesions were detected in CT only, affecting almost exclusively the bony structures, predominantly the posterior wall of the vertebral body (50% of lesions missed in MRI).

In the cohort of patients with neurological deficits, lesions associated with an unstable spine were found in 6.5% of all segments, affecting the intervertebral discs (1.5%), interspinous ligaments (1.2%), and the spinal cord (1.5%) predominantly. Of these, 60.0% were only picked up in MRI, with almost identical distributions. In this sub-cohort, no lesion was visible only on CT scans.

### 3.8. Unstable injuries to the lumbar spine

We found injuries to 29,9% of all structures associated with potential instability of the lumbar spine, most commonly to the

**Table 4**

Note. – Differences of imaging findings in CT and MRI. The evaluation was performed separately for each segment. Bold entries show statistically significant differences between MRI and CT detection rates ( $p < 0.05$ ). \* $p \leq 0.05$ , \*\* $p \leq 0.01$ , \*\*\* $p \leq 0.001$ , \*\*\*\* $p \leq 0.0001$ , ns: $p > 0.05$ , na not applicable.

	Total				Neurological Symptoms			
	CT+/MRI+	CT+/MRI-	CT-/MRI+	CT-/MRI-	CT+/MRI+	CT+/MRI-	CT-/MRI+	CT-/MRI-
<b>Vertebral body (**)</b>	153	35	67	2398	21	5	11	846
Compression fractures (ns)	6	3	1	2352	2	1	0	777
Anterior edge (ns)	15	6	1	2332	3	0	0	774
Posterior edge (ns)	61	8	3	2255	7	0	1	761
Vertebral joint (ns)	8	5	0	2467	1	1	0	822
Transverse process (ns)	18	8	0	2452	2	1	0	819
<b>Spinous process (**)</b>	40	11	24	2404	10	2	4	808
<b>Bone Bruise (****)</b>	0	3	165	2341	0	1	45	805
<b>Intervertebral disc (****)</b>	35	4	42	2266	4	0	19	758
<b>Ant. Longitudinal ligament (**)</b>	13	5	19	2587	3	0	5	866
<b>Post. Longitudinal ligament (*)</b>	4	4	13	2285	2	0	2	764
<b>Ligamentum flavum (*)</b>	11	4	15	2440	0	0	6	816
<b>Interspinous ligament (****)</b>	2	3	102	2383	0	0	29	802
Supraspinous ligament (ns)	0	4	9	2469	0	0	1	822
Luxation (ns)	6	3	2	2471	1	0	1	822
Spinal canal compression (ns)	6	6	5	2456	0	0	5	818
<b>Myelon (****)</b>	1	3	75	2402	0	0	48	775
<b>Hematoma (****)</b>	2	3	121	2356	0	0	41	783

**Table 5**

Note. – Lesions associated with spinal instability in CT and MRI. The evaluation was performed separately for the cervical, thoracic, and lumbar spine and detection. Below the total percentage of lesions, the detection rates in CT and MRI are given. No information is provided for the vertebral bodies of the thoracic and lumbar spine. These lesions are not generally considered unstable without the involvement of the posterior edge, which is evaluated separately.

	Vertebralbody	Posterioredge	Vertebraljoint	Intervertebral disc	Ant.Longitudinalligament	Post.Longitudinalligament	Ligamentumflavum	Interspinousligament	Supraspinousligament	Luxation	Spinalcanalcompression	Spinalcord	Σ
<b>C1–C7</b>													
Total lesions	6,3%	0,5%	0,6%	2,7%	2,3%	1,2%	1,0%	7,0%	0,8%	0,6%	1,4%	6,7%	<b>31,0%</b>
visible in MRI only	1,9%	0,0%	0,0%	1,7%	1,3%	0,8%	0,9%	6,8%	0,7%	0,1%	0,5%	6,6%	<b>21,4%</b>
visible in CT only	0,7%	0,1%	0,2%	0,0%	0,2%	0,1%	0,1%	0,0%	0,1%	0,0%	0,3%	0,0%	<b>1,8%</b>
Neurological deficits	2,1%	0,3%	0,0%	1,9%	1,7%	0,6%	1,1%	4,6%	0,3%	0,3%	1,3%	11,6%	<b>25,7%</b>
visible in MRI only	0,2%	0,0%	0,0%	1,9%	1,2%	0,6%	1,1%	4,6%	0,3%	0,0%	1,3%	11,6%	<b>22,8%</b>
visible in CT only	0,0%	0,0%	0,0%	0,0%	0,0%	0,0%	0,0%	0,0%	0,0%	0,0%	0,0%	0,0%	<b>0,0%</b>
<b>Th1–Th12</b>													
Total lesions		2,4%	0,1%	4,2%	0,6%	0,9%	0,5%	2,3%	0,2%	0,1%	0,1%	0,9%	<b>12,3%</b>
visible in MRI only		0,3%	0,0%	1,5%	0,4%	0,5%	0,4%	2,3%	0,2%	0,0%	0,0%	0,8%	<b>6,4%</b>
visible in CT only		0,8%	0,0%	0,3%	0,1%	0,1%	0,1%	0,0%	0,0%	0,0%	0,1%	0,1%	<b>1,6%</b>
Neurological deficits		0,9%	0,0%	1,7%	0,3%	0,6%	0,3%	1,2%	0,0%	0,0%	0,0%	1,5%	<b>6,5%</b>
visible in MRI only		0,3%	0,0%	0,6%	0,0%	0,0%	0,3%	1,2%	0,0%	0,0%	0,0%	1,5%	<b>3,9%</b>
visible in CT only		0,0%	0,0%	0,0%	0,0%	0,0%	0,0%	0,0%	0,0%	0,0%	0,0%	0,0%	<b>0,0%</b>
<b>L1–L5</b>													
Total lesions		12,7%	1,5%	3,8%	1,5%	0,8%	3,7%	2,8%	0,8%	1,0%	0,8%	0,8%	<b>29,9%</b>
visible in MRI only		0,0%	0,0%	2,8%	0,0%	0,0%	0,3%	2,0%	0,0%	0,2%	0,0%	0,0%	<b>5,3%</b>
visible in CT only		1,8%	0,8%	1,0%	0,8%	0,8%	0,8%	0,8%	0,8%	0,8%	0,8%	0,8%	<b>9,5%</b>
Neurological deficits		3,5%	0,9%	0,9%	0,0%	0,0%	0,0%	0,0%	0,0%	0,0%	0,0%	0,0%	<b>5,2%</b>
visible in MRI only		0,0%	0,0%	0,9%	0,0%	0,0%	0,0%	0,0%	0,0%	0,0%	0,0%	0,0%	<b>0,9%</b>
visible in CT only		0,0%	0,0%	0,0%	0,0%	0,0%	0,0%	0,0%	0,0%	0,0%	0,0%	0,0%	<b>0,0%</b>



posterior wall of the vertebral body (12.7%), the intervertebral discs (3.8%), and the ligamentum flavum (3.7%). Of these, 17.7% (5.3% of all lesions) were only detected in MRI, affecting predominantly intervertebral discs (2.8%), interspinous ligaments (2.0%), and ligamentum flavum (0.3%). In 30.1% (9.5% of all lesions), lesions were only picked up in CT, affecting the posterior wall of the vertebral body (1.8%) and the intervertebral disc (1.0%) predominantly.

In the group of patients with neurological deficits, lesions associated with an unstable lumbar spine were found in 5.2% of all segments, affecting the posterior wall of the vertebral body (3.5%), the intervertebral discs (0.9%), and the vertebral joints (0.95). Of these, 16.9% were only identified in MRI, affecting the intervertebral disc exclusively, and no lesions were identified in CT only.

#### 4. Discussion

Adequate management and imaging of patients with blunt trauma to the spine, especially the cervical spine, remains controversial, despite the detrimental effects a missed unstable injury can have for patients. This uncertainty is rooted in different protocols for the primary survey of patients with potential injury to the spine, varying criteria for spinal instability, and discrepancies in study design.

Here we provide a structured analysis of cervical, thoracic, and lumbar spine injuries as determined by CT and MRI, emphasizing spinal stability, injury patterns, and discrepancies in detection rates between imaging modalities. We used a dedicated catalogue of typical findings in the setting of spinal trauma and evaluated each injured spinal segment for spinal instability as suggested in the corresponding AO classification systems, thereby providing a transparent and comprehensible overview of injury patterns in the setting of spinal trauma [18,19].

We demonstrate that supplementary MRI yields additional information in all spinal segments regarding spinal stability, most often in the cervical spine. Novel information derived from MRI changed clinical management to surgical intervention in 2.4% by revealing unstable injuries to the cervical spine that were not detected in the previous CT examination. Due to different injury patterns, supplementary MRI of the thoracolumbar spine provided only limited additional information and did not impact clinical management. MRI of the lumbar spine provided inferior detection rates of potentially unstable injuries compared to CT.

Baseline patient demographics of our study cohort, such as age, gender, injury mechanism, percentage of neurological deficits, and the average time between CT and MRI, are comparable to previously conducted studies, indicating a good transferability of our study results to larger patient cohorts [24,28–31]. In line with the current literature, detection rates of injuries to soft tissue and ligaments were superior in MRI, and detection rates of osseous lesions were generally superior in CT [32]. However, due to hospital policy, which mandates additional MRI in the case of vertebral body fractures to determine fracture age, the detection rates of acute vertebral body fractures in MRI could be overestimated in our study.

The cervical spine was the most examined spinal segment in our patient cohort, which can be attributed to its relative instability and the fact that most spinal cord injuries result from trauma to the cervical spine, resulting in a lower threshold to request imaging [33,34]. In line with the increased susceptibility to injury, there is a predominance of studies investigating the role of CT and MRI in the cervical spine compared to other spinal segments, with mixed recommendations. This study found injuries to 31.0% of structures associated with instability of the upper and subaxial cervical spine. Of these, 69.0% were only visible in subsequently performed MRI, underlining that supplementary MRI of the cervical spine will yield additional information most of the time. Similar observations were made in the subgroup of patients with neurological deficits.

In contrast, only a fraction of lesions was only visible in CT scans, both for patients with and without neurological symptoms. The number of novel lesions detected by MRI over CT is well within the range of 3.3%–54.0% reported by Malhotra et al. However, comparability is limited because we adjusted novel lesions for their association with spinal instability and performed an analysis per segment rather than a per-patient. Furthermore, we found a significantly higher rate of unstable cervical spine fractures that changed clinical management in 6 out of 165 patients (3.64%), four requiring surgical intervention, compared to 0.3% previously reported [18].

Injuries to structures associated with thoracic and lumbar spine instability were present in 12.3% and 29.9%, respectively, higher than 17.8% previously reported by Deramo et al. However, studies investigating instability of the thoracolumbar spine without evidence of a fracture are scarce, and comparability is limited due to inconsistent definitions of stability [35]. Fifty-two percent of potentially unstable injuries of the thoracic spine were visible in MRI only; this number was significantly lower for the lumbar spine, in which MRI detected only 17.7% of potentially unstable lesions, predominantly affecting the PLC and the intervertebral discs. While injury to the PLC can lead to persistent instability of the thoracolumbar spine and often requires surgical intervention in the long term, no change in clinical management resulted from supplementary MRI in the short term [36]. Therefore, MRI seems to play a subordinate role in patients without a fracture or neurological symptoms; however, it should be performed for persisting pain. These findings align with current research, which suggests that supplementary MRI does not alter the clinical course in patients with trauma to the thoracolumbar spine without neurological symptoms [35]. Furthermore, MRIs of the lumbar spine missed some potentially unstable osseous injuries detected previously in CT.

This study has certain limitations we would like to address. First, we only included patients that received CT and subsequent MRI imaging. Since, at our institution, supplementary MRI is routinely performed only for select indications, this possibly led to a pre-selection bias towards patients with previously documented injuries or persistent pain. Second, our analysis of injured structures was performed per segment rather than per patient and independent of injury mechanisms and initial clinical symptoms, somewhat detaching the analysis from the clinical context and potentially overestimating the number of injuries compared to a per-patient analysis. However, due to significant discrepancies in the assessment of spinal stability between studies, we felt this was necessary to allow and facilitate further analysis by other parties. By adhering to the recommendations of the AO classification systems regarding spinal injury and per-segment analysis, we took a step towards improved comparability between future research regarding the



integrity of spinal stability [25–27,37]. Last, the diagnostic accuracy of MRI regarding spinal instability and injuries to the PLC remains controversial, and more extensive studies are required to establish the connection more accurately between injury patterns in imaging and intraoperatively verified lesions [37,38].

In conclusion, our study provides a detailed summary of injury patterns and their detection rates in CT and MRI following blunt trauma of the cervical, thoracic, and lumbar spine. We demonstrate that, in all spine segments, MRI provides additional information regarding injury to structures associated with spinal instability. In the cervical spine, this additional information led to a change in clinical management in up to 3.6% of patients, whereas no change in clinical management was observed in patients with lesions of the thoracolumbar spine. Therefore, we suggest that supplementary MRI of the cervical spine should routinely be performed in patients that sustained blunt spinal trauma, whereas CT is sufficient for the detection of unstable injuries in the thoracolumbar spine.

## Data availability

Raw data were generated at the University Hospital Frankfurt. Derived data supporting the findings of this study are available from the corresponding author (L.D.G.) on request. No data associated with this study has deposited into a publicly available repository.

## Declaration of competing interest

The authors declare that they have no known competing financial interests or personal relationships that could have appeared to influence the work reported in this paper.

## Appendix A. Supplementary data

Supplementary data to this article can be found online at <https://doi.org/10.1016/j.heliyon.2023.e17396>.

## References

- [1] D.W. Nelson, M.J. Martin, N.D. Martin, A. Beekley, Evaluation of the risk of noncontiguous fractures of the spine in blunt trauma, *J. Trauma Acute Care Surg.* 75 (2013) 135–139, <https://doi.org/10.1097/TA.0b013e3182984a08>.
- [2] C.M. Holland, M.D. Mazur, E.F. Bisson, et al., Trends in Patient Care for Traumatic Spinal Injuries in the United States: A National Inpatient Sample Study of the Correlations with Patient Outcomes from 2001 to 2012, 2017. *Spine (Phila Pa 1976)* 42:1923–1929.
- [3] M. Reinhold, L. Audigé, K.J. Schnake, et al., AO spine injury classification system: a revision proposal for the thoracic and lumbar spine, *Eur. Spine J.* 22 (2013) 2184–2201, <https://doi.org/10.1007/s00586-013-2738-0>.
- [4] L.D. Hachem, C.S. Ahuja, M.G. Fehlings, Assessment and management of acute spinal cord injury: from point of injury to rehabilitation, *J Spinal Cord Med* 40 (2017) 665–675, <https://doi.org/10.1080/10790268.2017.1329076>.
- [5] C.J. Hauser, G. Visvikis, C. Hinrichs, et al., Prospective validation of computed tomographic screening of the thoracolumbar spine in trauma, *J. Trauma Inj. Infect. Crit. Care* 55 (2003) 228–235, <https://doi.org/10.1097/01.TA.0000076622.19246.CF>.
- [6] J.L. Antevil, M.J. Sise, D.I. Sack, et al., Spiral computed tomography for the initial evaluation of spine trauma: a new standard of care? *J. Trauma Inj. Infect. Crit. Care* 61 (2006) 382–387, <https://doi.org/10.1097/01.ta.0000226154.38852.e6>.
- [7] J.F. Holmes, R. Akkinepalli, Computed tomography versus plain radiography to screen for cervical spine injury: a meta-analysis, *J. Trauma Inj. Infect. Crit. Care* 58 (2005) 902–905, <https://doi.org/10.1097/01.TA.0000162138.36519.2A>.
- [8] S. Wesarg, M. Kirschner, M. Becker, et al., Dual-energy CT-based assessment of the trabecular bone in vertebrae, *Methods Inf. Med.* 51 (2012) 398–405, <https://doi.org/10.3414/ME11-02-0034>.
- [9] L.D. Gruenewald, V. Koch, S.S. Martin, et al., Diagnostic accuracy of quantitative dual-energy CT-based volumetric bone mineral density assessment for the prediction of osteoporosis-associated fractures, *Eur. Radiol.* (2021), <https://doi.org/10.1007/s00330-021-08323-9>.
- [10] C. Booz, J. Nöske, M.H. Albrecht, et al., Diagnostic accuracy of color-coded virtual noncalcium dual-energy CT for the assessment of bone marrow edema in sacral insufficiency fracture in comparison to MRI, *Eur. J. Radiol.* 129 (2020), 109046, <https://doi.org/10.1016/j.ejrad.2020.109046>.
- [11] L.D. Gruenewald, D.H. Leitner, V. Koch, et al., Diagnostic value of DECT-based collagen mapping for assessing the distal tibiofibular syndesmosis in patients with acute trauma, *Diagnostics* 13 (2023) 533, <https://doi.org/10.3390/diagnostics13030533>.
- [12] L.D. Gruenewald, V. Koch, I. Yel, et al., Association of phantomless dual-energy CT-based volumetric bone mineral density with the prevalence of acute insufficiency fractures of the spine, *Acad. Radiol.* (2022), <https://doi.org/10.1016/j.acra.2022.11.020>.
- [13] L.D. Gruenewald, V. Koch, S.S. Martin, et al., Diagnostic value of DECT-based colored collagen maps for the assessment of cruciate ligaments in patients with acute trauma, *Eur. Radiol.* (2023), <https://doi.org/10.1007/S00330-023-09558-4>.
- [14] C.V.R. Brown, J.L. Antevil, M.J. Sise, D.I. Sack, Spiral computed tomography for the diagnosis of cervical, thoracic, and lumbar spine fractures: its time has come, *J. Trauma Inj. Infect. Crit. Care* 58 (2005) 890–896, <https://doi.org/10.1097/01.TA.0000162149.89139.FF>.
- [15] R. Schouten, T. Albert, B.K. Kwon, The spine-injured patient: initial assessment and emergency treatment, *J. Am. Acad. Orthop. Surg.* 20 (2012) 336–346, <https://doi.org/10.5435/JAAOS-20-06-336>.
- [16] A.M. Erwood, T.J. Abel, A.J. Grossbach, et al., Acutely unstable cervical spine injury with normal CT scan findings: MRI detects ligamentous injury, *J. Clin. Neurosci.* 24 (2016) 165–167, <https://doi.org/10.1016/j.jocn.2015.09.004>.
- [17] P. Deramo, V. Agrawal, J. Amos, et al., Does MRI of the thoracolumbar spine change management in blunt trauma patients with stable thoracolumbar spinal injuries without neurologic deficits? *World J. Surg.* 41 (2017) 970–974, <https://doi.org/10.1007/s00268-016-3841-2>.
- [18] A. Malhotra, X. Wu, V.B. Kalra, et al., Utility of MRI for cervical spine clearance after blunt traumatic injury: a meta-analysis, *Eur. Radiol.* 27 (2017) 1148–1160, <https://doi.org/10.1007/s00330-016-4426-z>.
- [19] A.A. Maung, D.C. Johnson, K. Barre, et al., Cervical spine MRI in patients with negative CT: a prospective, multicenter study of the research consortium of new england centers for trauma (ReCONNECT), *J. Trauma Acute Care Surg.* 82 (2017) 263–269, <https://doi.org/10.1097/TA.0000000000001322>.
- [20] G.J. Hogan, S.E. Mirvis, K. Shanmuganathan, T.M. Scalea, Exclusion of unstable cervical spine injury in obtunded patients with blunt trauma: is MR imaging needed when multi-detector row CT findings are normal? *Radiology* 237 (2005) <https://doi.org/10.1148/radiol.2371040697>.
- [21] M.P. Labattaglia, P.A. Cameron, M. Santamaria, et al., Clinical outcomes of magnetic resonance imaging in blunt cervical trauma, *Emerg. Med. Australasia (EMA)* 19 (2007), <https://doi.org/10.1111/j.1742-6723.2007.00960.x>.

- [22] Deutsche Gesellschaft für Unfallchirurgie (DGU), 2016 S3-leitlinie polytrauma/schwerverletzten-behandlung. [https://www.awmf.org/uploads/tx\\_sleitlinien/012-019l\\_S3\\_Polytrauma\\_Schwererletzten-Behandlung\\_2017-08.pdf](https://www.awmf.org/uploads/tx_sleitlinien/012-019l_S3_Polytrauma_Schwererletzten-Behandlung_2017-08.pdf), 2016. Accessed 28 Oct 2021.
- [23] S. Qureshi, S.S. Dhall, P.A. Anderson, et al., Congress of neurological surgeons systematic review and evidence-based guidelines on the evaluation and treatment of patients with thoracolumbar spine trauma: radiological evaluation, *Neurosurgery* 84 (2019), <https://doi.org/10.1093/neuros/nyy373>.
- [24] K.B. Wood, W. Li, D.S. Lebl, A. Ploumis, Management of thoracolumbar spine fractures, *Spine J.* 14 (2014) 145–164, <https://doi.org/10.1016/j.spinee.2012.10.041>.
- [25] J.A. Canseco, G.D. Schroeder, T.M. Paziuk, et al., The subaxial cervical AO spine injury score, *Global Spine J.* (2020), <https://doi.org/10.1177/2192568220974339>.
- [26] A.R. Vaccaro, B.A. Karamian, H.A. Levy, et al., Update on upper cervical injury classifications, *Clin. Spine Surgery: A Spine Public.* 35 (2022) 249–255, <https://doi.org/10.1097/BSD.0000000000001215>.
- [27] A.R. Vaccaro, C. Oner, C.K. Kepler, et al., AOSpine thoracolumbar spine injury classification system. *Spine (phila Pa 1976)* 38:2028–2037. <https://doi.org/10.1097/BRS.0b013e3182a8a381>, 2013.
- [28] C. Schinkel, T.M. Frangen, A. Kmetz, et al., Wirbelsäulenfrakturen bei Mehrfachverletzten, *Unfallchirurg* 110 (2007), <https://doi.org/10.1007/s00113-007-1351-2>.
- [29] R.M. Hasler, A.K. Exadaktylos, O. Bouamra, et al., Epidemiology and predictors of spinal injury in adult major trauma patients: European cohort study, *Eur. Spine J.* 20 (2011), <https://doi.org/10.1007/s00586-011-1866-7>.
- [30] Y.P. Charles, J.-P. Steib, Management of thoracolumbar spine fractures with neurologic disorder, *J. Orthop. Traumatol.: Surgery & Research* 101 (2015), <https://doi.org/10.1016/j.otsr.2014.06.024>.
- [31] B.G. Chew, C. Swartz, M.R. Quigley, et al., Cervical spine clearance in the traumatically injured patient: is multidetector CT scanning sufficient alone? *J. Neurosurg. Spine* 19 (2013) <https://doi.org/10.3171/2013.8.SPINE12925>.
- [32] J.F. Holmes, S.E. Mirvis, E.A. Panacek, et al., Variability in computed tomography and magnetic resonance imaging in patients with cervical spine injuries, *J. Trauma Inj. Infect. Crit. Care* 53 (2002), <https://doi.org/10.1097/00005373-200209000-00021>.
- [33] Y. Kang, H. Ding, H. Zhou, et al., Epidemiology of worldwide spinal cord injury: a literature review, *J. Neurorestoratol.* 6 (2017), <https://doi.org/10.2147/JN.S143236>.
- [34] K. Stephan, S. Huber, S. Häberle, et al., Spinal cord injury—incidence, prognosis, and outcome: an analysis of the TraumaRegister DGU, *Spine J.* 15 (2015), <https://doi.org/10.1016/j.spinee.2015.04.041>.
- [35] P. Deramo, V. Agrawal, J. Amos, et al., Does MRI of the thoracolumbar spine change management in blunt trauma patients with stable thoracolumbar spinal injuries without neurologic deficits? *World J. Surg.* 41 (2017) 970–974, <https://doi.org/10.1007/s00268-016-3841-2>.
- [36] S. Gamanagatti, D. Rathinam, K. Rangarajan, et al., Imaging evaluation of traumatic thoracolumbar spine injuries: radiological review, *World J. Radiol.* 7 (2015) 253, <https://doi.org/10.4329/wjr.v7.i9.253>.
- [37] J.A. Rihn, C. Fisher, J. Harrop, et al., Assessment of the posterior ligamentous complex following acute cervical spine trauma, *J. Bone and Joint Surgery-Am.* 92 (2010), <https://doi.org/10.2106/JBJS.H.01596>.
- [38] H.M. Ackland, P.A. Cameron, D.K. Varma, et al., Cervical spine magnetic resonance imaging in alert, neurologically intact trauma patients with persistent midline tenderness and negative computed tomography results, *Ann. Emerg. Med.* 58 (2011), <https://doi.org/10.1016/j.annemergmed.2011.06.008>.