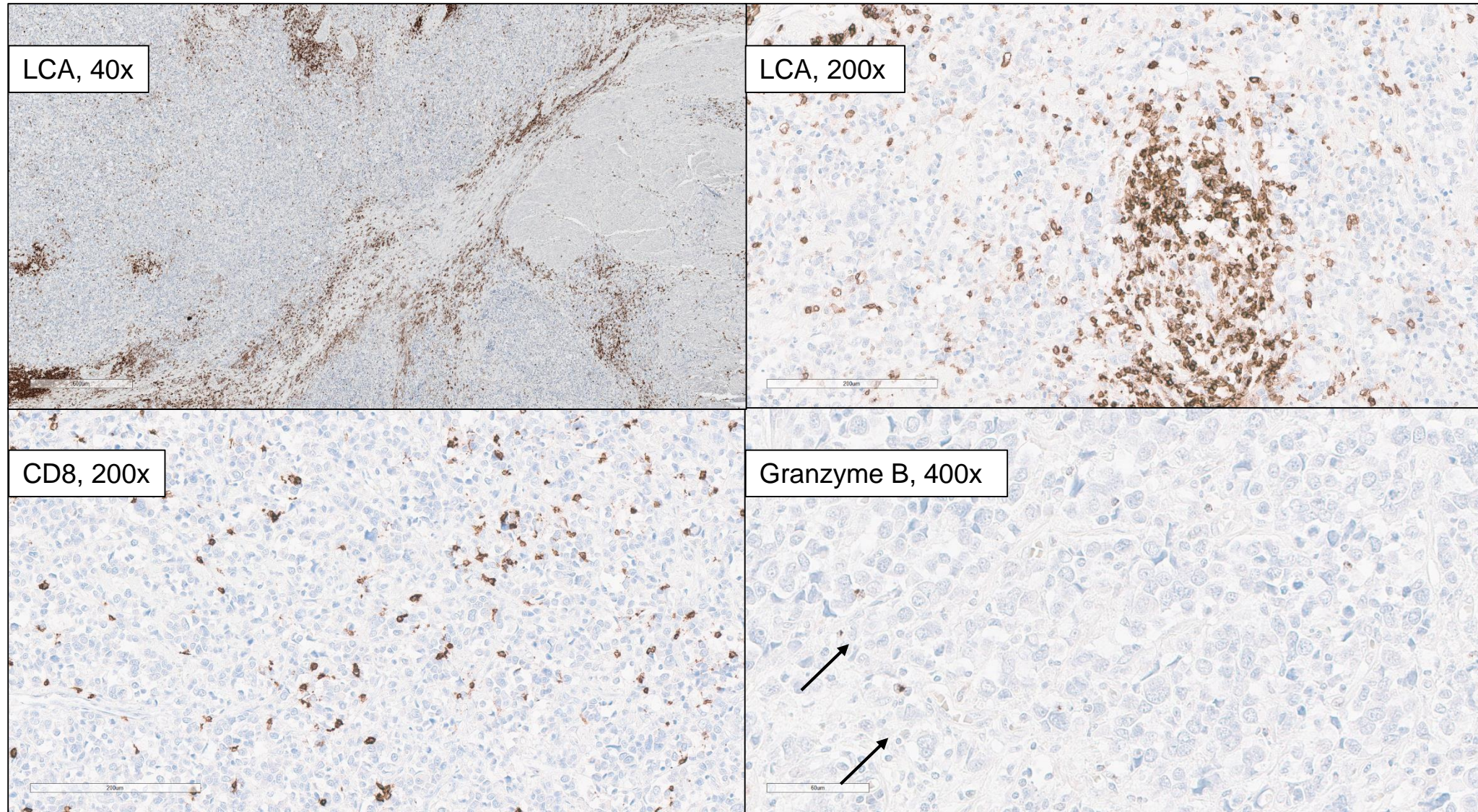


**Figure S2**



**Figure S2: Microphotographs of the immunostainings.**

Top row: LCA (leucocyte common antigen (CD45) in 40x and 200x magnification. Immune cells are accentuated at the tumor periphery, but also in the tumor itself; CD8-positive cells are less often detected and for the detection of granzyme B positive cells, the algorithm had to be adjusted due to small granular cell positivity. This needs a well performed immunohistochemical process, as artifacts would have hindered correct detection.