

American Journal of Physical Anthropology

VOLUME IV

JANUARY-MARCH, 1921

NUMBER 1

AGE CHANGES IN THE PUBIC BONE¹

T. WINGATE TODD

Anatomical Laboratory, Western Reserve University, Cleveland, Ohio

CONTENTS

II. THE PUBIS OF THE MALE NEGRO-WHITE HYBRID.....	1
III. THE PUBIS OF THE WHITE FEMALE.....	26
IV. THE PUBIS OF THE FEMALE NEGRO-WHITE HYBRID.....	40

II. AGE CHANGES IN THE PUBIC BONE OF THE MALE NEGRO-WHITE HYBRID

INTRODUCTION—THE MALE WHITE OS PUBIS

In the first contribution to this subject (7) I discussed at some length the age changes occurring in the pubic bone of the male White after the eighteenth year. In that communication I explained that individuals of one human stock and sex were taken in order to obtain, so far as possible, a standard by which comparisons could be made with other stocks, with the female sex, and with Primates in general. The observations showed that there is a definite metamorphosis going on in the pubic bone throughout life, and that this metamorphosis has a fairly precise age-relationship which I summarized in the following manner:

Age 18-19. Phase 1:—Typical adolescent ridge and furrow formation with no sign of margins and no ventral bevelling.

¹For Part I see No. 3, Vol. III, of this Journal.

Age 20-21. Phase 2:—Foreshadowing of ventral bevelling with slight indication of dorsal margin.

Age 22-24. Phase 3:—Progressive obliteration of ridge and furrow system with increasing definition of dorsal margin and commencement of ventral rarefaction (bevelling).

Age 25-26. Phase 4:—Completion of definite dorsal margin, rapid increase of ventral rarefaction and commencing delimitation of lower extremity.

Age 27-30. Phase 5:—Commencing formation of upper extremity with increasing definition of lower extremity and possibly sporadic attempts at formation of ventral rampart.

Age 30-35. Phase 6:—Development and practical completion of ventral rampart with increasing definition of extremities.

Age 35-39. Phase 7:—Changes in symphyisial face and ventral aspect of pubis consequent upon diminishing activity, accompanied by bony outgrowths into pelvic attachments of tendons and ligaments.

Age 39-44. Phase 8:—Smoothness and inactivity of symphyisial face and ventral aspect of pubis. Oval outline and extremities clearly defined but no "rim" formation or lipping.

Age 45-50. Phase 9:—Development of "rim" on symphyisial face with lipping of dorsal and ventral margins.

Age 50 and upwards. Phase 10:—Erosion of and erratic, possibly pathological osteophytic growth on symphyisial face with breaking down of ventral margin.

It has also been shown that the age-relationship of the metamorphosis is affected by local anomalies in the pubic bone, by certain diseases or rather by the disorganization of the functions of certain glands and to a smaller extent by undetermined individual factors. In occasional cases the metamorphosis remains incomplete throughout life as regards the ventral margin and upper extremity of the symphyisial face. Whereas there is usually practical harmony in the age relationships of various parts of the skeleton, occasionally the stage of bone-change in the os pubis is at variance with that of other bones. The symphyisial face has practically reached its adult dimensions at puberty so far as the cartilages go but the bony dimensions cannot be accurately measured until phase 6 is completed which occurs at about the age of thirty-five. After the age of eighteen

there is practically no actual growth of bone at the symphysis and certainly none after the twenty-first year.

In the ensuing pages it will be taken for granted that the reader is conversant with the features of the male White os pubis. I shall therefore proceed immediately to a discussion of the bone in the male Negroid without repeating all the details previously given.

THE OS PUBIS OF THE NEGRO-WHITE HYBRID MALE
TYPICAL METAMORPHOSIS

There is no large series available of pure African material or indeed of any other non-White stock with accurate information as regards age. Hence we are driven to use American Negro-White hybrid material for comparison with the observations upon the male White skeleton. Actually this is not of practical disadvantage because the differences between the White and Negro stocks are sufficiently marked to be picked out even in hybrid material. As evidence of this fact the recent papers by Schultz upon the external nose in Whites and Negro-White hybrids may be cited (5, 6). Furthermore, in the course of present studies one is convinced that the negroid type of pelvis is retained in the hybrid population. Since then in morphological features the Negro-hybrid pelvis is distinctly negroid one must expect that the features of growth and metamorphosis of the pelvic bones will also bear testimony to the negroid origin.

The material used in the present study includes quite varied racial admixtures from the very dark to the quadroon. Samples of the skin of most are retained in the laboratory but the relation of these samples to Davenport's color mixtures (3) gives us no help in the present connection. It is noticeable that the various skeletal features do not go hand in hand with the colorimetric values of the skin. During the influx of Negroes from the south which has taken place in the past few years we have noticed that the southern Negro-hybrid is more distinctively negroid in external features than that of the north. From a consideration of all these factors one might anticipate in the American Negro-hybrid a greater or more erratic individual deviation from the typical age-relationship, always presupposing that there is an age-relationship typical for the Negro and differing from the standard established for the White. In the following pages we

shall see what relation such a hypothesis has to actual fact.

Our Negro-hybrid male material of known age comprises ninety pelves the majority of which, it will be observed, lies between the ages of seventeen and forty-five. Reference to Fig. 2 discloses the fact that the numbers are fairly evenly distributed along this age period and the polygon is devoid of the striking upward leaps which characterize the polygon of ages of the male White material. We have therefore little inherent suggestion that there may be gross errors in the age records.

As illustrative of the condition of the pubic bone soon after puberty we take pelves Nos. 519, 695 and 721 of ages seventeen, eighteen and eighteen respectively (Figs. 3, 4). In all the iliac and ischial epiphyses are in process of uniting with the main mass of the bone; in No. 519 alone the epiphysis for the anterior inferior spine is still incompletely united on both sides.

The symphyseal face of each exhibits the characteristic horizontal ridges and furrows, a little less pronounced perhaps in No. 721 than in the others. The greater relative massiveness of the upper ridges noted in the male White is not apparent here. In all the rugged symphyseal face extends to include the pubic tubercle and no ossified epiphyses occur. As in the male White there is no indication of a dorsal delimiting margin although the symphyseal face is sharply marked off from the dorsal and ventral aspects of the pubis by an abrupt change in surface appearance and bony texture. A similar though less abrupt change differentiates the symphyseal face from the upper aspect of the pubis whereas the lower part of the face merges gradually into the more smoothly textured inferior pubic ramus. It is apparent then that there is no striking racial difference between the Negro-hybrid and the White in the immediate post-adolescent features of the pubic symphysis (Phase I).

In No. 693 (age eighteen) and Nos. 17 and 588 (age nineteen) (Figs. 5, 6) the ischial epiphyses are united except at their ramal portion, though the iliac epiphyses show no more complete union than in the last group. The symphyseal faces of these are as already described, except that in Nos. 693 and 588 the pubic tubercle is completed and this without the assistance of an ossified epiphysis.

We have then among this material six specimens between the ages of seventeen and nineteen which display characters precisely similar

to those of the White male material of the same ages except that the ridges are of the same approximate dimensions throughout the symphyseal face.

First post-adolescent phase. Age 17-19:—Symphyseal surface rugged, traversed by horizontal ridges separated by well-marked grooves. No ossific (epiphyseal) nodules fusing with the surface. No definite delimiting margin. No definition of extremities.

Skeletons 639 and 808 each of age twenty years, and 698 and 413 each of age twenty-two (Figs. 7, 8, 9) show features noted in the male White series as characteristic of the second post-adolescent phase. Both iliac and ischial epiphyses are united fully in all save 413, but Nos. 639 and 808 still exhibit plainly the junction lines of these epiphyses. This clear indication of the recent fusion remains for a short time only and is already invisible in No. 698. No. 413 shows incomplete union of the iliac epiphyses and non-union as yet of the ramal portions of the ischial epiphyses. In all these specimens a ridge appears linking up the hinder ends of the horizontal ridges and the grooves adjacent to this dorsal delimiting ridge are filling up with finely textured bone. The other notable feature is the beginning of the break-down of the ventral region of the surface to bring about the characteristic bevelling which will be so obvious in the next group.

As with the members of the same phase in the male White series the occurrence of bony epiphyseal nodules is apparent at this stage. They are present already fused on both sides of No. 413. In these examples as in the previous series there is no difference in size between the upper and lower horizontal ridges.

This phase in the Negro-hybrid occurs at the same age as in the male White and is characterized by the same general features which may be presented in brief in the following manner.

Second post-adolescent phase. Age 20-22:—Symphyseal surface still rugged, traversed by subequal horizontal ridges, the grooves between which are becoming filled near the dorsal limit, however, with a new formation of finely textured bone which begins to obscure the hinder extremities even of the horizontal ridges themselves. Dorsal delimiting margin begins to develop. Early ventral bevelling. Occurrence of a bony (epiphyseal) nodule at the upper extremity of

the symphyseal face in some cases. No delimitation of extremities as yet.

As in the case of the White the next stage in development of the pubis is practically an intensified continuation of the processes already foreshadowed in the last. Nos. 366 and 703 of age twenty-two, 506 of age twenty-three, and 497 of age twenty-four fall into this group (Figs. 10, 11). The horizontal ridges and furrows are still more or less evident although the hinder extremities of the latter are well filled by the new bone formation. The dorsal margin and adjoining platform are quite apparent. In all except 497 the upper bony nodule is present although varying greatly in size. But the striking feature is the ventral bevelling. There is no indication as yet of the lower extremity. In all these examples except 506 the horizontal ridges probably have never been very strongly marked. We may define the stage thus:

Third phase. Age 22-24:—Symphyseal face shows progressive obliteration of horizontal ridges and furrows. Commencing formation of the dorsal platform or plateau. Occurrence of fusing bony (epiphysial) nodules. Dorsal margin becoming more defined. Ventral bevelling from rarefaction strongly marked. No delimitation of extremities.

Phase IV is very inadequately represented in the collection so far for the only example referable to this stage is No. 524 of age twenty-four (Fig. 12). The outstanding feature of the phase is the development of the lower extremity which in the specimen is in its early beginning. The dorsal margin is however complete and the dorsal platform extends about one-third of the distance to the ventral limit of the surface. The ventral bevelling is very well marked. The most notable feature of this specimen however cannot be seen on the illustration. On both sides the epiphysial line can be traced from the ramal extension of the ischial epiphysis into the lower extremity of the symphyseal face which therefore would seem to be a direct continuation of the ischial epiphysis. This is still better marked in two specimens to be described later, namely, Nos. 792 and 744. The continuation however is more apparent than real for the ramal epiphysis stops at the narrowed portion of the pubis immediately below the lower extremity of the symphyseal face. That the ventral rampart and the upper nodule represent ossification in the morphological

plane of the ischial epiphysis is undoubtedly true and the tissue in which they all develop is the strip of connective tissue along the ventral and inferior margin of pubis and ischium. The present is not a suitable stage of the discussion for commenting upon the morphological significance of this relationship which will be dealt with in a later communication.

The outstanding features of the phase may however be stated.

In the time relationship the ages to be given for this phase are twenty-five and twenty-six. Since our single specimen shows only the very commencement of the lower extremity at twenty-four and already at twenty-seven the next phase is well under way there is not in the male Negro-hybrid series sufficient evidence to suggest that the age relationship of phase IV differs in the Negro-hybrid from that presented by the male White in which this phase corresponded to the twenty-fifth and twenty-sixth years of age.

Phase four. Age 25-26:—Ventral bevelled area greatly increased. Corresponding diminution of ridge and furrow formation. Complete definition of dorsal margin and increase of dorsal platform. Appearance of lower extremity.

Again as in the male Whites formation of the upper extremity follows rapidly upon that of the lower and into this formation an upper bony nodule may or may not enter. The examples presented by this collection are Nos. 379 and 802 of age twenty-seven, 658 of age twenty-eight, and 402 of age twenty-nine (Figs. 13, 14). In 802 and 658 the lower extremity is not very clearly defined and the upper extremity is beginning to be formed with the assistance of an epiphysial nodule. In 379 and 402 the lower extremity is much better defined but the upper is in much the same condition as in the other two although the bony nodule is very insignificant or altogether absent. The ventral bevelling is well developed and there is no sporadic attempt at formation of a ventral rampart except in 802. We therefore group these in the following manner.

Fifth phase. Age 27-29:—Little or no change in symphyseal face except for occasional attempts at formation of ventral rampart. Increasing definition of lower extremity and dorsal margin. Commencing formation of upper extremity with or without the intervention of an epiphysial nodule.

There are twelve typical specimens (Figs. 15-19) belonging to

the next stage of development the characteristic feature of which is the formation and completion or approximate completion of the ventral rampart by which the classic oval outline of the symphyseal face is brought about. These specimens are, Nos. 259, 563, 568 and 569 of age twenty-nine; Nos. 343, 435 and 598 of age thirty; No. 486 of age thirty-two; Nos. 290 and 596 of age thirty-three; No. 677 of age thirty-four; No. 451 of age thirty-five.

As in the case of the male Whites age discrimination becomes somewhat more difficult from this period on for we are dealing with relatively minor details. The same general considerations also hold. The individuality of the upper osseous nodule becomes merged into the main mass of bone and the speed of formation of the upper extremity varies greatly; indeed it may not be completed. The same is true of the ventral rampart so that, when a hiatus does occur it usually lies in the upper third of the ventral margin. In some specimens the lower extremity is well defined before the ventral rampart is completed, in others the reverse is the case. One must therefore carefully weigh the evidence submitted by both the lower extremity and the ventral rampart before deciding upon the age indication. In all the examples of age twenty-nine the formation of the ventral rampart has progressed apace whereas the definition of the lower extremity has lagged to some extent. Especially is this true of No. 568.

All the other specimens show a more regular arrangement with the lower extremity becoming progressively well defined in advance of the growing ventral rampart. There is perhaps even some slight retardation in No. 486. In all the pelves however the vertical and antero-posterior diameters of the symphyseal face can be stated with assurance. These measurements could not be given with the same exactitude in previous series.

The building up of the ventral rampart occurs in the same manner as in the male White, namely either by the linkage of independent bony nodules with the upper and lower extremities or by the gradual throwing up of a continuous narrow mound of bone on the greatly rarefied ventral strip. In either case the rarefied bone remains without change on both symphyseal and ventral sides of the rampart and in this respect the ventral margin differs absolutely from the dorsal which carries with it the formation of the dorsal platform.

At this stage as in the White pelvis there is no lipping of the symphyseal margins such as one meets with in older bones.

Nos. 677 and 451 fall rather outside the limits of the group for the Negro-hybrid. This becomes more evident in consideration of the ensuing series. They were originally picked out as showing a very early stage of retardation on account of the slight waxy appearance of the symphyseal face. This with the relatively incomplete ventral rampart (compared with the clear definition of extremities already formed) and margins indicate retardation in small degree.

We may now proceed to state the features of the sixth phase which runs its course apparently somewhat more quickly in the Negro-hybrid than in the White.

Sixth phase. Age 30-33:—Increasing definition of extremities. Formation and practical completion of ventral rampart. Retention of granular or rarefied appearance in symphyseal and ventral aspects of os pubis. Absence of lipping of symphyseal margins.

The seventh phase in the Negro-hybrid starts a little earlier than in the White but likewise continues to a rather uncertain upper limit which, for the sake of definition, we may arbitrarily set as in the case of the White at thirty-nine years. From the evidence presented by the entire Reserve material I feel sure that this date is a very close approximation and the only hesitation which I have in fixing it is due to the fact that about this time certain quasi-pathological appearances may supervene which obscure the typical features somewhat. The specimens falling into this group are (Figs. 20-23), Nos. 638, 705, 709, of age thirty-three; Nos. 74, 475, 594, 606, 664 of age thirty-five; Nos. 225, 416, 538 of age thirty-eight; No. 646 of age forty.

Of these Nos. 538 and 664 possibly show a little retardation but not enough to make them conspicuous. The outstanding feature of all is the rapid disappearance of the granular texture of the ventral aspect and the more gradual disappearance of the granular texture of the symphyseal face, the bone tissue in both places becoming more dense and giving the impression of quiescence. In this stage as in the male White a well marked lipping occurs in the ischium at the site of attachment of the sacro-tuberous ligament but the greater prominence of this ridge of bone in earlier phases in the Negro-hybrid than in the White must not be mistaken for lipping which is quite a

distinct feature to be more fully discussed when the general age changes of the pelvis are considered.

In the later years of this period there appears the first beginning of the formation of a "rim" around the entire symphyseal face giving to it a raised edge even before all sign of activity (i. e. granularity) has disappeared from the surface. This is one respect in which the Negro-hybrid differs from the White. Another is that in the specimens now at hand in the collection the ventral rampart is always complete during this stage. To conclude that completion always occurs in the White would be to imply that secondary erosion may take place even before the fortieth year which is not in accordance with the facts. It may be that we shall eventually meet with Negro-hybrid cases in which the rampart never is completed. In any case the distinction is not of very great significance at present.

The bony outgrowth into the attachment of the gracilis tendon occurring in the same stage of the White is present here also but is not so striking.

By the end of the period the symphyseal extremities are well defined. No lipping of the margin occurs however until the succeeding phase.

The characters of the pubis at this stage are the following:

Seventh phase. Age 33-38:—Increasing smoothness of symphyseal face and ventral surface consequent upon diminishing activity. Attempt at formation of a raised edge or "rim" to the entire margin. Completion of the ventral rampart if not already completed in the last phase. Commencing bony outgrowth into attachments of tendons and ligaments, especially the gracilis tendon and the sacro-tuberous ligament.

The three succeeding phases tend to dovetail as in the White and cannot be so clearly separated as the foregoing while the specific features of these phases no longer permit the fine age discrimination for which the earlier phases advanced such important information. Certain minor differences, moreover, are to be observed between the Negro-hybrid and White pelvis both in morphological features and in age relationship. Attention must be drawn to these during the discussion.

We therefore take up the consideration of a group of pelvis the characteristic feature of which is the smoothness of the symphyseal

and ventral aspects due to inactivity (Figs. 24, 25). These are: Nos. 434, 580, 722 of age forty; Nos. 558, 803 of age forty-one; No. 729 of age forty-five; No. 725 of age forty-seven; No. 441 of age forty-nine; No. 697 of age fifty.

The earlier members of the series are perhaps not very clearly marked off from those of the foregoing group. The criterion used in differentiation is not so much absolute smoothness and inactivity as a certain waxy appearance very difficult to describe but quite appreciable on inspection which characterizes an inactive symphyseal surface. It is important to note that there is no further development of the "rim" around the symphyseal margin beyond that already attained in the previous phase. In two features this series differs from the os pubis of the White male at the same age. In the first place there is commencing lipping of the dorsal margin which is readily palpable and depends not upon the age so much as the condition of the symphysis, being rather more marked in the smoother examples. It is however less marked than in the following phase. The second difference is seen in Nos. 558, 803 and to a less extent in No. 697. This is a small punched out excavation on the ventral aspect adjacent to the ventral margin of the symphyseal face at the junction of upper and middle thirds. It is clearly the forerunner of the ventral erosion which becomes a marked feature of the succeeding group.

As in the White the linear prominence on the ventral aspect for attachment of the gracilis muscle and noted by Cleland as "the limit of attachment of the femoral muscles" (2) is well defined at this stage.

Regarding the last three members of this series there may be some legitimate doubt in the mind of the reader as to whether the age record is really correct. It is necessary therefore to state briefly the reasons which convince me that they are properly included in this study.

No. 725 by the record of his birth was forty-seven years, eight months and two days old at the date of death. The fact that he was a case of mitral regurgitation is worthy of record for we have other cases of mitral disease in which there are indications of accelerated metamorphosis and especially of lipping of various bones which, it might be suggested, have some connection with a rheumatic factor. There is no real evidence for this view in the entire collection and

any possibility of such an impression must be corrected at once. The lipping of the long bones, vertebræ and ribs, the wear of the teeth and the condition of the cranial sutures all conform to the recorded age or a little less.

In No. 441 the inferences to be drawn from the bones mentioned in connection with No. 725 are all in accordance with an age of forty-five or a little more. Since the recorded age is forty-nine the possibility of retardation is not worthy of consideration in this case any more than in the last.

The most striking and at the same time the most significant feature of No. 697 is the commencement of a peculiar cinder-like texture and feel to the vertebræ and ribs. This we have learned to associate with skeletons of fifty years and over. Fifty is the recorded age of the specimen. With this the wear of the teeth accords well. The only feature of the skeleton failing to conform to the stated age is the condition of the cranial sutures which are wildly aberrant in their age relationship indicating certainly not more than twenty-five years. The erratic nature of cranial suture closure has been noted already in the first part of this memoir and it must not be allowed to confuse the very definite age indications of the rest of the skeleton.

For the reasons just enumerated therefore we conclude that skeletons 441, 697 and 725 possess a normal age relationship although we may allow that the symphysis itself may present some indications of retardation which can only be properly adjudged by further experience.

From the age frequency of the series it is apparent that we must give the same approximate limits for phase VIII as were given in the case of the White.

Eighth phase. Age 39-45:—Symphysial face generally smooth and inactive. Ventral surface of pubis also smooth and inactive with the exceptions noted above. Extremities clearly defined. No increasing distinctiveness of "rim" of symphysial face beyond that attained in the foregoing phase. Some lipping of dorsal but none of ventral border.

The characteristic feature of phase IX in the male White collection is the appearance and development of a marginal raised edge or "rim" to the symphysial face and during this phase also some lipping of both dorsal and ventral margins takes place. Among our Negro-hybrid males the "rim" formation never proceeds very far and occurs more

erratically as also does the lipping of the dorsal margin. Consequently we cannot clearly differentiate the ninth phase from the eighth on the one hand and from the tenth on the other. Another difference found in the Negro-hybrid is the earlier appearance of secondary erosions. Consequently it is necessary to omit the ninth phase from the category of the Negro-hybrid.

The remaining Negro-hybrid male pelves are referred to the tenth phase the distinguishing feature of which is secondary erosion. The pelves (Figs. 26-32) falling into this group are: Nos. 27, 426, 540, 553, of age forty-five; No. 574 of age forty-six; Nos. 31, 498, 725 of age forty-seven; Nos. 198, 699 of age forty-eight; No. 97 of age fifty; No. 192 of age fifty-one; No. 692 of age fifty-three; No. 433 of age fifty-five; No. 400 of age fifty-six; Nos. 79, 430 of age fifty-seven; No. 327 of age fifty-nine; No. 522 of age sixty-seven; No. 511 of age sixty-nine; No. 399 of age seventy; No. 422 of age seventy-six.

It will be noted that all the pelves in the collection beyond the age of forty-five fall into this group with the exception of three which are referred to phase VIII, namely Nos. 441, 697 and 725. These three are possible examples of retardation of bone metamorphosis. The earliest age at which phase X appears among the male Whites is forty-four as an anomaly. From the age of forty-eight it begins to appear more frequently but not till considerably after fifty does it become anything like general. In the Negro-hybrid collection, on the contrary, it first appears as an anomaly at thirty-nine and becomes almost constant after forty-five. It may be that the relatively small number of Negro-hybrids accounts for this but there are other indications noted here and there throughout this communication which indicate a general speeding up in the later phases of bone metamorphosis in the Negro-hybrid so far as the os pubis is concerned. It will be remembered that upon the basis of the male White alone it was impossible to deny absolutely a pathological factor in the rarefaction and erosion of phase X inasmuch as they frequently occurred in association with irregular ossifications and other plainly pathological features. The Negro-hybrid collection is wonderfully free from such pathological features and I feel therefore confirmed in my impression that both general rarefaction and local erosion are genuine age changes, non-pathological in type, as indeed I have hinted in my former communication.

These Negro-hybrids fall into three categories according to the

manner in which phase X supervenes. In pelves 27, 31, 422, 426, 498, 540, 553 it is the ventral erosion which is the significant feature. In all of these, although there may be some rarefaction of the symphyseal face most pronounced near the ventral margin, there is an erosion at the junction of upper and middle thirds of the ventral margin itself through which the rarefying process clearly proceeded.

In pelves 79, 192, 327, 399, 400, 483, 511, 522, 574, 692, 699 no such ventral erosion occurs but the symphyseal surface is rarefied to a greater or less extent mainly towards the *dorsal* margin. This peculiarity sharply indentifies the condition from a late phase VII in which the remaining activity is related more to the ventral margin. In pelves 97, 198, 430 both ventral erosion and surface rarefaction occur in about equal extent and it is not possible to decide which appeared first. Observe that these are not the oldest bones; ventral erosion and surface rarefaction are both variant types of the same phase and neither shows a special age frequency within the phase. Among the male Whites there seems to be a possible preference for the ventral erosion type of commencement in those symphyses the rampart of which has never completely formed. As the ventral rampart is apparently always completely formed in Negro-hybrids there is no evidence to be obtained from them upon this point.

The moniliform lipping characteristic of the ventral margin during this phase in Whites also occurs in the Negro-hybrid and needs no further description. The "rim" formation is not more than rudimentary even in quite senile bones. In No. 97 alone is there any question of possible pathological appearance of the symphyseal face and No. 198 is the only one in which the ventral lipping has proceeded to a bizarre and pathological extent. Dorsal lipping is no different from that found among the male Whites and as in them is scarcely related so much to age as to the phase.

We may therefore summarize the foregoing characteristic features in the following manner:

Tenth phase. Age 45 and upward:—Symphyseal face showing rarefaction of a non-pathological nature. Ventral border more or less eroded. Increased lipping of dorsal and ventral margins. No more clear definition of "rim" than in previous phases. Occasional pathological disfigurement.

INDIVIDUAL DEVIATIONS IN AGE RELATIONSHIP

Local retardation.—In the discussion of phase VIII we noted three skeletons, namely 441, 697 and 725, which demonstrated the possibility of retention of the essential features of this phase for five years at least after its usual termination. It was suggested there that further research might definitely establish these skeletons as examples of retardation in bone metamorphosis localized to the os pubis alone.

Local acceleration.—We find also three specimens in the male Negro-hybrid collection which upon observation of the pubic bone only, would be estimated as of greater than their real age since the features of the symphysis are undoubtedly those characteristic of phase X. The skeletons are Nos. 515, 682 and 736. It will be well therefore to examine these more fully, taking them in their actual age sequence.

No. 682 (Fig. 33) from a case of mitral stenosis aged thirty-nine, possesses pubic bones the symphyseal faces of which are distinctly eroded at the junction of the upper and middle thirds of the ventral margin. Of this erosion the sharp-edged pits are characteristic. The ventral surfaces of the bones display a waxy deposit of new bone transversely striated by the passage of abnormal blood vessels indicating chronic inflammation. Some lipping of the long bones, the vertebræ and the ribs other than the first pair together with the wear of the teeth and the state of the cranial sutures all bespeak the recorded age. There are no "rheumatoid" features. It is only the os pubis with its pathologically thickened and "bearded" ventral aspect which fails to accord with the stated age. Quite possibly the chronic inflammatory focus has stimulated the early occurrence of breakdown in the ventral symphyseal margin. The tendency to disintegration being a feature of the normal bone it is but natural that erosion should be accelerated by the pathological factor. This specimen and No. 198 already mentioned (p. 14) are however the only examples among the Negro-hybrid males in which a pathological origin for the ventral erosion might be invoked.

We pass on then to the consideration of two specimens displaying uncomplicated age changes. The first of these, No. 515 of age forty (Fig. 34), shows features in its long bones, vertebræ, ribs, cranial sutures and in the wear of its teeth typical of the recorded age. Commencing erosion at the junction of upper and middle thirds of the

ventral symphyseal margin signifies therefore an undoubted acceleration of pubic metamorphosis for which there is at present no adequate explanation.

No. 736 (Fig. 35) like the foregoing is of age forty and again the lipping of long bones, vertebræ and ribs accords with the stated age. The condition of the cranial sutures, the wear of the teeth and the external features of the cadaver point to age forty as a probable maximum. There is however in this skeleton undoubted osteo-arthritis of the knee and elbow joints. In the pubis the ventral symphyseal margin and the ventral third of the symphyseal face show typical erosion.

The conclusion to which one tends from a study of these three specimens is that acceleration has occurred locally in the metamorphosis of the pubic bone from some unknown cause not affecting the remainder of the skeleton. One may also add that pathological factors, which are by no means always or necessarily present, appear to have the power of assisting in this acceleration since it is a process of disintegration. The conclusion here drawn can only be justified however by a more extended survey of our material.

In discussing the great mass of skeletons upon which this memoir is based it is impossible to deal in detail with every specimen. Nor is this necessary for the collection is a permanent one and the observations now recorded can be readily checked over. In the consideration of the male White skeletons therefore I have been most concerned to establish the principles of pubic metamorphosis. At that stage the full presentation of the evidence upon anomalous age relationships could only have served to befog the real purpose of the paper. Now that these principles are clearly before the reader and are confirmed by the collection of male Negro-hybrids we can proceed to a discussion of individual deviations from the typical age relations of the pubic bone change as observed in Negro-hybrids.

In the pages immediately preceding we have noted the occurrence of individuals in the second half of life displaying either a possible retardation on the one hand or a definite acceleration on the other in metamorphosis of the pubic bone unaccompanied by parallel changes in the remainder of the skeleton. To develop the argument in favor of this assertion we must examine the material further in search for other examples of like conditions.

In the male Negro-hybrid material no other cases of retardation restricted to the pubic bone have so far presented themselves but there are three other instances of undoubted localized acceleration. These shall be discussed in order of age.

No. 744 of age twenty-two shows excellently an acceleration of metamorphosis at the pubic symphysis and as a feature of this the typical formation of the ventral rampart. No epiphysial lines remain upon this specimen which is from a man who died of pulmonary tuberculosis and whose skeleton in all other respects is characteristic of age twenty-two. Note that in this example (Fig. 36) the dorsal delimiting margin is beginning to appear and the adjacent parts of the grooves to become filled with a deposit of new bone. The specimen itself, when carefully examined under the newly-formed ventral rampart, shows rarefaction of the ventral part of the symphyseal face rather more advanced than one usually finds at this age. The upper part of the surface is covered by a recently united mass of bone, undoubtedly an ossified epiphysial nodule which strongly resembles that in No. 413 (Fig. 9). These features are all characteristic of the latter part of phase two, but in addition there is the appearance of a completely formed and partially fused ventral rampart and lower extremity which have united into one piece with the upper nodule now transformed into an upper extremity. Apparently then the specimen has reached the end of the sixth phase and is, in its bone age, about thirty-three. A second glance however disposes of such an interpretation for the dorsal margin is scarcely more than started and the dorsal platform is visible nowhere. The features with the exception of the anomalous ventral rampart and extremities are all those of age twenty-two. From some cause at present unknown the growth of the ventral rampart has taken place unusually early. No. 744 is one of the rather rare instances in which there is an anomaly in age-relationship of bone change quite local in its occurrence.

There is another suggestion which the condition of No. 744 brings forcibly to mind, namely that possibly formation of the ventral rampart always or usually occurs at a quite early age and that in consequence of its not uniting until much later it is lost in maceration. It will be recalled that Aeby claimed the loss of the finer structural relations of the symphysis in maceration (1). Aeby's statement does not refer however to such features as this. Against the suspicion

also must be quoted the fact that for more than seven years we have been preparing these bones with the utmost care, always on the lookout for epiphyses and separate masses of bone not yet described, that we have discovered such in other parts of the skeleton the discussion of which is not relevant here, but that we have never found at the symphysis any ununited mass of bone save that, which becomes the nodule of the upper face rapidly fusing with the face itself. The actual formation of the ventral rampart and extremities, moreover, is of a nature to preclude the loss of portions, since they grow up from the underlying bone and are only partially separated therefrom. The next anomalous specimen to be described in fact, while exhibiting the same end-result, shows a very different manner of ossification.

No. 190 of age twenty-six displays a symphyseal face of which the ventral rampart is almost complete and the extremities well defined (Fig. 37). It belongs to the latter part of phase VI. The clavicular epiphyses are not however completely fused. This fact together with the absence of epiphyseal lines on vertebræ and ribs indicates pretty clearly that the recorded age is correct. The ischia act also as an important check upon the age. It is true that the teeth are somewhat worn and that the sutures of the cranium would indicate more than forty, nevertheless this evidence cannot contradict the very definite indications of the rest of the skeleton.

No. 93 (Fig. 38) is likewise anomalous in the age relationship of the os pubis alone. It is possible that the anomalous shape of the symphyseal outline may be related to this. The stated age is thirty and whereas the teeth and clavicles suggest somewhat less than this the sutures, long bones, vertebræ, ribs and even the ischia indicate rather more. Upon general skeletal considerations we should say that the recorded age is confirmed. The ventral rampart and extremities of the symphysis are however completed and the pubis must be referred to phase VII. This acceleration of pubis alone may be related to its anomalous shape since other instances of similar anomalies in the male White series, especially the short type No. 94 (Fig. 59, Part I), exhibit acceleration.

General skeletal retardation.—Attention has already been drawn, during the discussion of the male White pelvis, to the fact that anomalies in age relationship may not be localized to the os pubis alone. Cases in which the entire skeleton is involved may have a possible

causation more definitely suggested but as a rule they are more apt to cause confusion and uncertainty regarding the correctness of the records. Indeed were it not for the elaborate way in which the records are checked and the very precise information which is available in a considerable number of cases in the total collection one would have greater hesitation in presenting the evidence now to be set forth.

The first case to be considered is No. 523 (Fig. 39) the skeleton of an individual, twenty-four years of age, showing some five years' retardation in bony metamorphosis. No gross lesion was observed which might be invoked as influencing the rate of bony change. The condition is then one of unknown origin. In this specimen the iliac epiphyses are almost completely united and the ischial epiphyses are united except for their ramal portions which are still entirely free. No other epiphyses are apparent. The pubic bone presents features characteristic of the first phase but there is a suggestion of the beginning of a dorsal delimiting margin and of the filling up of the hinder extremities of the horizontal grooves by new bone formation. The pubic tubercle is completed and there is not the faintest indication of ventral bevelling. Clearly then the stage of bone formation is the latter part of the first phase and the bone age of the individual is about nineteen years. The other parts of the skeleton justify this conclusion. Turning to the records we find that the age given is twenty-four and the family data are so complete that we know his actual age to be twenty-four years and four days. The case is one of minor delay in bony metamorphosis but there is no evidence in the skeleton either that actual inhibition had occurred or that a prolonged stationary period had been entered upon.

No. 474 is an interesting example of retardation. The stated age of this individual who died from pulmonary tuberculosis is twenty-eight. The clavicular epiphyses are not completely ossified. The epiphyses on the auricular surfaces of the sacrum and those of the sacral attachment of the sacro-tuberous ligaments are incompletely united. All other epiphyses are entirely fused. From these findings one would give the skeletal age as about twenty-five or somewhat less. Reference to the pubis (Fig. 40) would distinctly indicate the third phase which accords with the information given by the rest of the skeleton.

General skeletal acceleration.—No. 525 (Fig. 41) of age twenty-two died from pneumonia in City Hospital. We have therefore the

hospital file in addition to the family record to assure us that the age has been correctly stated. No epiphysial lines are discernable except that for the iliac crest which is not of much significance as an age marker. In general the skeleton indicates an age of about twenty-six or rather more but the absence of facets upon the teeth, the result of wear, accords with the stated age and not with that suggested by the skeleton. The pubic bones are unusual in that whereas the left symphysial face is concave in both the vertical and the antero-posterior directions the right face is convex. This anomaly was observed by Aeby (1) and is occasionally met with in the Reserve collection but it appears to be of no functional or real morphological significance. The specimen is of the type which has relatively poorly marked horizontal ridges and furrows and this feature together with the abnormally early appearing ventral rampart tends to mislead one regarding the age indication of the pubis. That the development of the symphysial face is anomalous is clearly indicated by the poor definition of the dorsal margin and the dorsal platform and by the absence of the lower extremity all of which are associated with the more advanced features already described. The ill-defined ventral rampart and upper extremity are being built up on the relatively slightly eroded ventral border. The entire surface presents a waxy appearance which one comes to associate with bone change which has entered upon a period of temporary stagnation. One would say therefore that the pubic bones show an age appearance of between twenty-five and twenty-eight years.

No. 458 (Fig. 42) is another case of generalized acceleration. The skeleton is that of a man of twenty-five dying of endocarditis. Acceleration is shown throughout the skeleton. There are no epiphysial lines on vertebræ, ribs or clavicles and no sign of the junctional lines in the sternal gladiolus, features which indicate an age of somewhat less than thirty. Slight lipping of long bones and the condition of the cranial sutures suggest about thirty-three but the teeth, in their wear, are compatible with about twenty-five. In the pubis the ventral rampart is almost completed but the lower extremity is less defined than one would expect from the condition of the rampart, and the ischia also suggest less than thirty. On the whole one may credit this skeleton with four or five years acceleration.

Regarding No. 330 (Fig. 43) there is some legitimate doubt con-

cerning the age. This is given as twenty-five. My reasons for expressing uncertainty as to whether this specimen should be included in the series of known age are several. The man was killed in an accident and therefore the age is not his own statement. The cranial sutures and the lipping of the long bones indicate approaching thirty-five. The ischia and the pubis also suggest this age. On the other hand the general texture of the skeleton and the wearing of the teeth are quite compatible with thirty years. The specimen is included simply upon the policy of refraining in any way from hand-picking the material. The extremities and ventral rampart are completed and the pubis falls within phase VII. Note also however that the symphyseal face is convex in both directions on the left side and concave upon the right.

No. 326 (Fig. 44) is another case of generalized acceleration. The recorded age is thirty and we at once look to the teeth for confirmation. Unfortunately they are peculiarly worn in consequence of an anomaly of occlusion and therefore do not help in age estimation. The absence of all epiphyses and the lipping of the long bones but not of the vertebræ or ribs indicate between thirty and thirty-five. The cranial sutures suggest about thirty-three. The pubic bones are referable to phase VII which corresponds to the ages thirty-three to thirty-nine and with this the ischia conform. All in all therefore this skeleton exhibits a general acceleration of bone change of about four years.

Contradictory skeletal age indications of acceleration.—The next case presents a somewhat different type of deviation. This is No. 448 of age thirty-one confirmed by the case sheet (Fig. 45). There is commencing lipping of the articular margins of the long bones of the legs and to a less extent of the arms. The first costal cartilages are quite considerably ossified and this is interesting for the individual died from phthisis complicated by tubercular abscesses in the sternum, ribs 2 and 3 on the left side and 3 and 11 on the right. Although all epiphyses are united there is no spondylitis and no lipping of the ischia. The wear of the teeth is not greater than one would expect at thirty-one and the cranial sutures indicate little over thirty. The symphyseal face of the pubis is distinctly in phase VII and the ventral aspect is quite quiescent. There is an irregularity in the age indication of the skeleton for pubis, ribs and leg bones suggest about thirty-six, cranial sutures about thirty-three and other features the

stated age of thirty-one. We must therefore examine the collection for further specimens of the same type.

No. 791 (Fig. 46) of age twenty-eight, confirmed by his case sheet at City Hospital where he died from pulmonary tuberculosis, shows a general bone age of between thirty and thirty-five but whereas the cranial sutures confirm this, the wear of the teeth is more compatible with the recorded age. While the symphysis like the ischia also points to about thirty-three it must be admitted that the ventral rampart presents the waxy appearance suggestive of having been formed for some time. This is unusual in relation to the relatively normal, excavated and very granular symphyseal and ventral aspects. On the whole then the acceleration of the skeleton, though definite, displays some points which suggest irregularity.

We thus discover a third grouping of individual deviations, one which may at first cause the reader to feel that too much is being claimed in the matter of estimating age relationships. The justification for this grouping of irregular age relationships within a single skeleton can only appear as the series of publications dealing with age features grows so as to include all the bones. In the building up of the collection all these skeletal features have necessarily been studied and it is impossible to avoid making reference to them and even calling upon them for confirmatory evidence before they are properly presented. It naturally follows that if we accept the two types of deviation which have just been discussed we must also accept the possibility of existence of the group to which we now turn.

Contradictory skeletal age indications of retardation.—Skeleton 792 comes from a man of twenty-three who died in City Hospital from pulmonary tuberculosis (Fig. 47). The age given by the family record is confirmed by the hospital file. So far as the rest of the skeleton is concerned there are no unfused epiphyses to be seen on the vertebrae or ribs but those of the clavicles are not yet united. The general skeleton then confirms the stated age. At the knees however there are epiphyseal lines on both femur and tibia, apparently indicating recent fusion. The ramal portions of the ischial epiphyses also are not quite fused. But the symphyseal face is the most striking and indicates an age of approximately nineteen. There is scarcely a suggestion of the dorsal margin and none at all of ventral bevelling. Even the pubic tubercle is not yet completely ossified, yet the subequal hori-

zontal ridges are clearly cut and show no evidence of stagnation of metamorphosis as do those of No. 525 to be described later. We must conclude therefore that there are local retardations of bone-change in the pelvis and possibly also at the knees.

No. 779 (Fig. 48), the skeleton of a man who died from broncho-pneumonia at the age of thirty-eight is another instance of irregular though general retardation. This individual died in the Medical Wards of City Hospital so that we have the evidence of his case-sheet to confirm the family record of his age. The cadaver on admission to the Department looked about thirty and we therefore anticipated finding some irregularities. Enough is said in this section of the memoir to show that acceleration or retardation of bone-change may be local or generalized in character. This is precisely parallel with the well recognized fact that external features may uniformly indicate a certain age which may or may not be the real age of the individual. Furthermore there may be more or less local accelerations or retardations in the external age-changes. Age features are not merely superficial; they obviously must appear in every tissue and every cell. Usually the general somatic age relationship extends throughout the body from the surface inwards but not always. The case in point as regards external features looked thirty; the sutures of the cranium suggested much less than this; even the teeth were relatively little worn for thirty-eight. The clavicles show epiphysial lines but there are no unfused epiphyses on vertebræ or ribs. There is an age relationship oscillating between twenty-five and thirty according to the part examined. When we look at the symphysis however we are inclined to state the age as between thirty and thirty-three for the extremities are well formed and the ventral rampart in course of development. The ischia on the other hand more nearly approach in their appearance the actual age of thirty-eight. It is therefore necessary to concede that this individual is irregular in the age relationship of his several parts.

Summing up the facts recorded in this section of the work we note that there are three types of individual deviation from the typical age relationship. The first of these is the type in which the os pubis alone exhibits retardation or acceleration of metamorphosis. In the second the entire skeleton is fairly evenly involved. In the third various

parts of the skeleton differ from each other in the age which they indicate.

In discussing the male Negro-hybrids there has been no effort to draw particular attention to instances of mixed phase as was done in the case of the male Whites. That such instances do occur is apparent from the inclusion of specimens such as No. 744. It is now possible to take the younger specimens, of which group No. 744 is one, and present them as examples of acceleration or retardation as it seemed inexpedient to do in the earlier part of this work. The reason for so doing has already been stated: the basic principles of pubic metamorphosis had not been sufficiently established. Such specimens will in future fall into their appropriate grouping.

In the section dealing with the male Whites it was pointed out that in certain cases phase VIII, IX, or X might supervene upon an earlier phase. It may be remarked that no reference is made to such cases in the present section for the very simple reason that they do not occur.

THE RELATIONSHIP OF RACIAL STOCK TO PUBIC METAMORPHOSIS

Having now considered fully the features of the male os pubis in random samples of reasonable size in the White and Negro-White hybrid populations of the United States we are in a position to draw certain conclusions regarding the relationship of human stock to the metamorphosis of this bone which, while perhaps not based upon samples large enough to justify final judgment, are at least admissible pending further study upon more extensive material.

First we observe that the bone change runs through the same phases irrespective of stock, the only difference being that in the Negro-hybrid the features of phase IX do not group themselves so definitely into a localized age period distinct from other features as they do in the White.

Secondly, the age relationships of the successive phases are substantially the same in both populations. It is true however that the remarks just made in regard to phase IX indicate a difference in the later periods. This difference is further emphasized by the following facts.

1. Phase VI terminates somewhat earlier, a year or two possibly, in the Negro-hybrid than in the White. This is off-set however by the lingering of phase VII to the thirty-ninth year as in Whites.

2. The commencement of formation of a "rim" to the symphyseal surface occurs in the Negro-hybrid during the seventh phase, that is to say some ten years earlier than in the White. This rim formation is however quickly aborted and never proceeds to the formation of a well defined raised edge as in the White.

3. Lipping of the dorsal margin occurs some five years earlier in the Negro-hybrid but again this process seems to be arrested before it has gone so far as it is liable to go in the White.

4. The secondary changes characteristic of phase X, namely surface rarefaction and ventral erosion also tend to commence some five years earlier in the Negro-hybrid. This process again seems not to proceed to such disorganization of the pubic bone as occurs in the senile White.

5. A feature possibly associated with but not causally related to the foregoing is the smaller inclination of the Negro-hybrid os pubis to develop a markedly pathological condition.

One may say therefore that while in general the phase-age relationships are in essential agreement the Negro-hybrid shows a marked tendency to pass through the phases occurring in the fourth and fifth decades of life more rapidly than the White by about five years but that in spite of this he does not develop the characteristic features to anything like the same degree as the White. I think this will be clearer if I remind the reader of the similar peculiarity of the Negro-hybrid in external features. We often note that the old American Negro is much better preserved than the White, meaning that he does not develop senile features to the same extent.

Thirdly as regards the various features of the several phases the striking fact is their almost identical nature in the two populations. The only differences are of very secondary importance. Some have been mentioned in the foregoing paragraph: others are the following.

In the first phase the horizontal ridges are subequal in the Negro-hybrid but more massive above in the White. The relation of the ventral rampart and upper epiphysial nodule to the epiphysis of the ischial ramus is better shown in the Negro-hybrid series. The ventral rampart is much more generally completed in the Negro-hybrid so that in the eighth phase the symphyseal margin is always complete.

In addition to the foregoing the collateral feature of the ischium

must not be forgotten. Although actual lipping of the attachment to the ischium of the sacro-tuberous ligament occurs during phase VII in White and Negro-hybrid alike, there is a greater previous development of this ligamentous ridge in the Negro-hybrid population.

Knowing as we do that Negro-hybrids retain many essentially negroid traits and that such traits are readily observable in the pelvis itself we are forced to conclude from this review that, so far as Negro and White pelvises are concerned stock has strikingly little influence upon pubic metamorphosis.

There still remain three aspects of the relationship which eventually must be presented. The discussion of anomalies in the os pubis, especially those related to the symphyseal area, will be taken up after the female pelvises have been considered. The frequency of individual deviations from the typical age relationship of pubic metamorphosis cannot be adequately treated until the amount of material is much greater than it is at present. The influence of racial stock upon the dimensions of the symphysis and even of the os pubis in general will be dealt with in later studies.

III. AGE CHANGES IN THE PUBIC BONE OF THE WHITE FEMALE HISTORICAL INTRODUCTION

According to Aeby it was Bouvart who first made a comparison of the rate of metamorphosis at the symphysis pubis in the male and female, Haller in 1750 quoting him as authority for the statement that ossification proceeds more slowly and is completed later in the female (see 1). With this statement Aeby found himself unable to agree.

Aeby sought to explain on the contrary that acceleration of ossification in the female is due to the periodic pelvic congestion characteristic of that sex. The physiological condition of the male pelvis, he says, remains the same throughout life whereas the female pelvis undergoes congestion at regular intervals during the prime of life. As a result of this congestion Aeby notes the marked softening of ligaments and holds it not contrary to common sense that vascularity in association with other factors energizes the ossification process. Pregnancy also, according to Aeby, may bring about the same result.

We have already seen that so far as the comparison between the White and Negro-White hybrid males is concerned there is no very

outstanding distinction due to stock in the age relationship of pubic metamorphosis. We now pass to examine in detail the sex factor.

TYPICAL METAMORPHOSIS

In the Western Reserve collection are forty-seven female White pelves of known age between sixteen and seventy-four years. While entirely too small a number for an independent study and also too small to base a final judgment upon as to the influence of the sex factor, we may nevertheless examine these pelves together with the Negro-hybrid females and upon the combined results form some impression of the relation of sex, taking into account the probability that we shall have at least as much justification for the impression we shall obtain as Aëby had for his quite definite assertions.

As representative of the immediate post-adolescent condition we turn to skeletons 527, and 437 (Figs. 49, 50) of sixteen and eighteen years respectively. In neither case is there any attempt at fusion of the iliac crest epiphysis and whereas there is partial union of the ischial epiphysis with the ischial tuber the ramal portion is still free. On both the epiphysis for the anterior iliac spine is completely united.

On the symphyseal face the horizontal ridges and furrows are similar to those of the male at the same ages except that the pattern is more delicate and there is no distinction in massiveness between the upper and lower ridges. No sign of any margin or of ventral bevelling is present but there is the usual abrupt differentiation and angle between the face and the dorsal and ventral aspects of the bone. There is the abrupt delimitation of the face from the upper aspect of the pubis and the gradual merging of the lower part with the ramus as in the male. One very obvious distinction in these two specimens however is the complete ossification of the pubic tubercle which lies quite a considerable distance from the symphyseal face instead of being very closely associated with it as in the male. As usual at this stage no bony nodules are to be observed fusing with the surface. There being only two skeletons in the first phase we are unable to define precisely the upper age limitation of the phase of which the features may be characterized almost in the terms already used for the male.

First post-adolescent phase. Age 16-?:—Symphyseal surface rugged, traversed by horizontal ridges separated by well marked grooves, there being no distinction in size between the upper and the

lower ridges and the whole pattern being more delicate than in the male. No bony (epiphysial) nodules fusing with the surface. No definite delimiting margin. No definition of extremities.

The female White pelves next in order of age are three which form a puzzling group because they present quite diverse features and yet each is of age twenty-five years. They illustrate vividly the extreme difficulty of deducing any conclusions from meager data. Indeed it is only the information which we have culled from the relatively large number of male skeletons which enables us to make use of the female series at all.

The first of these pelves, No. 604 (Fig. 51), exhibits the subequal horizontal ridges and furrows with a well-defined dorsal lip, a poor but none the less a real representative of the future dorsal margin. Adjacent to it the furrows are commencing to fill up with finely textured bone. There is a fusing bony nodule at the upper extremity of the symphysial face on both sides. The ventral margin is greatly bevelled owing to rarefaction. The clavicular epiphyses and ramal portions of the ischial epiphyses are almost united but all other epiphyses of the appendicular skeleton and vertebræ are fully fused. A few epiphyses for the heads of ribs alone remain incompletely united. So far then as the general skeleton is concerned it presents the features which we have learned to associate with age twenty-five. This age also is confirmed by the cranial sutures and the wear of the teeth. Nevertheless the pubic bones are clearly at the stage of metamorphosis defined as the later part of phase II and to the condition of the pubic bones the ischia conform. This would correspond in the male with twenty to twenty-one years.

No. 406, also a White female of twenty-five years, has the advantage over the last in possessing a Hospital record to confirm the stated age. Again the epiphyses remaining incompletely fused are those at the sternal ends of the clavicles and the heads of some ribs. In addition the ramal parts of the ischial epiphyses are not quite united. The endocranial sutures and wear of the teeth confirm age twenty-five. The skeleton is therefore in very much the same stage of general metamorphosis as No. 604. The symphysis however presents quite different characters. The differentiation into ridges and furrows is lost through the formation of a dorsal platform near the dorsal margin which is commencing to develop and forming quite a lip. There is considerable

beveling of the ventral portion but no delimitation of extremities. These are undoubtedly features of the third phase and, with the condition of the ischia, suggest that in comparison with this specimen No. 604 is an example of retardation in the pelvis alone.

The third example, No. 269 (Fig. 52) exhibits no unfused epiphyses even on the clavicles but there is no lipping of long bones, vertebræ or ribs. In the present state of our knowledge of the female skeleton we cannot infer more from this than that the skeleton is less than thirty-five years old. The state of the cranial sutures gives no further light. The wear of the teeth distinctly indicates no more than thirty and perhaps less than that. No bony nodules occur upon the symphyseal face which however shows a well formed dorsal margin and platform with some development of both extremities and even partial formation of the ventral rampart. In feature then the os pubis of No. 269 is at least in the late stage of phase V. It may be that further investigation will compel the elimination of this skeleton from those of known age.

Leaving No. 269 for the present we can state from observation of the other two that phases II and III correspond almost exactly in features with those of the male but the age limits of these two phases we are not yet in a position to define. The chief features are the following:

Second phase. Age ?-25:—Symphyseal face still rugged. The horizontal grooves are becoming filled near their dorsal limit with new finely textured bone. Bone (epiphysial) nodules fusing with upper symphyseal face. Dorsal delimiting margin begins to develop. No delimitation of extremities. Ventral bevel commencing.

The very obvious growth of the bone at the site of the dorsal margin and the marked lipping of this margin at this stage indicate there may be greater actual addition of bony substance than in the corresponding stage in the male.

Third phase. Age 25-26?:—Symphyseal face shows progressive obliteration of ridge and furrow system. Commencing formation of dorsal platform. Possible presence of bony nodules. Dorsal margin becoming more defined and sharply lipped. Ventral bevel more pronounced. Extremities not delimited.

There is no material at present which illustrates the features of the fourth phase but from examples of the next it is plain that the

procedure already described for the male is characteristic also of the female. The age relationship also must be nearly the same for we have noted that No. 406 of age twenty-five is in the later part of phase III, whereas No. 204 at twenty-seven years exhibits the earliest stage of phase V. Both of these skeletons are reliable as age indicators since their family record is borne out both by the hospital file and by their skeletal features.

From these two we may therefore outline in summary the main missing phase.

*Fourth phase. Age 26-27:—*Great increase of ventral bevelled area. Corresponding diminution of ridge and furrow formation. Complete definition of dorsal margin through the formation of the dorsal platform. Commencing delimitation of lower extremity.

We next turn to two skeletons which exemplify phase V. These are Nos. 204 of age twenty-seven and 514 of age thirty.

In No. 204 (Fig. 53) the ridge and furrow system is entirely obliterated by the dorsal platform and the ventral bevel. The dorsal margin is irregular in outline and sharply lipped. These features are much more characteristic of female pelves than of male and are almost constantly present in varying degree after the age of twenty-five. The lower extremity is fairly developed and the upper is commencing to form on the left side though not as yet on the right. A sporadic effort at formation of the ventral rampart occurs here and there on both sides.

The description just given holds also for No. 514 (Fig. 54) except for the following differences of which the first two are indicative of greater age. The lower extremity is better defined; the upper is more developed; there is no suggestion of a ventral rampart and there are still slight indications of the ridge and furrow system.

From these two we may therefore outline in summary the main characteristic of phase V.

*Fifth phase. Age 27-30:—*Relatively small change in symphyseal face and dorsal platform except for sporadic efforts at the formation of a ventral rampart. Dorsal margin increasingly clearly defined and more sharply lipped. Lower extremity better defined. Upper extremity forming with or without the intervention of a bony (epiphysal) nodule.

The sixth phase is represented in our collection by the following

specimens (Figs. 55-58): No. 306 of age thirty-four; Nos. 476, 603, 690 of age thirty-five; No. 552 of age thirty-six; Nos. 118, 421 of age thirty-eight.

The first suggestive fact is the age range of these pelves. It would appear as though the phase were later in its inception and its termination than in either male series previously considered. Against this it must be mentioned that there are no pelves in the series of between thirty and thirty-four years so that pending further accessions there is no direct evidence to justify the raising of the lower age limit. Further, although two specimens of age thirty-eight belong to this phase there are four which properly fall into succeeding ones. Three of age thirty-five belong to phase VI but two belong to phase VII. It is clear therefore that the upper age limit lies somewhere between thirty-five and thirty-eight, that is to say somewhat later than in the male White.

A second feature of the group is the relatively late transformation of the rarefied tissue of the ventral aspect into compact bone. The ventral rampart develops in precisely the same manner as in the male and the symphyseal face adjacent to the rampart consolidates correspondingly but the failure of the ventral aspect to follow suit results in the undermining of the rampart in a peculiar way which, in those cases where it occurs, is totally unrepresented in the male and quite characteristic of the female. It is associated, I believe, with retardation of the phase and consequent presence of the last two specimens, Nos. 118 and 421, in this group.

The formation of the ventral rampart occurs in the same manner as in the male. It is built up by the linkage of independent bony nodules in Nos. 421, 522 and 603 but in the others by the gradual growth of a mound of bone which nevertheless is more or less incomplete upon the ventral aspect. Since it is to the region thus remaining rarefied that the fibres of the ventral symphyseal ligament are attached it might be surmised that the specimens showing undermining in the clearest degree would also present a deep or otherwise strongly marked pre-auricular notch. This however is not the case: there does not appear to be any relation in degree of development between the two features.

The lipping of the dorsal margin noted in earlier groups of female pelves occurs in this also but without increasing in correspondence with

age. A peculiarity of the dorsal margin in the female is the retention of a pectinate outline, plainly connected with a remnant of the earlier ridge and furrow formation which lingers longer in the female and is still quite evident although faint in Nos. 188, 472, 522 and 603.

The various characteristics of the phase may be summarized in the following manner:

Sixth phase. Age 30-36:—Increasing definition of extremities. Development and practical completion of ventral rampart. Retention to a small degree of granular appearance of symphyseal face indicating that activity has not yet quite ceased. Failure of ventral aspect of pubis adjacent to ventral rampart to become transformed into a compact surface. Because of this the rampart is more or less undermined. Retention of pectinate outline of dorsal margin and in slight degree of ridge and furrow system. No lipping of ventral margin and no increased lipping of dorsal margin.

The stage of diminishing activity in the os pubis is shown by the following group of pelves (Figs. 59-61): Nos. 53, 260 of age thirty-five; Nos. 83, 221 of age thirty-eight; Nos. 16, 228 of age forty.

By the beginning of this phase the symphyseal face is already practically quiescent but there is still some undermining and rarefaction of the ventral aspect. The completion of the ventral aspect however rapidly occurs from below upward so that the last site of rarefaction observable is close to the upper extremity. There is indeed very little to differentiate the last stage from an early erosion. No symphyseal rim exists at this stage however, no lipping of the ventral border and no marked bony outgrowth into the tendinous and ligamentous attachments of the pelvis, and thus the observer is guided to the correct phase. It is to be noted that ossification of ligamentous and tendinous attachments apparently occurs somewhat later in the female than in the male.

One striking difference from the condition in the male is the obtrusive way in which the lower extremity juts out from the main mass of the pubis but this does not occur in all specimens. In some no such sexual distinction is discernible.

There is still in some instances a slight remnant of the ridge and furrow system but much less marked than in the last.

From the small number of observations it appears that completion of the ventral rampart always occurs but regarding this feature fur-

ther information is necessary. We may sum up the special characters of the phase thus:

Seventh phase. Age 36-40:—Slight changes in symphyisial face and marked changes in ventral aspect consequent upon diminishing activity. No formation of symphyisial rim. No ossification of tendinous and ligamentous attachments. The lower age limit is approximate but the upper is more exactly defined by the material.

General quiescence of the pubic bones is illustrated by the next group of specimens (Figs. 62-65): Nos. 243, 249 of age forty; Nos. 324, 457 of age forty-three; No. 415 of age forty-four; No. 111 of age forty-five.

There is very little comment to make upon this group. All show a symphyisial face and a ventral aspect devoid of erosion or rarefaction. Any lipping of the dorsal margin is entirely that which was already present at the beginning of the phase. There is a slight suggestion of rim formation on Nos. 243 and 457 but upon none of the others. The lipping of tendinous and ligamentous attachments which occurs at an earlier age in the male begins to make its appearance in the female at this stage. In No. 243 the ossification of the gracilis origin is very remarkable but by no means pathological. The symphyisial face of No. 324 is deformed, being concave in the vertical direction on the right side and convex on the left.

In brief then the characteristic features are the following:

Eighth phase. Age 40-45:—Symphyisial face and ventral aspect of pubic bone generally smooth and inactive. Oval outline complete. Extremities clearly defined. No distinct "rim" to symphyisial face. No lipping of ventral or increased lipping of dorsal margin. Development of ossification in tendinous and ligamentous attachments especially those of sacro-tuberous ligament and gracilis muscle.

We now pass to the consideration of the later stages of metamorphosis. The following pelves fall into phase IX (Figs. 66, 67): No. 517 of age forty-five; No. 355 of age forty-nine; Nos. 229, 252, 742 of age fifty; No. 411 of age fifty-one.

Upon all these except 517 and 411 the symphyisial rim can clearly be identified. In the case of the former it is still incomplete and in the latter it is obscured by deformity of the bone. There is no suggestion in any of activity, whether primary or secondary in symphyisial face or ventral aspect. No lipping occurs on the ventral mar-

gin and no increased lipping on the dorsal. As in the male series the only doubtful specimen, if one except the deformed No. 411, is rightly appraised as belonging to the border-line age between phases VIII and IX.

The features of the phase may be thus summarized:

Ninth phase. Age 45-50:—Symphysial face presents a more or less marked rim. No lipping of ventral and no further lipping of dorsal margin. No secondary erosion or rarefaction.

The last group of female White pelves comprises the following (Figs. 68, 69): No. 728 of age fifty; Nos. 311, 572 of age fifty-six; Nos. 22, 346, 541 of age sixty; No. 466 of age sixty-two; No. 281 of age sixty-three; No. 234 of age sixty-five; No. 340 of age seventy-two; No. 420 of age seventy-four.

This series differs from the corresponding male group very markedly. In the first place lipping of the ventral margin does not occur except slightly in No. 281. There is likewise no special lipping of the dorsal margin beyond that which apparently is one of the initial features of the margin itself.

Rarefaction starting in the symphysial face also is uncommon: it occurs only in Nos. 22 and 420 and in these it appears to be the result of rarefaction starting from the cancellous tissue within the substance of the bone rather than rarefaction originating in the surface itself. The otherwise invariable mode of commencement is erosion of the ventral margin which however progresses very slowly and is only well marked in Nos. 234 and 340 even in which specimens the erosion does not extend deeply into the symphysial face.

The essential features of the group can be stated very briefly:

Tenth phase. Age upwards of fifty:—Ventral margin eroded over a greater or less extent of its length, continuing somewhat into the symphysial face. No increased lipping. Disfigurement only occasional and slight.

INDIVIDUAL DEVIATIONS IN AGE RELATIONSHIP

As in the male occasional cases occur where the stage of pubic change fails to conform to the actual age. After discussing the instances presenting themselves in this series we shall be in a position to compare our results with those previously given.

In the consideration of the three specimens of age twenty-five, Nos. 604, 406 and 269, we observed that there was nothing in the records or the skeletal condition of the first and second to cast doubt upon the real age. Nevertheless the os pubis of No. 604 is indicative of phase II whereas that of No. 406 is equally certainly to be allotted to phase III. As the age relationships of the female skeleton are in general the same as those of the male it is apparent that here is evidence of retardation in the female os pubis alone.

For the reasons given in the previous section (p. 29) No. 269 must either be eliminated from the series of pelvises of known age or it must be admitted as one showing at least five years acceleration throughout the entire skeleton. Which of these courses should be adopted further investigation upon general age changes is required to decide.

General skeletal acceleration.—No. 681 (Fig. 70) has its stated age of twenty-eight confirmed by the City Hospital file. Since all epiphyses are united and no lipping has yet occurred it is difficult in the present state of our knowledge to give the upper age limit more exactly than between thirty and thirty-five. The wear of teeth distinctly indicates twenty-eight or but little more while the fusion of the clavicular epiphyses suggests no less than twenty-six. The cranial sutures indicate thirty to thirty-five. Although the ventral rampart of the symphyseal face is not definitely forming there is the considerable molecular bone growth in this area, one of the methods by which the ventral rampart is formed in the White. The method has been described for White males in part I of this memoir. In addition to the development of the ventral rampart the upper extremity is well formed. We are therefore compelled to refer this specimen to phase VI and to accord it some three years acceleration throughout the skeleton.

Doubt regarding the age of No. 339 (Fig. 71) is raised by the fact of her having committed suicide and her age therefore not being her own statement. But the absence of lipping and spondylitis and the condition of the teeth all confirm the stated age of thirty-eight years. It is true that there is some ossification of the first pair of costal cartilages and that the cranial sutures indicate about forty-five. On the whole one cannot accord this specimen more than three years' acceleration in bone change and with this the pubic bones and ischia very well agree for there is distinct lipping of the latter and

general quiescence of both symphyseal face and ventral aspect of the former.

No. 454 (Fig. 72) is from a woman who died of "malnutrition" at City Hospital and whose case sheet confirms the record of her age as thirty-eight. The malnutrition certainly did not retard the metamorphosis of the skeleton which shows a rather erratic age relationship. The slight lipping of the long bones and the ischia indicates somewhat over forty and this indeed is quite compatible with the condition of the teeth. The cranial sutures suggest much less than thirty-eight and there is no ossification of the first pair of costal cartilages. The os pubis shows a practically quiescent condition of the symphyseal face and the ventral aspect. Upon this record one must admit that although in general the features suggest an acceleration in metamorphosis it is only one of two or three years.

No. 715 (Fig. 73) of stated age forty-seven has no hospital record but the information revealed by the skeleton itself is quite unmistakable. There is marked lipping of all the long bones, ossification of the costal cartilages and spondylitis in the thoracic region. Together these features clearly indicate the close approach of fifty. The estimate is further justified by the commencing cinder-like texture of the vertebræ which in this case are affected before the ribs. The specimen is edentulous but the cranial sutures indicate well over forty. On the whole the stated age is confirmed with the reservation that there may be a slight general acceleration of about two years. The ischia are distinctly lipped and the pubic symphyseal face shows a poorly formed rim but erosion is commencing at the ventral margin so that here also slight acceleration occurs. The case is one therefore of generalized acceleration of metamorphosis in very moderate degree.

The cases showing individual deviation among the White females, as the foregoing record testifies, form a much less interesting group than those of the larger male Negro-hybrid series. This is partly due no doubt to the small amount of material upon which observations regarding the former can be made. Four cases of generalized acceleration occur but in none of them is there any startling deviation. No. 269, alone, included tentatively in the series, shows an acceleration of as much as five years. There is only one case suggestive of localized deviation, namely No. 604, an apparent instance of distinct and quite lengthy retardation. The significance of this apparent re-

tardation is not clear at this stage of the discussion though the similar tardiness in completion of phase VI suggests that it is really no retardation at all but that in the female os pubis there is normally a delay, compared with the male, in the progress of metamorphosis at this stage.

THE SEX FACTOR IN THE WHITE STOCK

The description of male and female White series shows that both sexes pass through a single definite succession of phases in the metamorphosis of the pubic bone. There are only a few differences in expression of one or two of the phases and these are of relatively minor consequence. The post-adolescent ridge and furrow system is somewhat more delicate and there is no distinction in massiveness between the upper and lower parts of the symphyseal face as there is in males. A delay of two or three years occurs in the consolidation of the ventral aspect of the pubic bone in the female so that the symphyseal face is already complete and quiescent before the ventral aspect. In the female also an irregular pectinate outline is retained much longer by the dorsal margin which is sharply and very early lipped. These features have special significance in the growth of bone at this site. Ossification of the tendinous and ligamentous attachments on the pelvis begins about five years later in the female. So far as our material goes there are far fewer pathological lesions in the female pelvis; lipping of the symphyseal margins and even erosion of the surface do not occur to the extent found in the male, and when erosion begins it is more orderly in its development. All of these features have but the most meager influence upon the estimate of sex and taken in a single case would be of very doubtful value.

There is however another group of features which is more definitely related to sex and seems to indicate a more vigorous growth associated with delayed metamorphosis in the symphyseal part of the os pubis during the years following close upon puberty. To this subject we shall have to recur in future studies for the incorporation of all the records and observations in this paper would extend it to inordinate length. While therefore we shall omit for the present the consideration and comparison of dimensions in the pubic bone and symphyseal face we may briefly refer to the features which cannot but obtrude themselves in observation of the morphological appearance.

The pubic tubercle is either rapidly being withdrawn from its connection with the symphyseal face soon after puberty as in No. 604, or is already far removed as in Nos. 437 and 527. This is not specially characteristic of the female for it is noticeable in both the preceding male series, but it is true that the specimens with the more distant pubic tubercles are usually female and the site of the tubercle gives the impression of relatively great increase of substance at the symphyseal end of the pubis. Further consideration of this matter must be postponed for the present, but there is evidence that the site of the tubercle is variable in different individuals.

The generally greater distance of the tubercle in females is to be associated with a feature which attracted Cleland's attention, namely the distance from the symphyseal face of the line of attachment of the gracilis muscle (2). As Cleland observes, the distance between these lines on right and left sides is considerably greater in the female than in the male. In his statement Cleland referred to "a middle-aged or old female." This distinction is not invariable according to my observations but when it does occur it is very striking. The obtrusiveness of the ridge is not marked until after the ventral rampart has been formed, that is until phase VII is well advanced or phase VIII begins. No. 243 (Fig. 62) shows the projection exceptionally well at forty years. Although Cleland admitted that the feature could not be used as a sex marker until "ossification is thoroughly completed" and he probably regarded this as some period after the age of twenty-five he was not in a position to carry the observation further. We have seen from the discussion of the male pubis that the marking out of the line in question is causally related to the growth of bone tissue as a rampart upon the ventral bevelled symphyseal area and we must therefore conclude that greater growth takes place at this site in the female than in the male. The difference may be equally well expressed as a relatively higher ventral rampart. Another feature intimately related to the growth of the ventral rampart is the greater outstanding character of the lower symphyseal extremity in the female. This apparently also fell under Cleland's observation and upon it he developed a theory of age-modification in the pelvis as a whole which is beyond the scope of the present discussion.

The prominence of the ventral rampart in the female suggests more vigorous growth or a longer period of growth at the symphysis in the

female and to this the character of the dorsal margin lends color. Instead of developing as in the male by the rather rapid filling of the hinder extremities of the horizontal grooves with new bone, the female dorsal margin becomes lipped at once as a thin edge which takes on a pectinate outline in consequence of the failure of the new bone to fill up the furrows. Indeed it is only during the seventh phase that this pectinate outline is really lost. One could not imagine that actual addition of substance continues at the symphysis up to this period but the peculiarities just mentioned do appear to indicate that there is a somewhat greater growth of bone in the earlier phases of female metamorphosis, although this cannot actually amount to more than one or two millimeters.

Before we leave the question of the sex factor for the present it is necessary to look into the relationship of the various phases to the age of the individual. As I shall shortly show Aeby characterized as inaccurate the assertion of Bouvart, which he quotes, to the effect that ossification proceeds more slowly and is completed later in the female than in the male (1). Observations on the Reserve skeletons however tend to confirm Bouvart's statement and contradict that of Aeby who had much less material than we upon which to base his conclusions and further had not the advantage of examining the entire skeleton and so checking off his observations on age relationship.

So far as our material goes there is evidence of delay in phases III and VI, so that their higher age limits are about two years later than in the male. This means that the commencement of extremity formation and completion of the ventral rampart may be somewhat retarded. But by the end of phase VII the age relationship is again practically the same in both sexes. Upon the basis of Aeby's theory of the relation of periodic pelvic congestion, more especially that of pregnancy, one might question how far this slight retardation of phase VI is influenced by child-bearing. The problem of the connection of pelvic sexual characters in their more marked degree to child-birth has by no means escaped our attention. Before making definite assertions much more work will have to be done. Indeed it is always difficult and in most cases impossible to obtain statements regarding children from or in relation to those females who ultimately find their way into our skeletal series. In the preliminary examination of the body upon arrival in the department all the ear-marks of child-birth are

carefully noted and recorded. Upon the observations so far carried out the evidence is wholly negative. This is in accordance with the conclusion of Hunter (4) that there is no real difference in the region of the symphysis pubis between the pelvis of the parturient and that of the non-pregnant woman. It is also in harmony with Aeby's view that no increase occurs in the actual distance between the pubic bones during pregnancy but that there is a softening and consequent extensibility in the ligaments themselves. No author except Aeby has so far claimed the consequent occurrence of any bone change. I do not believe that pregnancy and child-birth leave any permanent stamp upon the skeleton.

After the seventh phase there is no question of a sexual difference; the age-relationships of the phases do not differ in the female from those in the male. With the exception of the differences afore stated in the third and fourth decades we cannot admit any sexual factor in the age relationship of bone changes in the pubis. Such differences as occur between the ages of twenty and forty years will probably receive further confirmation for they are supported by the collateral evidence of sex differences in the ventral aspect of the os pubis and the lipping of tendinous and ligamentous attachments. Aeby's statement and the elaborate theory which he built up in consequence are directly contradicted by our material.

IV. AGE CHANGES IN THE PUBIC BONE OF THE NEGRO-WHITE HYBRID FEMALE INTRODUCTION

The acquisition of female Colored bodies is very difficult in Cleveland so that we possess only twenty-two pelvises in the series of known age and even among these one or two may eventually have to be discarded. To use so small a number as an independent unit in this investigation would be of course indefensible. We have already seen however that the sex factor has remarkably little influence upon the age relationships of pubic metamorphosis in Caucasian stock and also that differences due to human Stock are relatively insignificant so far as can be judged from a study of the American Negro-White hybrid male. The chief feature of distinction arising in this investigation is the date of termination of the third and sixth phases. In the male Negro-hybrid the sixth phase is completed two or three years earlier than in the male White whereas in the female White both phases tend

to continue for a year or two longer than in the male. While it is of interest therefore to record the pubic metamorphosis as it occurs in the female Negro-hybrid and note its relation to age, sex and Stock it is naturally the period of the third and fourth decades upon which our interest chiefly concentrates.

TYPICAL METAMORPHOSIS

As examples of the first phase we are able to present Nos. 485 and 576 both of age sixteen (Fig. 74). In both the iliac and ischial epiphyses are in process of union with the ossa innominata although there is as yet but little ossification of the ramal portions of the ischial epiphyses. The epiphysial line for the anterior inferior spine is still faintly discernible on No. 576 the dates of birth and death of whom were Aug. 31, 1901, and Jan. 1, 1918, respectively. In accordance with the rather greater age this line is lost upon No. 485. We do not know precisely the date of birth of this individual but the record gives 1900 and the date of death was Jan. 12, 1917.

The features of both specimens are exactly those already given for the female White of like phase and the only special observation necessary is that in No. 576 the pubic tubercle is still an extension of the symphyisial face but in No. 485 it is far removed, independent and completely ossified.

As in the female White series no other specimens occur below the age twenty-five so that the upper age limit of the phase cannot be certainly given. Nevertheless the features may shortly be stated in the following manner:

First phase. Age 16-?:—Symphyisial face rugged, traversed by rather delicate subequal horizontal ridges. No bony (epiphysial) nodules fusing with the surface. No definite delimiting margin. No definition of extremities.

Turning next to the two specimens of age twenty-five, namely Nos. 495 and 561 we find difficulties similar to those found in the female Whites of the same age.

No. 561 (Fig. 75) possesses a skeleton which from the recent fusion of clavicular epiphyses, character of cranial sutures and wear of teeth we must conclude is actually of age twenty-five or but little more. The dorsal margin of the symphyisial face is becoming defined and the earliest stage of formation of the dorsal platform is brought about

by the appearance of new bone in the hinder portions of the horizontal grooves. The ventral bevel is fairly considerable but there is no suggestion of extremities or of bony nodules. The specimen is therefore at the border-line between phases II and III and tends to confirm the indication given by the female White pelvis that these phases are a little retarded in their completion compared with the male. We have not sufficient material however to make more than the tentative suggestion.

Indeed the next specimen, No. 495 (Fig. 85) appears to refute the suggestion absolutely, the more so as the information upon it is quite detailed. The date of birth was Jan. 10, 1892 and that of death Jan. 19, 1917. The skeleton as a whole points to about thirty years or rather more by the condition of the clavicles, long bones, vertebrae and cranial sutures although the teeth do not indicate so much. From the external appearance of the cadaver an energetic investigation was immediately taken up to be sure that the correct body had been delivered to us, and as a result of tracing it in its journey from the hospital to the Department there seems no reasonable doubt of its authenticity. It ought therefore to be considered as a case of generalized acceleration and will be so recorded but is brought in at this juncture to emphasize the difficulty of recognizing and establishing age changes except upon a large material. The symphyseal face has its extremities recently completed and the ventral rampart newly formed and as yet undermined upon the ventral aspect. The dorsal margin is not so clearly defined as one would expect from the stage to which the other parts have progressed, nevertheless the specimen must be allotted to the border-line between phases VI and VII and would certainly be eliminated from the series of known age but for the precise records.

Upon the basis of the single specimen No. 561 we can state simply that the second and third phases in the female Negro hybrid seem to possess the same features as the male and that the passage of the one into the other may not occur until the age of twenty-five years. If confirmed, this would raise the upper limit of the third phase several years beyond that of the corresponding male and one or two beyond that of the female White. At present no definite age statement can be made but for the sake of completeness the following notes should be recorded regarding phases II, III, IV, the observations being justi-

fied by the evidence of other specimens and by the collateral evidence of other series.

Second phase. Age ?-25:—The statement of age relationship is purely provisional. Symphysial face still rugged. Grooves beginning to fill up with new bone at their hinder ends. Commencement of formation of dorsal delimiting margin. No delimitation of extremities. Ventral bevel commencing.

Third phase. Age 25-?:—The statement of age relationship is purely provisional. Symphysial face shows progressive obliteration of ridge and furrow system. Commencement of dorsal platform. Dorsal margin becoming more defined. Ventral bevel increasing. No delimitation of extremities.

Fourth phase. Age ?-?:—No statement of age relationship is possible at present except the inference drawn from specimens in the collection that the phase begins some time after the age of twenty-five and terminates before twenty-nine. Probably as in the male of very short duration. Increase of ventral bevelled area. Corresponding diminution of ridge and furrow system. Complete definition of dorsal margin through the formation of the dorsal platform. Commencing delimitation of lower extremity.

We now pass on to two skeletons which show almost equally well the very beginning of both extremities. They are No. 704 of age twenty-nine and 589 of age thirty. Both have a clearly defined dorsal margin and a dorsal platform which extends over approximately half the surface towards its ventral limit. The dorsal margin is not specially lipped although it is inclined to show the pectinate outline. The ventral bevel is very pronounced and there are sporadic efforts at the formation of a ventral rampart. The lower extremity is indistinctly formed and the upper is rapidly becoming delimited without the intervention of a bony nodule. The pelves are therefore certainly in the fifth phase which in the male Negro-hybrid is complete at about twenty-nine and in the female White at somewhat over thirty. In the Negro-hybrid female it seems to be the sex factor which is of weight rather than the type of Stock, at least in the third decade.

We have seen that the third phase is delayed in its completion and from the rapidity with which the delimitation of the upper extremity follows that of the lower we may justly infer that the fourth is shortened. This great contraction is not a feature of the male in

either Stock examined, but it is approximated in the female Whites of our collection.

The special characters just outlined may be thus stated:

Fifth phase. Age ?-30:—Symphysial face shows well developed dorsal platform and slight and sporadic attempts to form a ventral rampart. Dorsal margin clearly defined and somewhat lipped. Lower extremity still poorly defined. Upper extremity forming without necessarily developing a bony (epiphysial) nodule.

The *sixth phase*, as in the female White series, is well represented in our collection. It comprises the following (Figs. 76-78): No. 461 of age thirty; No. 613 of age thirty-three; No. 529 of age thirty-four; Nos. 128, 520 and 545 of age thirty-five; No. 668 of age thirty-seven.

One notes immediately that whereas the lower age limit is comparable with all the other series the upper age limit disagrees violently with that of the corresponding male group. In the male Negro-hybrid series phase VI is completed between thirty-three and thirty-five. In the female White series on the other hand phase VI does not terminate until between the ages of thirty-five and thirty-eight. Here again in the female Negro-hybrid the sex factor is the important one.

The characters of the phase are those of the same phase in the female Whites and there is again the peculiarity of completion of the symphysial face a considerable time before that of the ventral aspect so that the ventral rampart when almost or quite complete is still considerably undermined by rarefied tissue. No increased lipping of the dorsal margin takes place during this phase and the pectinate outline is especially distinct in some specimens. We may state the characters of this phase simply in summary:

Sixth phase. Age 30-37:—Increasing definition of extremities. Development and practical completion of ventral rampart. Retention to a small degree of granular appearance of symphysial face indicating that activity has not quite ceased. Failure of ventral aspect of pubis adjacent to ventral rampart to become transformed into a compact surface. Because of this the rampart is more or less undermined. Retention of pectinate outline by dorsal margin and in slight degree of ridge and furrow system. No lipping of ventral margin and no increased lipping of dorsal margin.

Nos. 315 and 442 both of age forty (Figs. 79, 80) show the beginning of quiescence. The ventral rampart is not thoroughly com-

pleted in either but there is the typical waxy appearance of the surface which denotes the supervention of inactivity. The symphyseal face is already almost smooth and the ventral aspect is rapidly losing its granular surface. The dorsal margin is very little more lipped than in the foregoing phase but there is a suggestion of a rim upon it, an appearance which I had not expected to find in this series. The lipping of the gracilis attachment is well marked in No. 315 but not in No. 442 and in both the ossification of the sacro-tuberous ligament is distinct though much less pronounced than in older specimens.

These two pelves must therefore be assigned to the end of phase VII or the beginning of phase VIII and since we find secondary erosion in bones of forty-five years the age limitations of these two phases may be provisionally outlined as similar to those of the female White.

Seventh phase. Age 37-40:—Changes in symphyseal face and ventral aspect consequent upon diminishing activity. Attempt at formation of raised edge or "rim" to margin. Completion of ventral rampart if not already completed during last phase. Possibly commencing ossification of tendinous and ligamentous attachments.

Eighth phase. Age 40-45:—Symphyseal face and ventral aspect smooth and inactive. Extremities clearly defined. Possible continuation of attempt at formation of "rim" to symphyseal outline. No marked increase in lipping of dorsal margin. Definite ossification of tendinous and ligamentous attachments.

As with the male Negro-hybrids there are no specimens showing either the characteristic "rim" formation going on to anything like completeness or the lipping of the dorsal and ventral margins found in phase IX. We must admit that so far as the American Negro population is concerned phase IX does not exist as a separate entity.

The remaining pelves must be grouped together as representing phase IX-X. They are (Figs. 81-84): Nos. 530, 685 of age forty-five; No. 516 of age fifty-one; Nos. 152, 331 of age seventy.

All show a well marked lipping of the dorsal margin but very little on the remainder of the symphyseal border, and an aborted "rim" formation. No. 152 hardly looks the recorded age but so far no skeletal features have presented themselves by which fine distinctions can be made in such old skeletons. No. 530 shows some erosion of the ventral margin and No. 685 of the symphyseal face although the

latter may well be the beginning of pathological change in this specimen. None of the rest shows any secondary change whatever.

The features in summary are the following:

Phase IX-X. Age forty-five and upwards:—Symphysial face shows no well defined "rim" but possibly some rarefaction of surface. Dorsal and to a less extent the ventral margin considerably lipping. Possibly erosion of ventral margin. Pathological disfigurement occasional and slight.

INDIVIDUAL DEVIATIONS IN AGE RELATIONSHIP

Among the twenty-two skeletons of this series there are five which demand special notice on account of irregularities in age relationship. They are Nos. 152, 226, 439, 495, 530. Some of these have already been considered.

General skeletal acceleration.—No. 495 (Fig. 85), the particulars of which have previously been set forth, shows general acceleration of age changes to such a degree that in spite of the carefully kept and well followed-up record I admit to the series of known age with misgiving and anticipate the possibility of its elimination later when more precision is attained in age estimation.

Another very puzzling case suggesting generalized acceleration is No. 439 (Fig. 86) of age thirty-five years. This was the victim of a street car accident and I have not been able to find out who gave the statement regarding age. Certainly the lipping of the long bones and first costal cartilages suggest forty and the cranial sutures confirm this. The wear of the teeth however is not incompatible with thirty-five or thereabouts and the woman suffered from a peculiar affliction of the bones which resulted in local softening and deformation especially in the pelvis. The specimen therefore remains on the list of those of known age until definite evidence shall be forthcoming that its inclusion is certainly an error. The symphysial face is on the border-line between phase VII and phase VIII and therefore confirms the general skeletal age of about forty.

No. 152 (Fig. 83) of age seventy has also been considered and it was pointed out that in the present state of our general skeletal investigation dogmatic assertions regarding such old skeletons are unwarranted. The texture of the bones in general indicates sixty years and there is advanced arthritis of both wrists and the left shoulder.

The teeth indicate by their wear more than fifty. The pelvic bones lack the shaggy appearance usual in very old specimens but we have not yet sufficient specimens to justify the assertion that such a condition is necessarily present in advanced age. The cranial sutures are compatible with thirty years and no more. There are thus definitely marked anomalies in age relationship in this skeleton whatever the actual age. It is probably best to leave the specimen as unproven but possibly indicating considerable and erratic retardation.

Local acceleration.—The two remaining pelvises are more easily dealt with since the anomaly is localized to the pubic bone.

No. 530 (Fig. 81) of age forty-five, already provisionally assigned to phase IX-X, shows what appears to be the commencement of erosion upon a ventral border never finally completed. It may be the supervention of phase X on a retained phase VI. Certainly the wear of the teeth, the lipping of the long bones and the vertebræ indicate that the recorded age is correct. The cranial sutures are typical of thirty which is obviously not the real age. The ventral border of the symphysis has a peculiar waxy appearance except in localized areas of erosion and this appearance is characteristic of quiescence. We must classify the pubis therefore as an example of local retardation.

The last anomalous specimen is No. 226 of age thirty (Fig. 87). The teeth are carious and some have been extracted but their wear is clavicles, vertebræ and cranial sutures. There is marked arthritis of both wrists but no lipping of other long bones. So far as the skeleton in general goes there is nothing to call in question the recorded age. The ischia are however distinctly lipped and the pubic bones are in phase VII. The symphyseal height is very short and the symphyseal faces are deformed so that a knife driven through the cartilage of the symphysis would not pass directly backward but would incline toward the left sacro-iliac articulation. From the local acceleration noted in association with short symphyses in previous series one would be inclined to attribute the symphyseal acceleration at least to the same cause which brought about the symphyseal deformity.

CHARACTERISTIC FEATURES OF THE FEMALE NEGRO-HYBRID OS PUBIS

Fragmentary as the observations upon so small a series must necessarily be one cannot but note that the Negro-hybrid female resembles the White female in very many of the essential features of pubic meta-

morphosis but that in some the negroid strain is apparent. A full discussion of the sex and stock-linked characters brought out by this investigation follows immediately but it is not out of place to refresh one's memory at this stage with a summary of the facts and inferences just presented.

As in the female White the post-adolescent pattern of the symphyseal face is delicate and remains relatively unchanged for a considerable time longer than in the male. In the discussion of the delay in transition from phase II into phase III one recalls the confusion injected into this question by the rival claims of Nos. 604 and 406 among the female Whites. Nevertheless by the end of phase V there is substantial agreement once more in all the series as to time relationship.

Again as in the female White series there is a lagging in completion of the sixth phase and in this respect there is a marked distinction between the male and female hybrids.

Female peculiarities are evident in the completion of the symphyseal face long before the ventral aspect of the pubic bone, in the pectinate outline and early sharp lipping of the dorsal margin, in the failure or slight nature of the later lipping of the symphyseal border and in the collateral feature of delayed ossification in the attachments of tendons and ligaments.

One very striking difference however from the condition in the female White is the absence of any suggestion of relatively great growth in the symphyseal region of the pubic bone. There is no wide separation of the lines of gracilis attachment even in skeletons over forty; there is no relatively prominent ventral rampart and there is no marked outstanding of the lower extremity. The pubic tubercles are indeed widely separated in many cases but in many others they are not even visible. The specific sex character which so powerfully attracted Cleland's attention fails when applied to the Negro-hybrid.

The female Negro-hybrid resembles the male of the same stock in the apparently invariable completion of the symphyseal outline, in the early and abortive attempt at the formation of a raised edge or "rim" to the symphyseal margin, in the absence of phase IX as a separate entity, in the slight extent of secondary change and in the infrequency of pathological disfigurement.

ASSEMBLED RESULTS OF THE INVESTIGATION

FEATURES OF PUBIC METAMORPHOSIS ATTRIBUTABLE TO SEX AND STOCK

Now that the life history of pubic metamorphosis as it relates to both sexes of the White and Negro-White hybrid populations of the United States has been fully described it is possible to draw some conclusions regarding the linkage of various features with sex and with racial Stock. In spite of the disadvantages resulting from lack of a really pure Negro strain with which to make comparison one is emboldened to attack the latter problem because our negroid population retains even in its admixture the characteristic features of the Negro pelvis in general and therefore may reasonably be expected to betray its negroid origin in the detail of the processes by which this final definite result is brought about. In the absence of information concerning the corresponding stages in the full-blooded Negro pelvis one may infer with reason that such differences from the metamorphosis of the White population as are shown by the Negro-hybrids would be still further emphasized in the African Negro.

In the case of the Whites no effort has been made to segregate such different races as the Nordic, Alpine or Mediterranean partly because of the difficulty of obtaining all the necessary information needed to render this possible, partly because many of the individuals whose skeletons are utilized in this survey were native born Americans whose ancestry is even more involved and obscure than that of the immigrants, and partly because the problem at large, in the present stage at least, relates to the influence of Stock rather than of Race.

Concerning the size of the samples of population in the present survey it may be objected that they are too small to serve as a basis for any final or sweeping conclusions. In a statistical review this would undoubtedly be the case and it will be noted that I have contented myself for the moment with recording methods of measurement and the reasons therefor but defer the presentation of averages and indices until such time as the collection is great enough to warrant mathematical consideration. Without a much larger material of hybrids and females a comparison of measurements reduced mathematically would be of little significance. It is otherwise however with the morphological features which are now under discussion. The establishment of the salient facts of metamorphosis rests upon the examination of about five hundred male White pelvises of which three hundred are

included in the earlier part of this memoir. The presentation of these facts forms a satisfactory background for the life-history of the Negro-White os pubis represented in this work by more than one hundred pelves of both sexes. Taking White and Negro-hybrid populations together almost eighty female pelves have been utilized. Since these accumulate far more slowly than the male and since quite definite distinctions in metamorphosis are indicated even by this number especially in phases which are well represented in the collection I have not hesitated to set forth the evidence offered by our present material in relation to the influence of sex, recognizing fully the possibility of later modification in minor details with the accumulation of more extensive data.

As to the size of samples the individual specimens of which can be effectively compared morphologically there are imposed by the bulkiness and perishability of the material limitations which do not apply to tables of measurements. For purposes of comparison of morphological data it is almost essential to have the entire sample laid out for observation at one time. Without this precaution most of the age changes would receive inadequate attention or would fail to make the vivid impression gathered when all the specimens are displayed at once. In practice one finds that, in point of time and space, the sample which can be most conveniently correlated as to morphological detail is one hundred pairs of bones. The examination of so large a sample as the three hundred pairs drawn upon for the initial survey is apt to entail considerable risk of damage to specimens owing to the time necessarily consumed in the investigation, while the maze of detail almost obscures the principles. Yet in no other way is it possible to study accurately the data presented. Conclusions once drawn from a sample of reasonable size can be submitted to confirmation or correction by the examination of further samples, the size of which will be determined largely by the physical limitations of possible accommodation.

STOCK-LINKED CHARACTERS

It is not necessary at this stage to recapitulate the various features of pubic metamorphosis. A comparison of White and Negro-hybrid populations has already been made in the description of the

male bones but some amplification is rendered necessary by the consideration of the female pelvis.

In both populations the symphyseal face of the os pubis in youth resembles a diaphyso-epiphyseal plane upon which definite epiphyseal nodules may or may not make their appearance, rapidly fusing with the main bone. In both the symphyseal face is ultimately completed or nearly completed by the growth of a margin divisible into dorsal and ventral borders and upper and lower extremities. Furthermore the ventral border and extremities may or may not involve in their composition epiphyseal nodules. In the Negro-hybrid the involvement of a definite bony nodule in development of the lower extremity and of a succession of nodules, which speedily unite to form bony bridges, in the growth of the ventral rampart is much more clearly shown although these features are sufficiently evident even in the White. In addition to the obvious manner in which this detail of construction is shown in the Negro-hybrid and certainly to be associated with it is the apparently invariable completion of the symphyseal outline in contradistinction to the White. In the latter the gap, if there be one in the outline, is always in the upper third of the ventral margin and may involve the upper extremity. These significant facts in the building up of the symphyseal outline will receive adequate attention in a later communication dealing with the general morphology of the mammalian os pubis. At present one must leave the problem with the bare observation that the Negro-hybrid exhibits a method of symphyseal construction apparently more primitive than that of the White.

Two features apparently connected with the modification of symphyseal construction in the White Stock are the frequent ill-marked condition or even absence of the ridge and furrow system and the method of formation of the ventral margin.

From part I of this memoir it will be observed that many specimens of the male White os pubis show poorly-developed horizontal ridges upon the symphyseal face. Indeed in some cases they are almost absent. This variation caused considerable confusion at first and seemed to interpose an insuperable obstacle to the age-grouping of specimens in the third decade of life. The investigation of Negro-hybrid Stock shows however that degree of development of the ridge and furrow system is a relatively minor character. Our Negro-hybrid

material of both sexes exhibits no such ill-defined ridges. It is true that examples are also rare in the female White series but this is so much smaller than the male White collection that I am not inclined to lay stress upon the feature as indicative of sex, especially since it is in its essence a secondary character like others which have just been discussed.

From the consideration of our material also it is apparent that the White Stock shows a much greater tendency to loss of the bony nodules from which the ventral rampart is built up than does the Negro-hybrid. Instead of isolated bony nodules linking up with each other and with the osseous deposits of the upper and lower extremities to form actual if temporary bone bridges, many examples of the White Stock present a ventral margin growing by simple linear mound-like addition of bony substance to the ventral part of the symphyseal face. Collateral evidence points distinctly to the bridge-work as the more typically primitive, if one use this word in a guarded sense, and to the gradual accretion or mound formation which is a slovenly, less vigorous bone metamorphosis, as probably a symbol of degeneracy.

As regards the post-adolescent pattern of the symphyseal face, the subequal nature of the horizontal ridges in the Negro-hybrid as distinguished from the White with its more massive upper ridges is of little significance and fades away in the comparison of the females.

The abortive attempt at formation of a "rim" to the symphyseal outline is much more characteristic of the Negro-hybrid but a well marked rim is not invariable in the White especially in the female. Its occurrence is apparently similar to the development of a slight rim to the glenoid margin about the same period of life and concerning its significance there is no evidence to offer at present. Associated with its absence in the Negro-hybrid is the failure of phase IX to develop in that Stock as a definite unit of age change.

The occurrence of "rim" formation, such as it is, in the Negro-hybrid ten years earlier than in the White must be associated with the earlier termination by about two years of the sixth phase and the earlier supervention by five years of phase X in that Stock. All these indicate the more rapid succession of features progressively attained during adult life. But on the other hand from the fact that the Negro-hybrid shows a relatively small amount of secondary ero-

sion and only infrequently any pronounced pathological change such as we have come to associate with senility it must be maintained that the Negro-hybrid becomes senile much more slowly than the White, so far as the pubic bone can exemplify this belief.

In a review of racial Stock characters one must not fail to mention the fact that although lipping of the attachment of the sacrotuberous ligament makes its appearance at about the same time in both Stocks there is a ridge in the Negro-hybrid, at an earlier age, much more marked in the male sex, apparently typical of the Stock and important only in relation to other instances of the same kind scattered over the skeleton.

There is still another question regarding Stock-linked characters which may receive passing notice at this stage of the investigation, namely the relative frequency of instances of individual deviation from type presented by the White and Negroid Stocks. We have at present no accurate tabulation of data upon which to make such a comparison. Indeed a tabulation would be very difficult to make and probably quite equivocal and unprofitable in the end. We have already seen that there are three types of deviation both of retardation and of acceleration. The selection of material for comparison could not be an easy matter.

Among the White Stock the ancestry of individuals, whether American born or immigrant is quite involved and it is conceivable that there may be differences in precise age relationship between say the more northern Nordic and more southern Mediterranean races. But involved as the problem is for the Whites it is still more difficult in the case of pure Negro Stock of which we have less accurate information regarding the various races. Representatives of various Negro races are undoubtedly present in our collection. We have for example several who show distinctly an ancestry from the tribe which Hawkins exterminated from West Africa when he brought the entire population across the Atlantic as slaves. When therefore the already mixed White and Negroid Stocks formed the hybrid population now known as the American Negro the problem for this hybrid Stock became very complex indeed. All that one can state is that there does not appear to be any marked distinction in number or extent of deviation from type when the White and Negro-White hybrid populations are compared without mathematical reduction.

SEX-LINKED CHARACTERS

As sex-linked characters in the pubic bone there is evidence in the foregoing descriptions of a modified age relationship in metamorphosis the exact significance of which is not yet clear but it is interesting to note that the female Negro-hybrid resembles the female White much more closely in this respect than she resembles the male of her own Stock. The evidence of this intensifies the probability that there are indeed sex-linked characters.

The various phases of metamorphosis arrange themselves rather naturally into three periods. The first comprises phases I, II, III, and includes early modifications preliminary and in a sense preparatory to the development of the definitive outline of the symphysial face. During the later part of this period the dorsal margin is indeed forming but not until early in the next is it well defined. The second period includes phases IV, V, VI. This is the period of actual formation of the symphysial outline although occasionally and for reasons explained in the body of the memoir completion may be deferred till the seventh phase. The third period may be defined as that of relative quiescence which is led up to by phase VII and curtailed by secondary changes in phase X but nevertheless includes phases VII, VIII, IX, X.

In the first two periods there is some normal retardation of metamorphosis seemingly characteristic of the female. This is evinced at precisely those stages where it might be expected to make its appearance. There is delay of perhaps two to three years in the commencement of phase III and some delay, less clearly defined in years by the present available material, in the termination of this phase. The meaning of the phase retardation is of course a retention for a short period longer than in the male of the essentially post-adolescent stage during which actual addition of bony substance is possible.

A more delicate pattern in the ridge and furrow system seems also to be more characteristic of the female sex.

A similar retardation is even more strikingly demonstrated during the second period for although the earlier phases show no real difference in time relation from these in the male the actual termination of the period as indicated by completion of the symphysial outline occurs on the whole about two years later than in the male and even then changes which are referable in reality to the second period are

still being evinced in the ventral aspect of the pubic bone during the seventh phase. The retardation is even longer and therefore more marked in the female Negro-hybrid than in the female White. In confirmation of the sex-linkage of this delay are various accessory features, namely the early sharp lipping and pectinate outline of the dorsal margin, the peculiarity just mentioned in the completion of the symphyseal face some time before that of the ventral aspect, the later date of appearance of lipping of pelvic tendinous and ligamentous attachments, and in the female White at least the greater distance between the lines of gracilis origin at and after the termination of the period.

During the third period a smaller inclination to lipping of the symphyseal outline appears to be a sex feature.

Before leaving the problem of sex-linked characters it is necessary to note briefly the relation of observations recorded in the present work to those made by Aeby upon the same subject. In all other respects the two investigations are quite harmonious and supplement each other. So far as sex is concerned we have seen that according to my observations there is in the female delay of about two years in the completion of the second and probably also of the first periods of post-adolescent metamorphosis. Aeby measured across the soft tissues of the symphysis upon horizontal sections the distance between the bony symphyseal faces of the ossa pubis at the extreme dorsal and ventral limits. The former he called the dorsal measurement and the latter the ventral measurement. I reproduce below Aeby's table of results in full.

TRANSVERSE MEASUREMENTS THROUGH THE SYMPHYSIS

Age in Years	MALE			FEMALE		
	No. of Cases	Ventral Measurement	Dorsal Measurement	No. of Cases	Ventral Measurement	Dorsal Measurement
1-14	3	13.7(12-16)	6.7(5- 8)	4	16.2(13-18)	8.3(5-12)
15-30	12	17.3(15-22)	6.4(3-10)	12	19.1(15-23)	7.3(4-13)
30-50	11	10.4(5-20)	5.4(3-10)	8	9.5(5-17)	4.6(3- 7)
over 50	13	11.5(5-21)	4.3(2- 6)	5	11.0 (6-19)	4.5(3- 6)

It will be seen that Aeby's investigation was conducted upon 68 specimens of which 39 were male and 29 female. In both dorsal and ventral measurements it is obvious that the female shows a greater

interosseous breadth during the first thirty years but that between thirty and fifty years the interosseous breadth in the female is less than that in the male. Over fifty years there is no sexual differences. From these figures Aeby infers that ossification in the female ossa pubis is more rapid and extensive between thirty and fifty years than in the male and to account for this he develops a theory that the sex difference is due to more energetic ossification in the sexual period of the female brought about by periodic pelvic congestion.

Aeby's remarks concerning this are as follows:

“Woher wohl dieses auffallend wechselnde Verhalten?—So räthselhaft die Sache anfangs auch erscheinen mag, so lässt sie sich doch vielleicht ohne allzugrosse Schwierigkeit erklären. Der physiologische Zustand des männlichen Beckens bleibt sich unter normalen Verhältnissen während des ganzen Lebens ziemlich gleich; nicht so derjenige des weiblichen, das während den Blüthjahren regelmässig in bestimmten Zwischenräumen von mit dem Geschlechtsleben des Weibes zusammenhängenden Blut-congestionen heimgesucht wird. Es ist somit heurdurch eine grössere Säftefülle gegeben, und gewiss liegt nichts Widersinniges in der Annahme, dass durch eine solche, so gut wie noch manche andere Prozesse, auch der Verknöcherungsprozess energischer sich gestalten. Eingestretene Schwangerschaft würde ganz in derselben Weise zu wirken vermögen.”

Nevertheless the sentences immediately preceding those just quoted seem to imply that in explaining his results Aeby expressed them incorrectly. Since I am unable to harmonize the latter part of the paragraph quoted below with either the table reproduced above or the earlier part of the paragraph or again with the quotation just made which gives the essence of Aeby's argument I reproduce in full the author's opening remarks.

“Von besonderem Interesse für uns sind die Resultate, welche sich aus einer Vergleichung der Zahlen für beide Geschlechter ergeben. Hier lehrt schon der erste Blick, wie grundlos die so vielfach ausgesprochene Ansicht von grösserer Knorpelbreite der weiblichen Symphyse ist, und wie Unrecht Bouvart hatte, wenn er (a.a.O) bei dieser die Verknöcherung langsamer vorschreiten und erst später vollendet sein liess. Allerdings hat bis zur Pubertät das weibliche Geschlecht einen kleinen Vorsprung vor dem männlichen; allein schon in der folgenden Periode geschieht ein Schritt zur Ausgleichung des Verhältnisses und

nach dem 30. Jahre vermag es ihm kaum mehr gleich zu kommen, geschweige denn es zu übertreffen."

Whatever be the explanation of the discrepancy just alluded to we must not fail to note Aeby's significant statement regarding the age-relationship of pubic metamorphosis as shown in his table. He says that in both sexes while the dorsal measurement diminishes from birth, the ventral at first and up till the age of thirty years takes the contrary course, but afterwards diminishes so much the more rapidly. This is of course exactly in harmony with the description which I have given of the earlier formation of the dorsal margin and the occurrence of ventral bevelling previous to the development of the ventral rampart.

The facts presented in this section of the paper do not enable one to judge of sex or of racial Stock in any individual specimen: they are not the less characteristic of the population as a whole. With sex and Stock determined from other pelvic features they are of assistance in estimating the probable age of the individual specimen.

INTERPRETATION OF SECTIONS THROUGH THE OS PUBIS

With the facts of pubic metamorphosis fresh in mind it is particularly instructive to refer in some detail to the observations made more than half a century ago by Aeby (1) since the method used by this author differed radically from the one which I have employed.

Aeby worked upon fresh and unmacerated material mainly with the object of investigating the soft tissues of the symphysis and their relation to the bones. To this end he cut vertical transverse (frontal) and horizontal sections of the symphysis and noted the bony outlines thus brought to view. Aeby's description in summary follows.

Frontal sections through the middle and horizontal sections through the upper third of the symphysis give the desired information concerning the bony outlines. It will be noted that Aeby's horizontal section passes luckily through the exact spot where the ventral margin finally is completed and where secondary erosion is usually first seen. These sections indicate as a general law, according to Aeby, that with the passing of childhood the variety and irregularity of the bony outline increase, later to form once again a single and smooth surface. Further the outline which in the young is formed

of spongy bone very often becomes compact in later age as noted by Henle.

The form shown on frontal section exhibits relatively little change. Whereas the bony border in earlier childhood presents a low, curved, moderately smoothly rounded outline, this with increasing age elongates always more towards a straight line, merging above by a short sharp curve and below, according to the sex, by a distinct short angle into the pubic bone. The explanation of these features is of course the growth in length of the symphysis up to puberty and the development thereafter of the upper and lower extremities in the manner described in the body of this memoir. In the transformation thus brought about in the bony outline Aeby notes the production of a series of swellings, with more or less interruption, coursing horizontally from behind forwards and "doubtless not without importance for the stability of the union for the cartilage." This is the horizontal ridge and furrow system which I have described and to which, according to Aeby, attention was first directed by Tenon in 1806. Continuing Aeby states that he noted these swellings most developed after puberty when they reach a height of two millimeters or more. But later the formation is not more distinct: it becomes irregular and dwindles more and more, without however completely disappearing, while in great age more or less distinct undulations call it to mind. These observations of Aeby's are in general accordance with those which I have described from the study of macerated bones.

More changing and varied, says Aeby, are the results given by a horizontal section. The bony outline thus disclosed often assumes in children the form of a highly regular semicircle which very soon becomes changed by the tendency to form edges. First the hinder quadrant forms a sharp angle, the ventral on the contrary undergoing a simple extension in consequence of which it forms a blunt angle with the pubis. Thus the circularly cut outline varies and may show two surfaces one directed inwards and one forwards. This summary of Aeby's description indicates the development first of the dorsal margin and the increase of the ventral bevel which is responsible for the production of the two surfaces.

From this point, continues Aeby, there occur various gradations quite constant in relation to age until a stage is reached where the

outlines of the two symphyseal surfaces become parallel. Hence Aeby also observed the formation of the ventral rampart though he did not recognize it as such. The description of the formation of the ventral margin is strikingly confirmatory of the processes which I have discussed. In brief Aeby notes that the free bone margin is rarely regularly symmetrical for upon it varied prominences and incisures occur of which the form is governed not by rule but by chance so that only exceptionally do the two sides correspond. In occasional cases a cartilaginous island is found symmetrically upon both sides surrounded by bone, or a bone island surrounded by cartilage indicating a detached portion of the margin. Nowhere however is there mention of the secondary changes occurring in phase X. Yet Aeby did admit the occurrence of pathological changes although he never observed these going to the extent of actual ankylosis such as Gurlt had described. And in this reservation of Aeby's I must concur for in all our collection of nearly seven hundred pairs of bones no such condition presents itself. There is a suggestion however in the Negro-hybrid male No. 399 (Fig. 29) of age seventy, that pathological ankylosis might have supervened eventually had the patient lived long enough.

As regards age relationships Aeby is less specific, this being due to the fact that he had not access to the age of all the material which he studied, as is clearly shown in legends to his illustrations. Nevertheless he makes several very significant and suggestive observations regarding age relationship, some of which I have noted in the foregoing abstract. It was Aeby's intention to investigate changes in the soft tissue of the symphysis itself brought about by advancing age. For this purpose he measured upon horizontal sections the distance between the hinder extremities of the symphyseal outline and again between the ventral extremities and he noted in contradistinction to its increase in height and antero-posterior diameter with advancing age that the transverse thickness of the intermediary cartilage diminishes in a very peculiar and striking manner. Indeed, as Aeby points out, it confirms what he had written in regard to the pushing forward of the bony margin. While the hinder measurement, he says, diminishes from birth, the ventral measurement up to the age of thirty years takes the contrary course but afterwards certainly diminishes so much the more rapidly. At fifty years, he con-

cludes, the ossification process, if it has not reached its end, has at least sunk to a minimum.

This abstract of Aeby's careful work and accurate observations bears an important relation to the present memoir in two respects. In the first place the two independent investigations figure the same changes resulting in the same final condition of the os pubis. They describe these changes as occurring in the same order and, so far as Aeby's age observations permit a comparison, at the same age periods. Secondly the close agreement of the two descriptions forestalls the objection which might be raised against my work by those insufficiently acquainted with careful technique in bone preparation, namely that the finer structure of the bone might be destroyed or mutilated in the process of maceration. That such an objection is futile is of course shown in the substance of this memoir itself by the fact that although all our skeletons have been prepared by one method and by the same preparators, yet the features exhibited by the bones vary, the variation being in definite sequence and in definite relation to age.

THE SIGNIFICANCE OF THE PUBIC TUBERCLE

The pubic tubercle is generally held to lie further removed from the symphysis in the female than in the male and in many cases to ossify from a separate center of lenticular shape and varying dimensions making its appearance more frequently in the female than in the male.

As a result of this investigation I find it is true that the tubercle is characteristically further from the symphysis in the female although this is by no means always the case and the sexual difference is less marked in the Negro-hybrid than in the White. In many individuals of both sexes and populations the tubercle is either insignificant or absent. The most characteristic sex feature is neither the prominence nor the degree of isolation of the tubercle from the symphysis but rather the massiveness of the upper border of the body of the pubis between the symphysis and the tubercle. In the male this is much fuller and more rounded; in the female thinner and with a rather knife-like edge to which the tubercle forms a more or less distinct termination. While in both sexes the tubercle lies approximately at the divergence of the upper and ventral aspects of the

body of the pubis its precise position is liable to a good deal of variation in the vertical direction so that in extreme case it may lie distinctly on the upper aspect or more frequently on the ventral aspect quite removed from the pecten.

As regards ossification I find no instance in which the tubercle possesses a separate epiphysial bony center. Sometimes it is developed from the upper bony nodule upon the symphyisial face by the extension of which it becomes progressively more removed from the line of symphysis during the first period, that is the first three phases of post-adolescent metamorphosis. But in other and more numerous instances it is already ossified soon after puberty without any indication of a separate center. In these individuals it is already removed beyond the sphere of influence of the upper bony nodule of the symphyisial face. There seems to be no sexual difference in the manner of its formation.

With increasing age, at least up to forty, the tubercle tends to become progressively more prominent in a manner similar to the development of lipping at the tendinous and ligamentous attachments.

ANOMALIES OF THE OS PUBIS ESPECIALLY AT THE SYMPHYISIAL REGION

Anomalies of the os pubis fall into two categories according as they relate to shape or to age relationship. The latter class already received sufficient attention in the body of this work but the former has had only scanty and occasional notice. When true variations have been eliminated, namely precise position and relative prominence of the pubic tubercle, individual differences in height and antero-posterior depth of the symphyisial face, and modifications of the symphyisial outline; and when also pathological deformities have been excluded there remain but three features of distinctly anomalous character. These previously attracted Aeby's attention and may therefore be dismissed very shortly. All are rare and since they represent merely forms of variation sufficiently exaggerated to merit notice I do not propose to discuss their frequency. Indeed to do this would require the establishment of a purely arbitrary subdivision between what one should consider normal and what abnormal. Artificial subdivision in a series of small gradations could merely result in confusion and erroneous impressions.

The first anomaly is represented only twice. It is extreme shortness of the vertical symphyseal height and occurs in the White male No. 94 (Fig. 59, Part I) and the Negro-hybrid female No. 226 (Fig. 87). In the former the symphyseal height is on both sides 22 mm., and in the latter 21 mm. Precise directions for the measurement of the symphyseal height have been given in the first part of the memoir and therefore do not need to be repeated. Such reduction of the symphyseal height to little more than half the normal is important not for itself but because with it there goes a marked acceleration of pubic metamorphosis. On reference to the description of these cases given in the appropriate section one notes that No. 94 of age twenty-eight is already in phase VIII and that No. 226 of age thirty is in phase VII. In both examples the acceleration is not general throughout the skeleton but localized to the os pubis alone. In many other cases where the symphyseal height is rather short a certain acceleration of metamorphosis appears to occur but at the present stage the evidence in favor of an intimate and special relationship between the reduction in height and the phase of metamorphosis is naturally less clear in general than in the two specimens just mentioned. In both 94 and 226 moreover the symphyseal outline retains approximately its normal shape. In some others it is relatively very deep antero-posteriorly but such cases are rather infrequent and except for some possible acceleration present no really significant correlated features.

The second anomaly is unequal height of the symphyseal face on the two sides (e. g. No. 524, Fig. 12). Very frequently the heights of the two sides differ by one, two or three millimeters. On two cases among the male Whites was the difference as much as five millimeters. As it is not always an easy matter to measure the real height of the symphyseal face these differences may be to some extent explicable technically. No associated anomalies occur with them and they may be dismissed without further notice. A few specimens not falling into any of the series examined in this work, do exhibit a very pronounced difference in symphyseal height on the two sides. These are cases of old infantile paralysis with very unequal development of the two sides of the pelvis, sufficient to explain the difference in the symphyseal height.

The third anomaly refers to the contour of the symphyseal face. Whereas in the post-adolescent phases it is convex in both directions

with the oncoming of phase VIII it becomes plane or even slightly concave. Very occasionally one surface remains convex and the other becomes concave. Again through anomalous bone metamorphosis the surfaces may be so inclined toward one another so that a knife driven between them through the soft symphyseal tissue would point not directly backwards but to one or other of the sacro-iliac joints. The Negro-hybrid female specimen No. 226 (Fig. 87) is a well marked example.

Apart from these anomalies there is a variation in symphyseal outline which has received no attention in these pages because it appears to have no special significance from any of the points of view from which we have discussed the pubis. As a general rule the outline of the symphyseal face is an elongated oval. Sometimes however the dorsal surface of the body of the bone, and with it the dorsal symphyseal margin, is concave from above downwards. These cases present a reniform symphyseal face (e. g. No. 93, Fig. 38). Either type of outline has its long axis in the vertical diameter.

GENERAL SUMMARY OF PARTS II, III, IV

1. There is no necessity in this case to include a classification of pubic bones by phases as was done in Part I. The number being smaller all the specimens utilized are mentioned at the beginning of the description of phases.

2. The general features of pubic metamorphosis described for the male White are confirmed in the female White and in the Negro-White hybrid of both sexes.

3. It is now seen that pubic metamorphosis falls into three periods comprising respectively phases I, II, III; IV, V, VI; VII, VIII, IX, X. The first includes the post-adolescent stages, the second the various processes by which the symphyseal outline is built up and the third the period of gradual quiescence and secondary change.

4. So far as age relationship is concerned the male Negro-hybrids compare almost exactly with the male Whites, the major differences being that in the former the second period terminates with completion of the symphyseal outline about two years earlier and that certain features like lipping and secondary erosion commence some years earlier but do not progress so far.

In age relationship the female Negro-hybrids agree with the female Whites rather than with the male Negro-hybrids. It is characteristic of the female that the first and second periods both terminate about two years later than in the male.

Associated with this retardation are certain features of detail in bone change fully discussed in the conclusions of Parts II and III.

5. As regards the influence of racial Stock upon pubic metamorphosis there are strikingly few differences. Some have been mentioned under 3 above and in these the female participates as well as the male.

6. Following the description of the Negro-hybrid female os pubis in the memoir I have devoted several sections to the consideration of salient features brought out by the research. In them the reader will find a summary of the results of the work.

7. Deviations from the normal in age relationship may occur throughout the skeleton generally, may be localized to one particular bone or region of which the symphyseal face serves as an example, or may be distributed erratically so that different parts of the skeleton exhibit very various deviations in their age relationship.

8. In actual bone growth at the symphyseal region the female White somewhat outsteps the male. This difference is not apparent in the Negro-hybrid and in any case there is very little greater addition of bony substance at this site in the White female than in the male.

REFERENCES

1. Aeby (Ch.)—1858. Ueber die Symphyse ossium pubis des Menschen nebst Beiträgen zur Lehre vom hyalinen Knorpel und seiner Verknöcherungen. *Zschr. f. rationelle Med.* Reihe 3, Bd. 4, S 1-77.
2. Cleland (J.)—1889. On certain distinctions of form hitherto unnoticed in the human pelvis, characteristic of sex, age and race. *Memoirs and memoranda in Anatomy*, vol. 1, London, pp. 95-103.
3. Davenport (C. B.)—1913. Heredity of skin color in Negro-White crosses. *Carnegie Publications*, No. 188, pp. 1-106.
4. Hunter (W.)—1761. Remarks on the symphysis of the ossa pubis. *Medical Observations and Inquiries*, vol. ii, p. 333.
5. Schultz (A. H.)—1918. Relation of the external nose to the bony nose and nasal cartilages in Whites and Negroes. *AM. JOUR. PHYS. ANTHROP.*, vol. 1, pp. 329-338.

6. Schultz (A. H.)—1920. The development of the external nose in Whites and Negroes. *Contrib. to Embryology*, No. 34, pp. 73-190. Carnegie Publications.
7. Todd (T. W.)—1920. Age Changes in the Pubic Bone; 1. The Male White Pubis. *AM. JOUR. PHYS. ANTHROPOL.*, vol. 3, pp. 285-334.

LEGENDS FOR FIGURES

FIG. 1. Arrangement of ossa innominata in photographic technique.

No. 571. White, male, age 69.

Note position of symphyisial faces of ossa pubis in small square, the right bone being toward the right of figure and left toward left, with ventral margins adjacent. All succeeding figures represent the ossa pubis in this relative position. Figures are reduced to one-half natural size. The variation in dimensions of the bones in the figures is a real indication of the natural variation in size. All are photographed with the symphyisial surfaces in a plane at right angles to the camera axis.

FIG. 2. Polygon of age frequencies in female and Negro-White hybrid material.

In part I dealing with White males the polygon showed relatively numerous individuals of ages ending in 0 or 5, between thirty and fifty years. This feature is not so strikingly shown in the polygon above although the condition is present to a small degree. Reasons for accepting for the present the series of skeletons here presented are given in the text. Some may be eliminated later when the investigation of age changes in the skeleton is completed. The tendency of the female series to group themselves in the columns corresponding to ages ending in 0 or 5 is comparable with the upward leaps of the male White polygon at these same ages. The large number of White females of age thirty-eight may be due to a feminine desire not to reach forty years; it may however be a genuine condition; further investigation of the skeletons will doubtless decide the question.

The number of skeletons in each age group is represented by the ordinates and the ages themselves by the abscissae.

PLATE I

Os pubis of Negro-White hybrid male. Phases I-IV.

PHASE I.

FIG. 3. No. 519, age 17. Typical ridge and furrow system, ridges being subequal in size; no indication of dorsal delimiting margin, but sharp differentiation of symphyisial face from dorsal aspect of pubis.

FIG. 4. No. 695, age 18. Features similar to those of Fig. 3; surface slightly damaged so that the thin compact tissue is lost in places revealing the underlying cancellous tissue.

FIG. 5. No. 17, age 19; FIG. 6. No. 588, age 19.—In both of these the features are as in Fig. 3; no ossific nodule apparent on any.

PHASE II.

FIG. 7. No. 639, age 20.—Dorsal delimiting margin commencing to form; small ossific nodule indicated in upper part of face; early ventral bevel.

FIG. 8. No. 808, age 20.—Dorsal margin slightly better marked; ventral bevel considerably advanced; note that the appearance of cancellous tissue here is the consequence of a physiological process and not an artefact as in Fig. 4.

FIG. 9. No. 413, age 22.—Dorsal margin distinct; dorsal platform indicated; bony nodule large; ventral bevel not pronounced.

PHASE III.

FIG. 10. No. 366, age 22.—Dorsal margin and platform clearly shown; ventral bevel considerable; disintegration of ridge and furrow system well advanced; bony nodule.

FIG. 11. No. 506, age 23.—Dorsal platform more pronounced; ventral bevel considerable; ridge and furrow system rather persistent; bony nodules not distinct.

PHASE IV.

FIG. 12. No. 524, age 24.—Dorsal margin and platform very clear; ventral bevel considerable; bony nodules present but ill-defined; first beginning of lower extremity.

PHASE V.

FIG. 13. No. 802, age 27; FIG. 14. No. 402, age 29.—These show early and later stages in formation of upper extremity with aid of bony nodule following rapidly upon appearance of lower extremity.

PHASE VI.

FIG. 15. No. 259, age 29.—Earliest beginning of ventral rampart starting from lower extremity.

FIG. 16. No. 486, age 32.—Growth of ventral rampart not very clear; possibly slight retardation; in this and the last there is a distinct remnant of the ridge and furrow system.

FIG. 17. No. 596, age 33.—Ventral rampart nearly completed; extremities well defined.

FIG. 18. No. 677, age 34.—Ventral rampart practically completed; extremities well defined.

FIG. 19. No. 451, age 35.—Features as in last.

PLATE II.

Os pubis of Negro-White hybrid male. Phases VII-X.

PHASE VII: FIG. 20. No. 709, age 33; FIG. 21. No. 606, age 35; FIG. 22. No. 416, age 38; FIG. 23. No. 646, age 40.—In No. 709 the outline is practically complete; in others it is complete; no rim develops but changes are going on in all symphyseal faces.

PHASE VIII: FIG. 24. No. 434, age 40; FIG. 25. No. 729, age 45.—Examples of quiescence of symphyseal face: slight lipping of dorsal margin in No. 729 but merely rudimentary rim formation.

PHASE IX-X: FIG. 26. No. 540, age 45; FIG. 27. No. 422, age 76.—Examples of erosion of ventral margin alone; the older specimen shows distinct lipping of the ventral margin.

FIG. 28. No. 574, age 46; FIG. 29. No. 399, age 70.—Examples of erosion commencing in symphyseal face; No. 574 shows in the upper dorsal part of the symphyseal face a pathological osteophytic area which might possibly later have resulted in pathological fusion of the two bones; No. 399 shows well senile lipping of the margins.

FIG. 30. No. 198, age 48; FIG. 31. No. 97, age 50; FIG. 32. No. 430, age 57.—Examples of erosion of both ventral margin and symphyseal face; No. 430 alone probably normal; symphyseal face erosion in No. 97 and osteophytic lipping ventral margin in No. 198 probably pathological.

PLATE III

Os pubis of Negro-White hybrid male. Individual deviations in age relationship.

Local Acceleration

FIG. 33. No. 682, age 39.—Ventral erosion and "bearded" margin are incompatible with other local and general skeletal features and indicate a local acceleration possibly pathological.

FIG. 34. No. 515, age 40.—Commencing erosion at least five years too early.

FIG. 35. No. 736, age 40.—Features similar to those of last.

FIG. 36. No. 744, age 22.—Early and irregular development of ventral rampart; the "epiphyseal" nature of extremities and ventral rampart is very clearly shown here.

FIG. 37. No. 190, age 26.—Local acceleration unaccompanied by anomaly in shape of symphyseal face; ventral rampart already almost complete and extremities well defined.

FIG. 38. No. 93, age 30.—In other cases such an anomalous outline of the symphyseal face is also associated with local acceleration.

General Skeletal Retardation

FIG. 39. No. 523, age 24.—Features are those of Phase I. FIG. 40. No. 474, age 28.—Features are those of Phase III.

General Skeletal Acceleration

FIG. 41. No. 525, age 22.—Concavo-convex symphyseal faces; associated with this is anomalous metamorphosis suggesting age 25-28.

FIG. 42. No. 458, age 25.—Ill-definition of lower extremity combined with approaching completion of ventral margin indicates about 30.

FIG. 43. No. 330, age 25.—Doubt is expressed regarding the propriety of including this specimen; concavo-convex type; indicates age 35.

FIG. 44. No. 326, age 30.—Pubic bones indicate Phase VII.

Contradictory Skeletal Age Indications of Acceleration

FIG. 45. No. 448, age 31.—Symphyseal face becoming quiescent; ventral aspect of pubis is quite quiescent.

FIG. 46. No. 791, age 28.—Ventral rampart seems to have been formed for some time but has obviously grown up rapidly and left exposed a young-looking symphyseal face.

Contradictory Skeletal Age Indications of Retardation

FIG. 47. No. 792, age 23.—Symphyseal face indicates approximately 19 years but lower extremity is already forming through fusion of an "epiphyseal" nodule.

FIG. 48. No. 779, age 38.—Well defined extremities and ventral rampart in course of formation indicate about 32-33.

PLATE IV

Os pubis of White female.

PHASE I.

FIG. 49. No. 527, age 16.—Contrast this os pubis with No. 437 in size. They show admirably the great individual variation

FIG. 50. No. 437, age 18.—Surface slightly damaged but nevertheless obviously of Phase I.

PHASE II.

FIG. 51. No. 604, age 25.—This specimen corresponds with age 20-21 in the male.

PHASE V.

FIG. 52. No. 269, age 25.—This is an anomalous specimen: see text. FIG. 53. No. 204, age 27.—As in the last there is an early attempt at formation of the ventral rampart. FIG. 54. No. 514, age 30.—Ventral rampart scarcely begun: contrast Nos. 269 and 204.

PHASE VI.

FIG. 55. No. 476, age 35.—Ventral rampart growing by gradual accretion.

FIG. 56. No. 603, age 35.—Ventral rampart growing by bridge formation; contrast No. 476.

FIG. 57. No. 552, age 36; FIG. 58. No. 421, age 38.—Both show ventral rampart forming by accretion very slowly in manner typical of female.

PHASE VII.

FIG. 59. No. 53, age 35; FIG. 60. No. 221, age 38; FIG. 61. No. 228, age 40.—

These specimens show very clearly the gradually diminishing activity of the symphyseal face and also the more persistent activity of the ventral aspect especially in its upper portion. Nos. 53 and 228 still show remnants of the ridge and furrow system. It is doubtless such a remnant occurring in some specimens which led Aeby to infer that the system never quite disappears.

PHASE VIII.

FIG. 62. No. 243, age 40.—Quiescent both on symphyseal face and ventral aspect; remnant of ridge and furrow system; slight suggestion of rim; outstanding lip for attachment of gracilis on ventral aspect near lower extremity especially on left bone.

FIG. 63. No. 249, age 40; FIG. 64, No. 324, age 43; FIG. 65. No. 111, age 45.—All show stage of general quiescence: No. 324 has anomalous symphyseal face, concave right and convex left described in text.

PHASE IX.

FIG. 66. No. 517, age 45.—The irregular appearance is not true erosion; very slight suggestion only of rim; dorsal lipping more clearly seen on original specimen.

FIG. 67. No. 229, age 50.—Rim clearly seen on original specimen: no marked lipping.

PHASE X.

FIG. 68. No. 728, age 50.—Slight ventral erosion; very prominent gracilis lip.

FIG. 69. No. 22, age 60.—Early erosion of symphyseal face.

DEVIATIONS IN AGE RELATIONSHIP

General Skeletal Acceleration

FIG. 70. No. 681, age 28.—Shows ventral rampart already forming by accretion.

FIG. 71. No. 339, age 38.—Shows a quiescent symphyseal face very early.

FIG. 72. No. 454, age 38.—Again an early quiescent symphyseal face.

FIG. 73. No. 715, age 47.—Early erosion ventral margin.

PLATE V

Os pubis of Negro-White hybrid female.

PHASE I.

FIG. 74. No. 485, age 16.—Shows typical appearance with symphyseal cartilage dried in situ.

PHASES II, III.

FIG. 75. No. 561, age 25.—This stage corresponds with age 22 in male.

PHASE VI.

FIG. 76. No. 613, age 33; FIG. 77. No. 529, age 34; FIG. 78. No. 668, age 37.—All show stages in formation of ventral rampart; the condition in No. 613 is somewhat advanced.

PHASES VII, VIII.

FIG. 79. No. 315, age 40; FIG. 80. No. 442, age 40.—Commencement of quiescence better shown in No. 442; gracilis attachment clearer in No. 315; attempt at rim formation in both.

PHASE IX-X.

FIG. 81. No. 530, age 45.—Ventral erosion already commencing. FIG. 82. No. 685, age 45.—Erosion starting in symphyseal face. FIG. 83. No. 152, age 70.—Ventral erosion slightly marked; looks younger than 70 years.

FIG. 84. No. 331, age 70.—Typical heavy senile marginal lipping; right bone damaged above.

DEVIATIONS IN AGE RELATIONSHIP

General Skeletal Acceleration

FIG. 85. No. 495, age 25.—Symphyseal outline already completed; indicates border line between Phases VI and VII.

FIG. 86. No. 439, age 35.—Symphyseal face indicates border line between Phases VII and VIII, i. e., about 40 years.

Local Acceleration

FIG. 87. No. 226, age 30.—Anomalous concavo-convex symphysis; symphyseal outline completed but ventral aspect not yet quiescent.

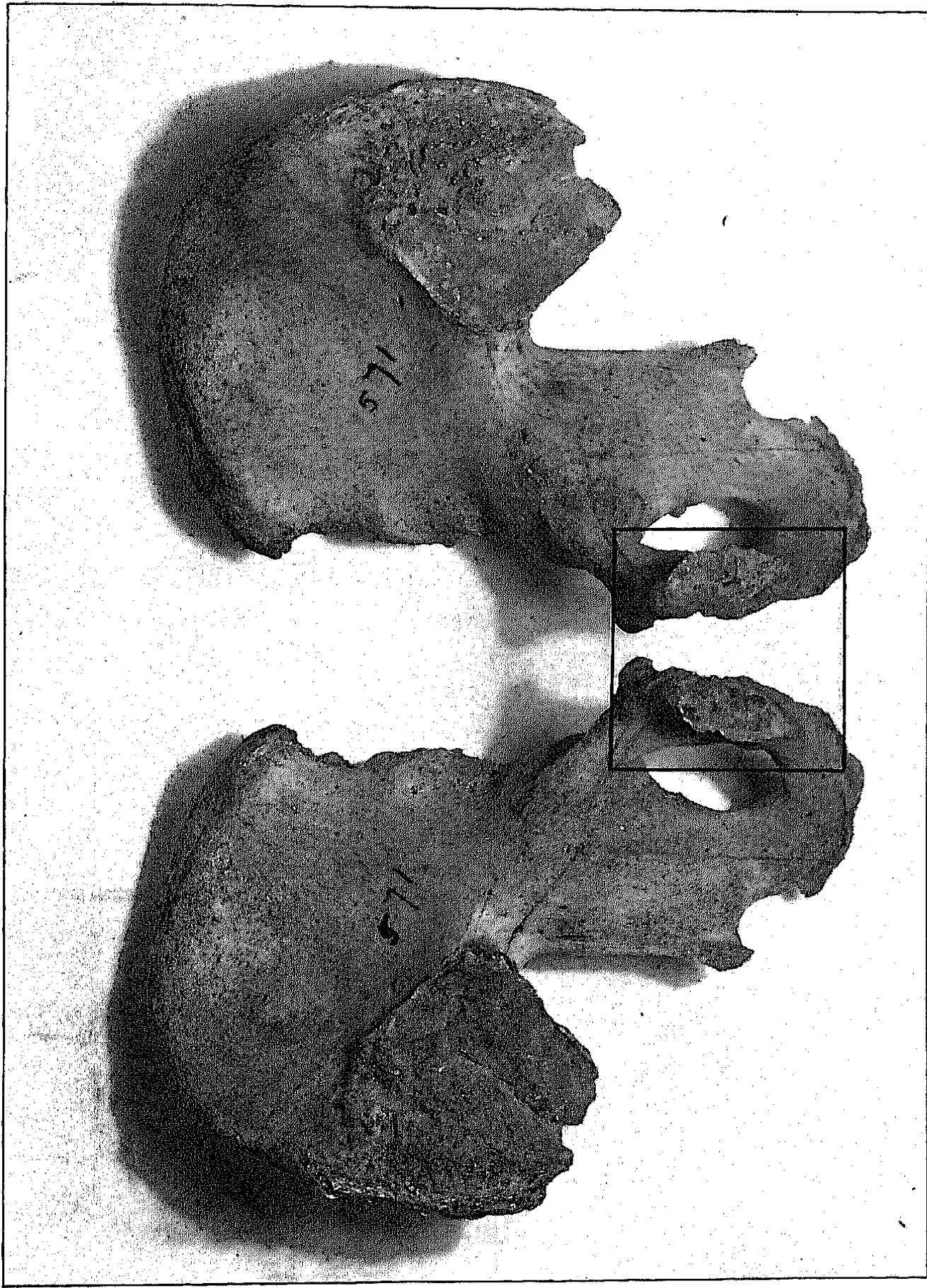

FIGURE 1

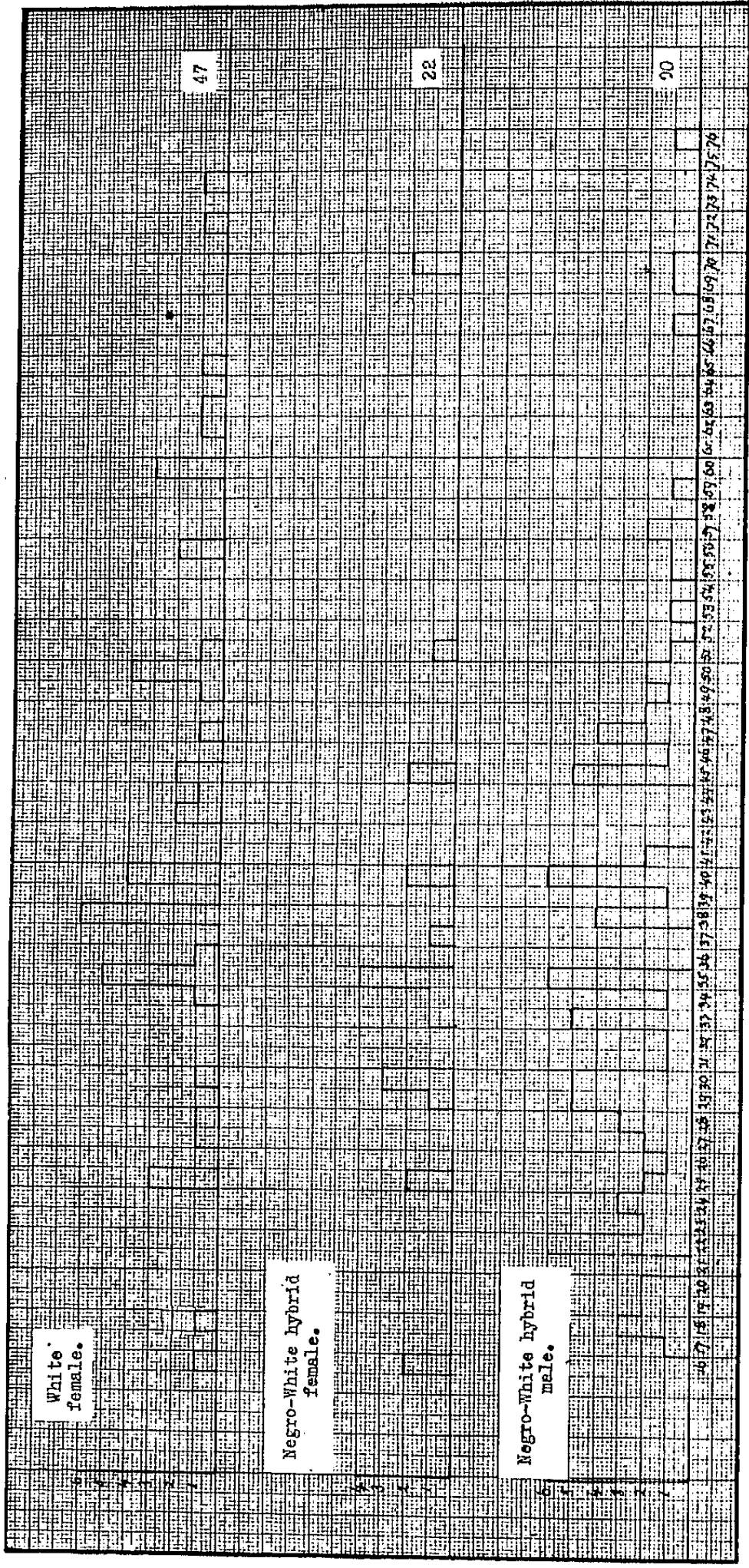


FIGURE II.




PLATE I

Uppermost row, Figs. 3, 4, 5, 6.

Second row, Figs. 7, 8, 9.

Third row, Figs. 10, 11, 12, 13.

Fourth row, Figs. 14, 15, 16.

Lowest row, Figs. 17, 18, 19.

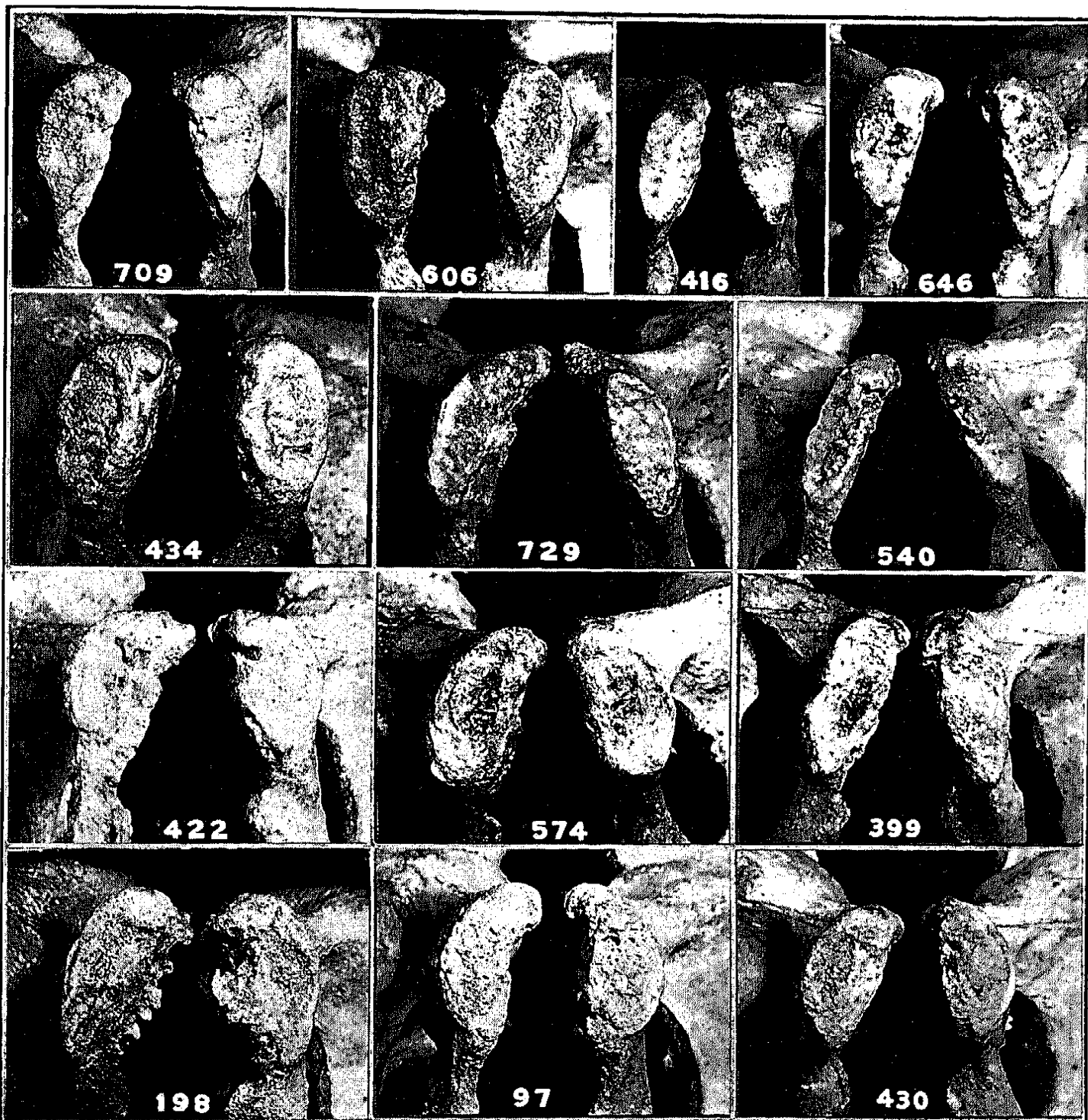


PLATE II

Uppermost row, Figs. 20, 21, 22, 23.

Second row, Figs. 24, 25, 26.

Third row, Figs. 27, 28, 29.

Lowest row, Figs. 30, 31, 32.

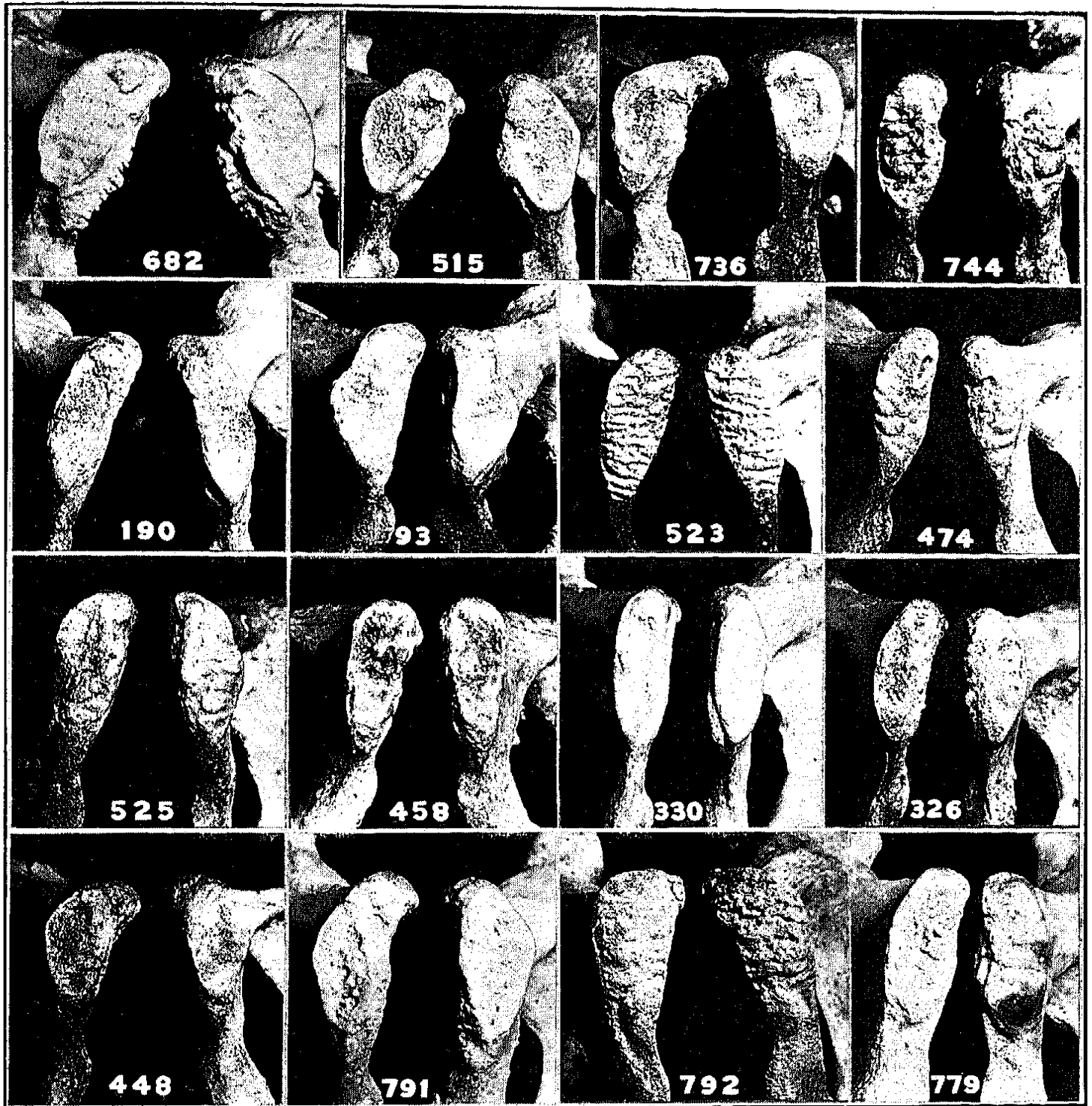

PLATE III

Uppermost row, Figs. 33, 34, 35, 36.
 Second row, Figs. 37, 38, 39, 40.
 Third row, Figs. 41, 42, 43, 44.
 Lowest row, Figs. 45, 46, 47, 48

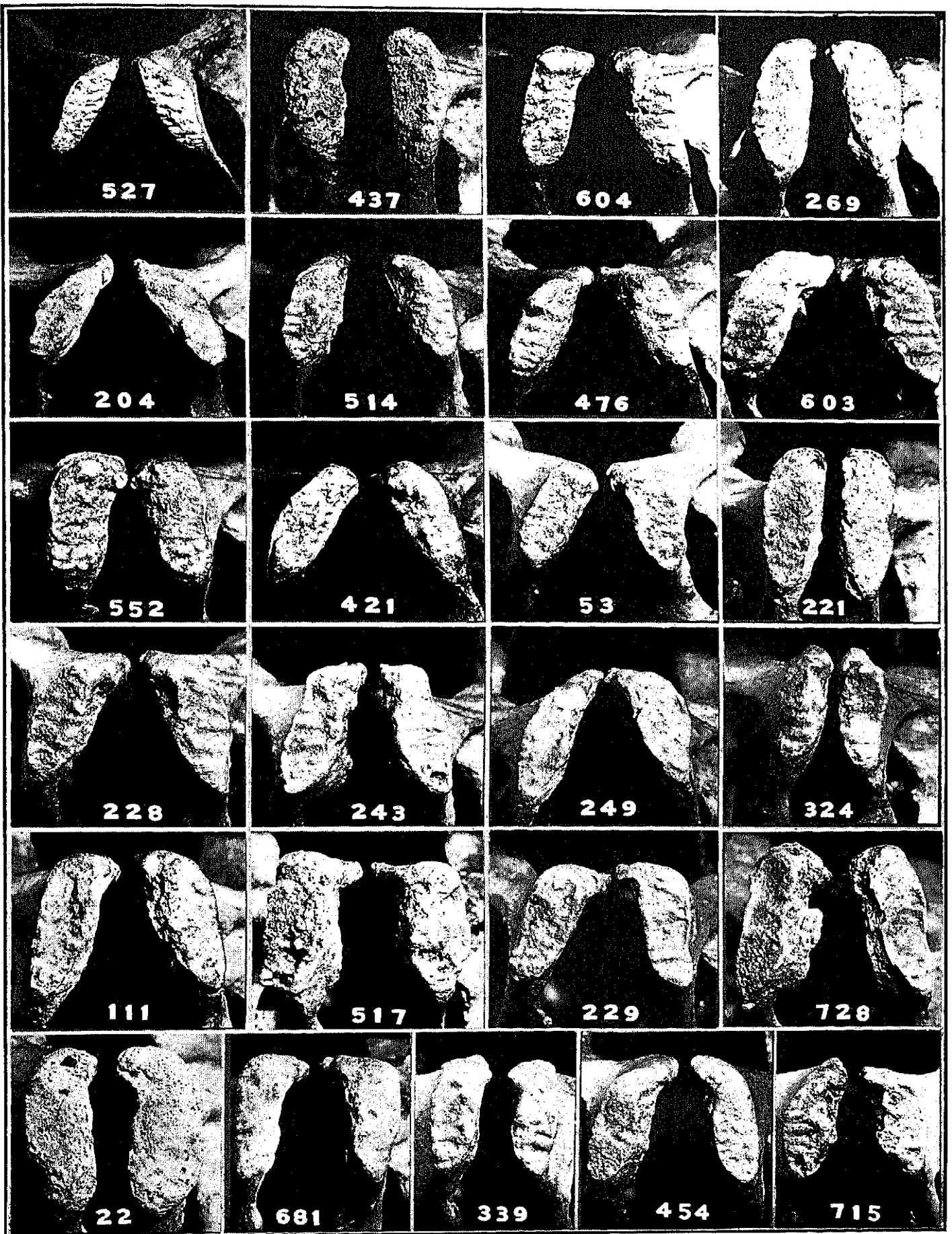


PLATE IV

Uppermost row, Figs. 49, 50, 51, 52.
 Second row, Figs. 53, 54, 55, 56.
 Third row, Figs. 57, 58, 59, 60.
 Fourth row, Figs. 61, 62, 63, 64.
 Fifth row, Figs. 65, 66, 67, 68.
 Lowest row, Figs. 69, 70, 71, 72, 73.




PLATE V

Uppermost row, Figs. 74, 75, 76, 77

Second row, Figs. 78, 79, 80, 81.

Third row, Figs. 82, 83, 84.

Lowest row, Figs. 85, 86, 87.