



HPV in postoperative RT of oropharynx

HPV16 DNA status is a strong prognosticator of loco-regional control after postoperative radiochemotherapy of locally advanced oropharyngeal carcinoma: Results from a multicentre explorative study of the German Cancer Consortium Radiation Oncology Group (DKTK-ROG)



Fabian Lohaus^{a,i,j,1}, Annett Linge^{a,i,j,1}, Inge Tinhofer^{b,k}, Volker Budach^{b,k}, Eleni Gkika^{c,l}, Martin Stuschke^{c,l}, Panagiotis Balermipas^m, Claus Rödel^{d,m}, Melanie Avlar^{e,n}, Anca-Ligia Grosu^{e,o}, Amir Abdollahi^{f,p,q,r}, Jürgen Debus^{f,p,q,s}, Christine Bayer^g, Claus Belka^{g,t}, Steffi Pigorsch^{g,u}, Stephanie E. Combs^{g,u}, David Mönnich^{h,v}, Daniel Zips^{h,v}, Cläre von Neubeck^{a,j}, Gustavo B. Baretton^{a,w,x}, Steffen Löck^j, Howard D. Thames^z, Mechthild Krause^{a,i,j,y}, Michael Baumann^{a,i,j,y,*}, for the DKTK-ROG

^a German Cancer Research Center (DKFZ), Heidelberg, Germany and German Cancer Consortium (DKTK) partner sites: Dresden; ^b Berlin; ^c Essen; ^d Frankfurt; ^e Freiburg; ^f Heidelberg; ^g Munich; ^h Tübingen; ⁱ Department of Radiation Oncology, Faculty of Medicine and University Hospital Carl Gustav Carus, Technische Universität Dresden; ^j OncoRay – National Center for Radiation Research in Oncology, Faculty of Medicine and University Hospital Carl Gustav Carus, Technische Universität Dresden; ^k Department of Radiooncology and Radiotherapy, Charité University Hospital, Berlin; ^l Department of Radiotherapy, Medical Faculty, University of Duisburg-Essen, Essen; ^m Department of Radiotherapy and Oncology, Goethe-University Frankfurt; ⁿ Department of Radiation Oncology, Clinical Study Section, University of Freiburg; ^o Department of Radiation Oncology, University of Freiburg; ^p Department of Radiation Oncology, Heidelberg Ion Therapy Center (HIT), Heidelberg Institute of Radiation Oncology (HIRO), National Center for Radiation Research in Oncology (NCRO), University of Heidelberg Medical School and German Cancer Research Center (DKFZ); ^q National Center for Tumor Diseases (NCT), University of Heidelberg Medical School and German Cancer Research Center (DKFZ); ^r Translational Radiation Oncology, University of Heidelberg Medical School and German Cancer Research Center (DKFZ); ^s Clinical Cooperation Unit Radiation Oncology, University of Heidelberg Medical School and German Cancer Research Center (DKFZ); ^t Department of Radiotherapy and Radiation Oncology, Ludwig-Maximilians-Universität, Munich; ^u Department of Radiation Oncology, Technische Universität München; ^v Department of Radiation Oncology, Faculty of Medicine and University Hospital Tübingen, Eberhard Karls Universität Tübingen; ^w Institute of Pathology, Faculty of Medicine and University Hospital Carl Gustav Carus, Technische Universität Dresden; ^x Tumor- and Normal Tissue Bank, Universitäts KrebsCentrum (UCC), University Hospital Carl Gustav Carus, Technische Universität Dresden; ^y Institute of Radiooncology, Helmholtz-Zentrum Dresden – Rossendorf, Germany; ^z Department of Biostatistics, The University of Texas MD Anderson Cancer Center, Houston, USA

ARTICLE INFO

Article history:

Received 30 August 2014

Received in revised form 29 October 2014

Accepted 8 November 2014

Available online 2 December 2014

Keywords:

DKTK-ROG

HNSCC

HPV

Postoperative radiochemotherapy

p16

p53

ABSTRACT

Objective: To investigate the impact of HPV status in patients with locally advanced head and neck squamous cell carcinoma (HNSCC), who received surgery and cisplatin-based postoperative radiochemotherapy.

Materials and methods: For 221 patients with locally advanced squamous cell carcinoma of the hypopharynx, oropharynx or oral cavity treated at the 8 partner sites of the German Cancer Consortium, the impact of HPV DNA, p16 overexpression and p53 expression on outcome were retrospectively analysed. The primary endpoint was loco-regional tumour control; secondary endpoints were distant metastases and overall survival.

Results: In the total patient population, univariate analyses revealed a significant impact of HPV16 DNA positivity, p16 overexpression, p53 positivity and tumour site on loco-regional tumour control. Multivariate analysis stratified for tumour site showed that positive HPV 16 DNA status correlated with loco-regional tumour control in patients with oropharyngeal carcinoma ($p = 0.02$) but not in the oral cavity carcinoma group. Multivariate evaluation of the secondary endpoints in the total population revealed a significant association of HPV16 DNA positivity with overall survival ($p < 0.01$) but not with distant metastases.

* Corresponding author at: Department of Radiation Oncology and OncoRay – National Center for Radiation Research in Oncology, Faculty of Medicine and University Hospital Carl Gustav Carus, Technische Universität Dresden, Fetscherstraße 74, 01307 Dresden, Germany.

E-mail address: Michael.Baumann@uniklinikum-dresden.de (M. Baumann).

¹ Both authors contributed equally to this study.

Conclusions: HPV16 DNA status appears to be a strong prognosticator of loco-regional tumour control after postoperative cisplatin-based radiochemotherapy of locally advanced oropharyngeal carcinoma and is now being explored in a prospective validation trial.

© 2014 Elsevier Ireland Ltd. Radiotherapy and Oncology 113 (2014) 317–323 This is an open access article under the CC BY-NC-ND license (<http://creativecommons.org/licenses/by-nc-nd/3.0/>).

Head and neck squamous cell carcinoma (HNSCC) patients have a 5-year survival of approximately 50% [1,2]. Within the last years, the number of oropharyngeal cancers has increased [3–5]. Postoperative radiotherapy (PORT) with concurrent cisplatin (PORT-C) has become standard for the adjuvant treatment of patients with resected locally advanced HNSCC after three randomised trials showing superior loco-regional control and improved survival rates compared to PORT alone [6–8]. A meta-analysis of two of the above mentioned trials, the EORTC and the RTOG trials, concluded that patients with positive microscopic resection margins and/or extracapsular extension (ECE) from neck nodes benefit most from this combined treatment [9]. However, all three trials also report increased toxicity after PORT-C vs. PORT [6–8].

In recent years, infection with high-risk human papillomavirus (HPV) has been implicated in the pathogenesis of HNSCC, independently of the risk factors smoking and alcohol consumption [10]. On the molecular level, the HPV oncogenes E6 and E7 have been shown to drive carcinogenesis, which is accompanied by degradation of p53 and pRB and overexpression of p16 due to loss of its transcriptional repression. In addition, HPV-related HNSCC show less p53 mutations than smoking and alcohol induced HNSCC [11]. HPV-positive tumours most commonly originate from the oropharynx [12,13]; high-grade histology and positive lymph nodes are frequent [14]. Interestingly, a recent study observed that patients with HPV16 DNA positive oropharyngeal carcinoma and lower levels of comorbidity show a significantly better overall survival compared to patients with HPV16 DNA negative tumours [15]. Specifically for the field of Radiation Oncology, it has been shown that HPV-positivity is a strong prognostic marker for overall survival and/or local tumour control in patients treated with primary radiochemotherapy [16–20]. However, its impact on outcome after PORT-C is not well evaluated so far.

In an ongoing multicentre retrospective – prospective trial conducted by the Radiation Oncology Group of the German Cancer Consortium (DKTK-ROG), biomarkers for stratification of patients for dose of primary or postoperative radiochemotherapy of HNSCC are being evaluated. The present publication reports the impact of HPV infection on loco-regional tumour control and survival after PORT-C in the multicentre explorative cohort.

Material and methods

Patients, treatment and tissue samples

Patients meeting the following criteria were eligible for inclusion in this retrospective study: histologically proven squamous cell carcinoma arising from the hypopharynx, oropharynx or oral cavity, treatment between 2005 and 2010 with a curatively intended cisplatin-based PORT-C according to standard protocols covering the former tumour region and the neck nodes. All patients had to be judged as being at high risk for loco-regional recurrence due to locally advanced disease with a tumour stage pT4 and/or >3 positive lymph nodes and/or due to postoperative residual disease (positive microscopic resection margins and/or extracapsular spread). Minimum follow-up of patients without progressive disease had to be 24 months. Additionally, formalin-fixed paraffin-embedded (FFPE) material, radiotherapy treatment plans, CT, MRI or PET–CT images of the localisation of the recurrent tumours as well as follow-up data of patients had to be available. Smoking sta-

tus and alcohol consumption were not consistently recorded for all patients and therefore could not be analysed. It was aimed to include 40 patients per DKTK partner centre (i.e., 320 patients in total). To enhance the proportion of HPV-positivity, patients were included consecutively backwards from 2010 towards 2005 in all centres, as HPV prevalence in HNSCC is increasing in recent years [21]. Finally, 221 patients were found to meet all requirements. Those patients were evaluated in this study (Table 2). Pathological specimens, radiotherapy treatment plans, radiological images of recurrent tumours and follow-up data of patients were centrally collected in the DKTK RadPlanBio Platform [Skripcak et al., manuscript in preparation] at the DKTK partner site Dresden.

Ethical approval for multicentre retrospective analyses of clinical and biological data was obtained by the Ethics Committees of all DKTK partner sites.

Failure pattern analysis

Disease status and first site of relapse were evaluated by the treating institution (loco-regional failure, distant failure or combined failure). When loco-regional recurrence and distant metastases occurred at the same time (maximally 6 weeks difference), the patient was counted as combined failure. For every reported loco-regional failure, the radiotherapy treatment plan and radiological images of the recurrence (CT, MRI or PET–CT) were centrally reviewed to ensure that failures originated from the irradiated volume.

Preparation of biomaterials for biomarker analyses

FFPE blocks of the primary tumours were centrally collected at the DKTK partner site Dresden where slides for immunohistochemistry were prepared and genomic DNA was extracted (vide infra). In parallel tissue microarrays, RNA isolates and cDNA were generated for further investigations of biomarkers, which are currently ongoing at the different partner sites. HPV DNA, p16 and p53 reported in this article were evaluated at the DKTK partner site Dresden.

Immunohistochemical staining of p16

In all FFPE samples, the squamous cell carcinoma content was estimated from haematoxylin and eosin stained tissue sections and FFPE samples with <10% tumour content were excluded from p16 analysis. Two hundred and fourteen of the 221 tumour samples (60 oral cavity, 121 oropharynx, 33 hypopharynx) were evaluable for p16. Immunohistochemical staining was performed using the CINtec® Histology Kit (Roche mtm laboratories AG, Basel, CH) according to the manufacturer's instruction. Overexpression of p16 was defined as $\geq 70\%$ intense tumour staining [16]. Blinded samples were evaluated semi-quantitatively by two independent observers (A.L. and C.v.N.) with an inter-observer variability of <5%.

Immunohistochemical staining of p53

FFPE material from all 221 patients was available for p53 analysis. Following deparaffinisation and antigen retrieval in target retrieval solution (pH 9; Dako, Glostrup, DK) for 35 min at 630 W, immunohistochemical staining was performed. Endogenous peroxidase activity was blocked (Peroxidase Block, Dako).

Sections were then incubated with the monoclonal mouse anti-human p53 antibody (Clone DO-7; Dako) in Dako REAL Antibody Diluent for 30 min. Negative control slides were incubated with corresponding IgG antibody control (Dako). The staining was visualised by DAB immunostaining (Dako REAL EnVision Detection System, Peroxidase/DAB, Rabbit/Mouse). Blinded samples were evaluated semi-quantitatively by two independent observers (A.L. and C.v.N.) with an inter-observer variability of <5%. Percentage of p53 staining [22] and staining intensity were scored (0, +, ++, +++). Tumours with $\geq 70\%$ positive nuclei and moderate (++) or strong (+++) staining intensities were considered as p53 positive.

DNA extraction and PCR array-based analysis of HPV status

Genomic DNA was extracted from 5 μm FFPE-sections using the QIAamp DNA FFPE tissue kit (Qiagen GmbH, Hilden, DE) according to the manufacturer's instruction and stored at -20°C until required. HPV DNA analyses including genotyping were carried out using the LCD-Array HPV 3.5 kit (CHIPRON GmbH, Berlin, DE) according to the manufacturer's instruction. Briefly, PCR was performed using the provided Primer Mix A (My 11/09) and B ('125') and the HotStarTaq Plus Master Mix (Qiagen GmbH). Hybridisation mix including 5 μl of each amplified PCR product A and B were added to each field of the LCD-Array. After staining and washing, the hybridisation spots were scanned and analysed using the SlideReader Software (CHIPRON GmbH). For internal quality control purposes, a positive control (HPV33 DNA, UT-SCC-45 xenograft) and a negative control (RNase free water; Qiagen GmbH) were included in each array. Six tissue samples had to be omitted from HPV DNA analysis due to too low DNA yield, thus 215 of the 221 tumour samples (58 oral cavity, 123 oropharynx, 34 hypopharynx) were evaluable for HPV-PCR array.

Statistics

The primary endpoint was loco-regional tumour control; freedom from distant metastases and overall survival were evaluated as secondary endpoints. Loco-regional tumour control, distant metastases and overall survival were calculated from the first day of radiotherapy to the date of local or regional recurrence, date of metastases and date of death or last follow-up, respectively. All endpoints were estimated with the Kaplan–Meier method. The impact of potential prognosticators on the endpoints was evaluated using the Cox-regression model. Parameters found to be significant in univariate analysis were included in a multivariate Cox model. Statistical analyses were performed for all patients and for the subgroups of patients with oral cavity cancers as well as oropharyngeal cancers. Patients diagnosed with hypopharyngeal cancers were excluded from this subgroup analysis due to the low number of cases. Sensitivity and specificity of p16 and HPV16 DNA for predicting loco-regional recurrence were determined by cross tabulation. For all analyses, two-sided tests were used and p -values <0.05 were considered statistically significant. SPSS 21 software (IBM Corporation, Armonk, NY, USA) was used for the generation of Kaplan–Meier plots. STATA 11 (StataCorp LP, College Station, TX, USA) was used for Cox analyses.

Results

In total, 221 patients treated with PORT-C for locally advanced HNSCC were evaluated in this multicentre retrospective study. Patient characteristics, treatment parameters and the number of patients included at each of the 8 DKTK partner sites are summarised in Tables 1 and 2.

Isolated loco-regional failure occurred in 21 patients, isolated distant failure in 31 patients and combined failures were observed

in 8 patients. In 2 patients loco-regional recurrence occurred after distant progression and 4 patients developed distant progression after loco-regional recurrence. All loco-regional recurrences occurred in the treatment volume. Actuarial rates at two years for loco-regional control, freedom from distant metastases and overall survival for the total patient population were 89.6%, 85.1% and 83.4%.

The results of the biomarker analyses of HPV DNA, p16 and p53 and their occurrence at the different tumour sites are shown in Table 3. According to the International Agency for Research in Cancer (IARC), HPV16 DNA positive HNSCC are currently being considered as HPV associated [23] and only this parameter was used for further analysis. HPV16 DNA positivity was observed in 34% of the tumours. Overexpression of p16 was found in 37% of all tumours, and 53% of the oral cavity tumours were positive for p53. The majority (86%) of HPV16 DNA positive tumours were found to be p53 negative.

Only two loco-regional recurrences occurred in patients suffering from HPV16 DNA positive tumours: the first in a R0-resected, ECE positive, pT2 pN2b oral cavity carcinoma (floor of mouth) after 23 months in the boost volume (66 Gy), the second in a R0 resected, ECE positive pT2 pN2b oropharyngeal cancer (tonsil) after 26 months at the margin of the boost volume (64 Gy) to the adjuvant volume (54 Gy). Univariate analyses revealed a significant impact on loco-regional tumour control for HPV16 DNA positivity (HR 0.13; $p < 0.01$; Fig. 1A, Supplementary Table S1). This effect was seen at all 8 treatment centres (Fig. 2). Overexpression of p16 (HR 0.24; $p < 0.01$), p53 positivity (HR 3.36; $p < 0.01$) and tumour site (oral cavity vs. all other tumour sites, HR 3.86; $p < 0.01$; oropharynx vs. all other tumour sites, HR 0.38; $p = 0.01$) also showed a significant impact on loco-regional tumour control. No significant impact was found for sex, UICC stage, R status and ECE status (Supplementary Table S1). Specificity and sensitivity of HPV16 DNA positivity in the total patient population to predict loco-regional tumour control were 93% and 38%, the corresponding values for overexpression of p16 were 86% and 41%. In oropharyngeal cancer specificity and sensitivity of HPV16 DNA positivity were 91% and 53%, for p16 overexpression 73% and 56% were obtained (1 out of 11 loco-regional recurrences occurred within the HPV16 DNA positive group, 3 out of 11 were tested positive for p16). Stratified for tumour site, univariate analyses in oropharyngeal cancer showed that HPV16 DNA (HR 0.09; $p = 0.02$; Fig. 1B, Supplementary Table S1) but not p16 overexpression or p53 positivity have a significant impact on loco-regional tumour control, whereas p53 showed a significant impact on loco-regional tumour control in oral cavity cancer (HR 3.61; $p < 0.05$; Supplementary Table S1).

Table 4 summarises the results of the multivariate analyses, including the significant parameters of the univariate analyses plus ECE status, which had shown a significant impact on the secondary endpoints (Supplementary Table S1). For the total patient population, positive HPV16 DNA status was significantly associated with a high chance of loco-regional tumour control (HR 0.20; $p = 0.04$). Oral cavity cancer showed significantly poorer loco-regional tumour control than oropharyngeal cancers (HR 2.30; $p = 0.04$). Multivariate analysis stratified for tumour site showed that positive HPV16 DNA status correlated with loco-regional tumour control in patients with oropharyngeal carcinoma (HR 0.09; $p = 0.03$) but not in the oral cavity carcinoma group (Table 4). As HPV16 DNA and p16 are strongly correlated, a second multivariate Cox model assessing p16 overexpression was performed. The results of this Cox model showed that the HPV status was a borderline independent prognostic marker for loco-regional tumour control in the total patient population (HR 0.36; $p = 0.07$; Supplementary Table S2).

Multivariate evaluation of the secondary endpoints in the total population revealed a significant association of HPV16 DNA positivity with overall survival (HR 0.36; $p < 0.01$) but not with

Table 1
Patient characteristics and treatment parameter.

Patient characteristic		n	%			
Number of patients		221				
Sex	Male	180	81.4			
	Female	41	18.6			
UICC stage	II	8	3.6			
	III	33	18.6			
	IV	180	81.4			
Tumour localisation	Oral cavity	60	27.1			
	Oropharynx	126	57.0			
	Hypopharynx	35	15.8			
R status*	Negative	125	56.6			
	Positive	94	42.5			
ECE status	Negative	102	46.2			
	Positive	119	53.8			
Treatment parameter	Median	Percentiles				Range
		10%	25%	75%	90%	
Applied cisplatin-dose (mg/m ² body surface area)	200	100	200	200	240	100–300
RT dose (Gy)						
Boost volume	64.0	60.0	63.9	66.0	66.0	57.2–68.4
Per fraction	2.0	1.8	1.8	2.0	2.0	1.8–2.1
Adjuvant volume	50.4	50.0	50.0	55.9	60.0	46.8–66.0
Per fraction	2.0	1.8	2.0	2.0	2.1	1.8–2.2
Time between last surgery and first radiotherapy (weeks)	6.0	4.1	5.0	7.5	9.6	1.0–23.0
Overall treatment time of PORT-C (days)	44.0	41.0	43.0	46.5	50.0	31.0–57.0
Follow-up time (months)	47.3	11.1	30.7	61.2	71.7	2.5–98.6

* Two patients were not evaluable.

Table 2
Number of patients per treatment centre and tumour localisation.

Treatment centre	n	Oral cavity	Oropharynx	Hypopharynx
Dresden	42	21	14	7
Frankfurt	27	12	14	1
Tübingen	33	9	19	5
Freiburg	30	5	20	5
Essen	32	2	22	9
Berlin	24	9	11	4
Munich ^a	17	0	16	1
Heidelberg	15	2	10	3
Total	221	60	126	35

^a Partner site Munich consists of Technische Universität and Ludwig-Maximilians-Universität.

Table 3
Number of tumours with positive biomarkers per tumour localisation.

Biomarker	Overall	Oral cavity	Oropharynx	Hypopharynx
HPV16 DNA	72 (33.5%)	7 (12.1%)	59 (48.0%)	5 (14.7%)
HPV16/18 DNA ^a	1	–	1	–
HPV18 DNA	1	1	–	–
HPV33 DNA	1	–	1	–
p16	79 (36.9%)	11 (18.3%)	65 (53.7%)	3 (9.1%)
p53	85 (38.5%)	32 (53.3%)	40 (31.7%)	13 (37.1%)

^a Patient was included in HPV16 DNA positive group.

distant metastases. ECE status showed significant association with distant metastases (HR 2.55; $p < 0.01$) and borderline significance with overall survival (Table 4 and Supplementary Table S1). Overexpression of p16 showed a significant association with distant metastases (HR 0.31; $p = 0.02$) and on overall survival (HR 0.44; $p = 0.01$) (Supplementary Table S2).

Discussion

While several previous studies provided strong evidence that the HPV status is a significant prognostic marker of loco-regional

tumour control and/or survival in patients treated with primary radiotherapy or radiochemotherapy for locally advanced HNSCC [14,16,18,19], the impact of HPV status on outcome of postoperative radio(chemo)therapy is less well investigated. The results of the present multicentre retrospective study of the DKTK-ROG show that HPV16 DNA positivity is a significant prognosticator of loco-regional tumour control and survival of patients treated with cisplatin-based postoperative radiochemotherapy after surgical resection of locally advanced HNSCC. The effect appears to be robust over all treatment centres and is driven by the results in oropharyngeal cancers. Our findings are in line with a study by Snietura et al. who investigated the influence of HPV infection on the clinical outcome in a posthoc analysis of a randomised clinical trial of two different schedules of PORT without chemotherapy in 279 HNSCC patients. HPV analysis was conducted in tumours of 131 patients. From the 66 patients with oral cavity or oropharyngeal carcinoma, 9 were found to be positive for HPV16 DNA and were locally controlled after 5 years, whereas the loco-regional tumour control rate in the whole HPV DNA negative group was only 58% [24]. Taken together, HPV16 DNA appears to be a potentially promising biomarker for stratification and individualised prescription of postoperative radiotherapy. HPV-positivity seems to be sufficient to define a patient cohort that is highly unlikely to develop loco-regional recurrences after PORT-C, which is in contrast to primary radiochemotherapy where more stratification parameters are necessary [25]. This difference between the two treatment approaches may be caused by the fact that such additional factors, most obviously tumour volume, play a lesser role when the tumour is resected. Other patient-related risk factors like smoking status could not be evaluated in our dataset but might be relevant as well. We are currently performing similar analyses in a patient cohort that has been treated by the same centres and within the same period of time with primary radiochemotherapy to further evaluate such differential prognosticators using a multi-dimensional statistical approach including radiobiological estimates e.g., on tumour cell number. For the group of HPV-negative patients, the situation is largely different. Here, HPV can-

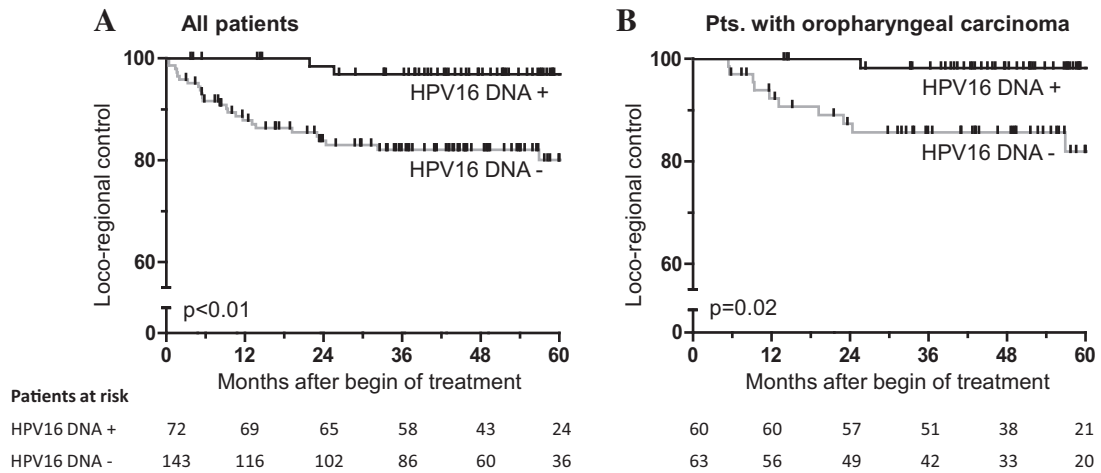


Fig. 1. Kaplan–Meier estimates of loco-regional tumour control. (A) Patients with HPV16 DNA positive HNSCC had significantly higher loco-regional tumour control compared to HPV16 DNA negative tumours. (B) In subgroup analysis, patients with HPV16 DNA positive oropharyngeal tumours showed significantly higher loco-regional tumour control rates than those with HPV16 DNA negative tumours confined to the oropharynx.

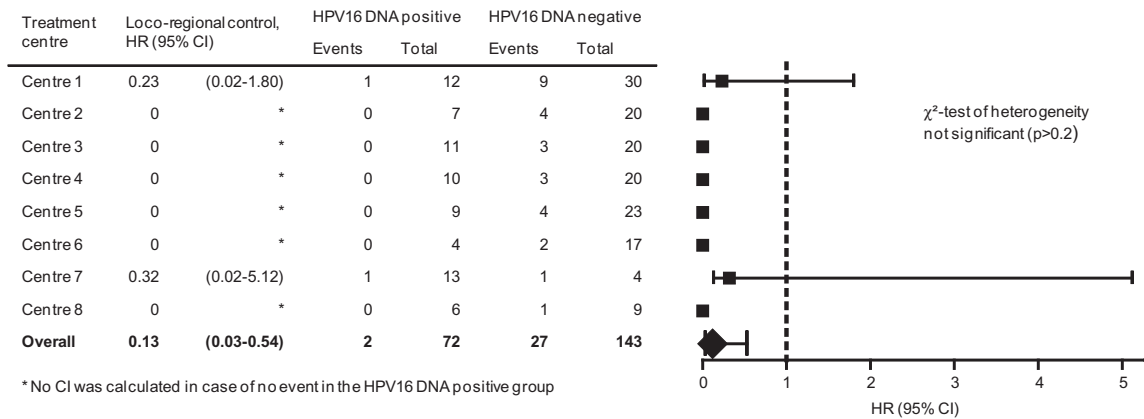


Fig. 2. Forest plot demonstrating the impact of HPV16 DNA status on loco-regional tumour control at the different treatment centres and the pooled estimate (univariate analyses; Supplementary Table S1). HPV16 DNA status is a prognostic parameter for loco-regional tumour control at all treatment centres.

Table 4

Multivariate analyses of prognostic factors for loco-regional control, distant metastases and overall survival. HR = hazard ratio; 95% CI = 95 percent confidence interval.

	All sites		Oral cavity		Oropharynx	
	HR (95% CI)	p-value	HR (95% CI)	p-value	HR (95% CI)	p-value
<i>Loco-regional control</i>						
HPV16 DNA	0.20 (0.04–0.92)	0.04	0.83 (0.10–6.75)	0.87	0.09 (0.01–0.74)	0.03
p53 positivity	1.81 (0.81–4.06)	0.15	3.21 (0.87–11.8)	0.08	0.89 (0.23–3.50)	0.87
ECE status	1.35 (0.62–2.93)	0.45	3.68 (0.83–16.4)	0.09	1.09 (0.29–4.14)	0.90
Oral cavity*	2.30 (1.02–5.16)	0.04	–	–	–	–
Hypopharynx*	0.71 (0.19–2.58)	0.60	–	–	–	–
<i>Distant metastases</i>						
HPV16 DNA	0.56 (0.22–1.42)	0.23	0.97 (0.21–4.38)	0.97	0.40 (0.11–1.49)	0.17
p53 positivity	1.39 (0.72–2.70)	0.32	0.93 (0.35–2.45)	0.88	1.46 (0.42–5.12)	0.55
ECE status	2.55 (1.26–5.15)	<0.01	9.10 (1.21–68.8)	0.03	1.36 (0.43–4.34)	0.60
Oral cavity*	2.37 (1.11–5.07)	0.03	–	–	–	–
Hypopharynx*	2.73 (1.15–6.47)	0.02	–	–	–	–
<i>Overall survival</i>						
HPV16 DNA	0.36 (0.17–0.73)	<0.01	0.30 (0.04–2.23)	0.24	0.36 (0.15–0.82)	0.02
p53 positivity	1.07 (0.65–1.79)	0.78	1.27 (0.58–2.79)	0.55	1.03 (0.46–2.30)	0.94
ECE status	1.63 (0.98–2.70)	0.06	3.60 (1.24–10.5)	0.02	0.99 (0.47–2.13)	1.00
Oral cavity*	1.73 (1.00–2.96)	<0.05	–	–	–	–
Hypopharynx*	0.66 (0.30–1.46)	0.31	–	–	–	–

* Baseline oropharynx.

not be used as a sole biomarker to predict tumour recurrences, as shown by the low sensitivity of 38% or 41% for HPV16 DNA or p16 positivity. Thus, the HPV-negative group needs further investigations into potential biomarkers to stratify for patients who may need treatment intensification and for patients for whom local recurrences are not to be expected.

Currently a prospective multicentre study of the DTKK-ROG is ongoing to validate the prognostic value of HPV16 DNA positivity on loco-regional tumour control after PORT-C in 240 HNSCC patients. If the results of the present retrospective cohort are confirmed, an interventional trial to de-escalate PORT-C radiation doses in HPV16 DNA positive, clinically suitable oropharyngeal cancer patients will be initiated. Specificity assessment of HPV16 DNA positivity for loco-regional tumour control from the present investigation suggests that very few if any recurrences should be expected from a moderate decrease of radiation dose in these patients, therefore strict stopping rules for patient safety against the risk of inferior treatment may be applied in such trial, using e.g., a Pocock boundary approach [26]. Further refinement of risk stratification specifically for the HPV-negative group may result from prospective assessment of clinical parameters [27] in the validation trial, and from ongoing efforts to identify further biomarkers in the current retrospective and in the validation patient cohort.

The low risk of loco-regional recurrence in HPV16 DNA positive oropharyngeal cancers after curatively intended resection and PORT-C suggests that either less tumour stem cells are present at start of PORT-C, that the remaining HPV-positive tumour cells are more radio(chemo)sensitive, or a combination of both. Recently it was reported that HPV-positive oropharyngeal cancers show low expression of stem cell markers such as CD44 and CD98 compared to HPV-negative oropharyngeal cancers [28]. Furthermore, patients with HPV-positive and low CD98 expressing tumours showed better overall survival and progression-free survival compared to patients with high CD98 expressing HPV-positive tumours. Increased radiosensitivity of HPV-positive tumour cells is supported by a number of investigations. HPV-positive HNSCC cell lines (all positive for HPV DNA, HPV RNA and p16) assessed by colony formation assay in vitro showed a higher cellular radiosensitivity when compared to HPV-negative cell lines due to compromised DNA repair capacity [29]. Similar observations have been reported by others [30,31]. Further observations using both in vitro and in vivo approaches suggest that overexpressed p16 impairs the recruitment of RAD51 to the DNA damage site in HPV-positive HNSCC by down-regulation of cyclin D1, thereby affecting the cell cycle and homologous recombination-mediated DNA repair response [32].

There is currently no generally agreed consensus for the assessment of the HPV infection status as a potential biomarker; general methods used for assessment of HPV infection include HPV DNA, HPV RNA, and p16 overexpression [33–35]. The vast majority of HPV-positive HNSCC has been shown to be positive for HPV16 DNA [21,36], which is in line with the results reported here. HPV16 DNA showed stronger correlations with outcome parameters as compared to p16 immunohistochemistry in a cohort of 50 patients with oropharyngeal tumours who received primary radiochemotherapy [37]. Also in our study HPV16 DNA appears as a stronger prognosticator for loco-regional tumour control compared to p16 expression (Table 4 vs. Supplementary Table S2), however this needs to be validated in a larger cohort.

In the present study HPV16 DNA positivity was a strong independent prognosticator for loco-regional tumour control in oropharyngeal but not in oral cavity tumours. In contrast, increased p53 positivity was observed in oral cavity tumours, which suggests an alternative pathway for tumour development, e.g. life style factors.

The tumour suppressor gene TP53 is known to be involved in carcinogenesis of HNSCC [38] and its overexpression is reported in heavy smokers and heavy drinkers [39,40]. Increased positivity has been linked to TP53 gene mutations, which can cause stabilisation and nuclear accumulation of p53 proteins [41]. It has been demonstrated that the HPV oncoprotein E6 inactivates and inhibits p53 [42,43], which is in line with the fact that the majority of our HPV-positive study cohort was negative for p53.

In our study, extracapsular extension of lymph nodes is a prognostic factor for overall survival in patients with oral cavity carcinomas but not in the total patient population. This seems to be in contrast to the results of the meta-analysis by Bernier et al., showing that positive margins and/or extracapsular extension are the most significant prognosticators for poor outcome/overall survival [9]. However this meta-analysis did not stratify between oral cavity and oropharyngeal cancer and molecular biomarkers were not investigated as confounding factors in the trials included in the meta-analysis (EORTC and RTOG trials). Furthermore patients included in the EORTC and RTOG trials might reflect a different population relative to the patient cohort analysed in the present study, underlining the necessity of constant marker adaptation for patient stratification. Further efforts to investigate different biomarkers specifically for the HPV-negative group receiving post-operative radiochemotherapy as well as for primary radiochemotherapy are currently ongoing in the DTKK-ROG using material of the cohort reported here and of the validation trial.

In conclusion, our results of this retrospective explorative multicentre study show that HPV16 DNA seems to be a strong prognosticator of loco-regional tumour control after postoperative cisplatin-based radiochemotherapy of locally advanced oropharyngeal carcinoma and is therefore a promising biomarker for patient stratification. The effect appeared robust over the 8 treatment centres. For patients with HPV16 DNA positive oropharyngeal carcinoma treatment de-intensification may be a valid interventional option for a prospective trial that is currently prepared.

Conflict of interest statement

The authors have nothing to disclose.

Acknowledgements

The authors acknowledge the excellent technical assistance by Mrs. Liane Stolz-Kieslich and Mrs. Sigrid Balschukat. The authors wish to thank all pathologists, head and neck surgeons, and maxillofacial surgeons at the 8 treatment centres that provided materials and data for this study. The study was financed by a Joint Funding Grant within the German Cancer Consortium (DKTK), which is funded as one of the National German Health Centres by the Federal German Ministry of Education and Research.

Appendix A. Supplementary data

Supplementary data associated with this article can be found, in the online version, at <http://dx.doi.org/10.1016/j.radonc.2014.11.011>.

References

- [1] Ferlay J, Shin HR, Bray F, Forman D, Mathers C, Parkin DM. Estimates of worldwide burden of cancer in 2008: GLOBOCAN 2008. *Int J Cancer* 2010;127:2893–917.
- [2] Leemans CR, Braakhuis BJ, Brakenhoff RH. The molecular biology of head and neck cancer. *Nat Rev Cancer* 2011;11:9–22.

- [3] Chaturvedi AK, Anderson WF, Lortet-Tieulent J, et al. Worldwide trends in incidence rates for oral cavity and oropharyngeal cancers. *J Clin Oncol* 2013;31:4550–9.
- [4] Sturgis EM, Cinciripini PM. Trends in head and neck cancer incidence in relation to smoking prevalence: an emerging epidemic of human papillomavirus-associated cancers? *Cancer* 2007;110:1429–35.
- [5] Habbous S, Chu KP, Qiu X, et al. The changing incidence of human papillomavirus-associated oropharyngeal cancer using multiple imputation from 2000 to 2010 at a Comprehensive Cancer Centre. *Cancer Epidemiol* 2013;37:820–9.
- [6] Bernier J, Dommene C, Ozsahin M, et al. Postoperative irradiation with or without concomitant chemotherapy for locally advanced head and neck cancer. *N Engl J Med* 2004;350:1945–52.
- [7] Cooper JS, Pajak TF, Forastiere AA, et al. Postoperative concurrent radiotherapy and chemotherapy for high-risk squamous-cell carcinoma of the head and neck. *N Engl J Med* 2004;350:1937–44.
- [8] Fietkau R, Lautenschläger C, Sauer R, et al. Postoperative concurrent radiochemotherapy versus radiotherapy in high-risk SCCA of the head and neck: results of the German phase III trial ARO 96–3. *J Clin Oncol* 2006;24:5507.
- [9] Bernier J, Cooper JS, Pajak TF, et al. Defining risk levels in locally advanced head and neck cancers: a comparative analysis of concurrent postoperative radiation plus chemotherapy trials of the EORTC (#22931) and RTOG (#9501). *Head Neck* 2005;27:843–50.
- [10] Fakhry C, Gillison ML. Clinical implications of human papillomavirus in head and neck cancers. *J Clin Oncol* 2006;24:2606–11.
- [11] Agrawal N, Frederick MJ, Pickering CR, et al. Exome sequencing of head and neck squamous cell carcinoma reveals inactivating mutations in NOTCH1. *Science* 2011;333:1154–7.
- [12] Kawakami H, Okamoto I, Terao K, et al. Human papillomavirus DNA and p16 expression in Japanese patients with oropharyngeal squamous cell carcinoma. *Cancer Med* 2013;2:933–41.
- [13] Salazar CR, Smith RV, Garg MK, et al. Human papillomavirus-associated head and neck squamous cell carcinoma survival: a comparison by tumor site and initial treatment. *Head Neck Pathol* 2014;8:77–87.
- [14] Fakhry C, Westra WH, Li S, et al. Improved survival of patients with human papillomavirus-positive head and neck squamous cell carcinoma in a prospective clinical trial. *J Natl Cancer Inst* 2008;100:261–9.
- [15] Ankola AA, Smith RV, Burk RD, Prystowsky MB, Sarta C, Schlecht NF. Comorbidity, human papillomavirus infection and head and neck cancer survival in an ethnically diverse population. *Oral Oncol* 2013;49:911–7.
- [16] Ang KK, Harris J, Wheeler R, et al. Human papillomavirus and survival of patients with oropharyngeal cancer. *N Engl J Med* 2010;363:24–35.
- [17] Habbous S, Harland LT, La Delfa A, et al. Comorbidity and prognosis in head and neck cancers: differences by subsite, stage, and human papillomavirus status. *Head Neck* 2014;36:802–10.
- [18] Lassen P, Eriksen JG, Hamilton-Dutoit S, Tramm T, Alsner J, Overgaard J. Effect of HPV-associated p16INK4A expression on response to radiotherapy and survival in squamous cell carcinoma of the head and neck. *J Clin Oncol* 2009;27:1992–8.
- [19] Lassen P, Overgaard J, Eriksen JG. Expression of EGFR and HPV-associated p16 in oropharyngeal carcinoma: correlation and influence on prognosis after radiotherapy in the randomized DAHANCA 5 and 7 trials. *Radiother Oncol* 2013;108:489–94.
- [20] Rischin D, Young RJ, Fisher R, et al. Prognostic significance of p16INK4A and human papillomavirus in patients with oropharyngeal cancer treated on TROG 02.02 phase III trial. *J Clin Oncol* 2010;28:4142–8.
- [21] Marur S, D'Souza G, Westra WH, Forastiere AA. HPV-associated head and neck cancer: a virus-related cancer epidemic. *Lancet Oncol* 2010;11:781–9.
- [22] Mineta H, Borg A, Dictor M, Wahlberg P, Akervall J, Wennerberg J. P53 mutation, but not p53 overexpression, correlates with survival in head and neck squamous cell carcinoma. *Br J Cancer* 1998;78:1084–90.
- [23] Bouvard V, Baan R, Straif K, et al. A review of human carcinogens – part B: biological agents. *Lancet Oncol* 2009;10:321–2.
- [24] Snietura M, Piglowski W, Jaworska M, et al. Impact of HPV infection on the clinical outcome of p-CAIR trial in head and neck cancer. *Eur Arch Otorhinolaryngol* 2011;268:721–6.
- [25] Rios-Velazquez E, Hoebels F, Aerts HJWL, et al. Externally validated HPV-based prognostic nomogram for oropharyngeal carcinoma patients yields more accurate predictions than TNM staging. *Radiother Oncol* 2014;113:317–23.
- [26] Ivanova A, Qaqish BF, Schell MJ. Continuous toxicity monitoring in phase II trials in oncology. *Biometrics* 2005;61:540–5.
- [27] Garden AS, Kies MS, Morrison WH, et al. Outcomes and patterns of care of patients with locally advanced oropharyngeal carcinoma treated in the early 21st century. *Radiat Oncol* 2013;8:21.
- [28] Rietbergen MM, Martens-deKemp SR, Bloemena E, et al. Cancer stem cell enrichment marker CD98: a prognostic factor for survival in patients with human papillomavirus-positive oropharyngeal cancer. *Eur J Cancer* 2014;50:765–73.
- [29] Rieckmann T, Tribius S, Grob TJ, et al. HNSCC cell lines positive for HPV and p16 possess higher cellular radiosensitivity due to an impaired DSB repair capacity. *Radiother Oncol* 2013;107:242–6.
- [30] Gupta AK, Lee JH, Wilke WW, et al. Radiation response in two HPV-infected head-and-neck cancer cell lines in comparison to a non-HPV-infected cell line and relationship to signaling through AKT. *Int J Radiat Oncol Biol Phys* 2009;74:928–33.
- [31] Kimple RJ, Smith MA, Blitzer GC, et al. Enhanced radiation sensitivity in HPV-positive head and neck cancer. *Cancer Res* 2013;73:4791–800.
- [32] Dok R, Kalev P, Van Limbergen EJ, et al. P16INK4a impairs homologous recombination-mediated DNA repair in human papillomavirus-positive head and neck tumors. *Cancer Res* 2014;74:1739–51.
- [33] Snow AN, Laudadio J. Human papillomavirus detection in head and neck squamous cell carcinomas. *Adv Anat Pathol* 2010;17:394–403.
- [34] Westra WH. Detection of human papillomavirus (HPV) in clinical samples: Evolving methods and strategies for the accurate determination of HPV status of head and neck carcinomas. *Oral Oncol* 2014;50:771–9.
- [35] Smeets SJ, Hesselink AT, Speel EJ, et al. A novel algorithm for reliable detection of human papillomavirus in paraffin embedded head and neck cancer specimen. *Int J Cancer* 2007;121:2465–72.
- [36] Mineta H, Ogino T, Amano HM, et al. Human papilloma virus (HPV) type 16 and 18 detected in head and neck squamous cell carcinoma. *Anticancer Res* 1998;18:4765–8.
- [37] Bussu F, Sali M, Gallus R, et al. Human papillomavirus (HPV) infection in squamous cell carcinomas arising from the oropharynx: detection of HPV DNA and p16 immunohistochemistry as diagnostic and prognostic indicators – A pilot study. *Int J Radiat Oncol Biol Phys* 2014;89:1115–20.
- [38] Nylander K, Dabelsteen E, Hall PA. The p53 molecule and its prognostic role in squamous cell carcinomas of the head and neck. *J Oral Pathol Med* 2000;29:413–25.
- [39] Field JK, Spandidos DA, Malliri A, Gosney JR, Yiagnisis M, Stell PM. Elevated P53 expression correlates with a history of heavy smoking in squamous cell carcinoma of the head and neck. *Br J Cancer* 1991;64:573–7.
- [40] Field JK, Spandidos DA, Stell PM. Overexpression of p53 gene in head-and-neck cancer, linked with heavy smoking and drinking. *Lancet* 1992;339:502–3.
- [41] Maestro R, Dolcetti R, Gasparotto D, et al. High frequency of p53 gene alterations associated with protein overexpression in human squamous cell carcinoma of the larynx. *Oncogene* 1992;7:1159–66.
- [42] Scheffner M, Werness BA, Huibregtse JM, Levine AJ, Howley PM. The E6 oncoprotein encoded by human papillomavirus types 16 and 18 promotes the degradation of p53. *Cell* 1990;63:1129–36.
- [43] Werness BA, Levine AJ, Howley PM. Association of human papillomavirus types 16 and 18 E6 proteins with p53. *Science* 1990;248:76–9.